22900306024

Med
K49943

Digitized by the Internet Archive
in 2016

https://archive.org/details/b28106817

SYSTEM OF

OPHTHALMIC PRACTICE

PYLE

THERAPEUTICS

DARIER

AN INTERNATIONAL SYSTEM

OF

OPHTHALMIC PRACTICE

Edited by WALTER L. PYLE, A. M., M. D.

Member of the American Ophthalmological Society, Ophthalmologist to the Mt. Sinai Hospital, Philadelphia, formerly Assistant Surgeon to Wills Eye Hospital, etc.

Compact Well Illustrated Octavo Volumes.

DARIER. Ophthalmic Therapeutics. According to the most Recent Discoveries. By DR. A. DARIER, *of Paris.* Translated by SYDNEY STEPHENSON, M. B., F. R. C. S., London. *Late Hon. Sect. Ophthalmological Society.* Illustrated.

KNAPP. Medical Ophthalmology. By ARNOLD KNAPP, M. D., *Professor of Ophthalmology, College of Physicians and Surgeons, New York City.* Illustrated.

BEARD. Ophthalmic Diagnosis. By CHARLES H. BEARD, M. D., *Surgeon to the Illinois Charitable Eye and Ear Infirmary, Chicago.* Illustrated.

COLLINS and MAYOU. Pathology and Bacteriology of the Eye. By EDWARD TREACHER COLLINS, F. R. C. S., *Surgeon to the Royal London Ophthalmic Hospital;* and M. S. MAYOU, F. R. C. S., *Assistant Surgeon and Pathologist, Central London Ophthalmic Hospital, etc.* Illustrated

HOLMES. Affections of the Orbit and Accessory Cavities. By CHRISTIAN R. HOLMES, M. D., Cincinnati. Illus.

PYLE. Examination and Refraction of the Eye and Eyestrain. By the Editor, DR. WALTER L. PYLE. Illustrated.

OPHTHALMIC SURGERY. This volume, completing the series, will be announced later.

AN INTERNATIONAL SYSTEM

OF

OPHTHALMIC PRACTICE

EDITED BY

WALTER L. PYLE, A. M., M. D., Philadelphia
MEMBER OF THE AMERICAN OPHTHALMOLOGICAL SOCIETY

THERAPEUTICS

BY

DR. A. DARIER, Paris

TRANSLATED BY

SYDNEY STEPHENSON, M. B., F. R. C. S., London
LATE HONORARY SECRETARY OF THE OPHTHALMOLOGICAL SOCIETY

ILLUSTRATED

PHILADELPHIA
P. BLAKISTON'S SON & CO.
1012 WALNUT STREET
1910

Copyright, 1910, by P. Blakiston's Son & Co.

WELLCOME INSTITUTE LIBRARY
Coll. welMOmec
Call No. WW

Printed by
The Maple Press
York, Pa.

PREFACE.

In pursuance with the announced purpose of this system to provide a compact and thoroughly modern digest of ophthalmic practice, Dr. Darier has endeavored to set forth concisely the established up-to-date methods of ophthalmic therapeutics and the results of the latest investigations in this connection. To secure the desired homogeneity in the series there has been exercised free editorial control of the manuscript. The comprehensive index includes complete cross-references to the various drugs and therapeutic methods discussed as well as to the relative diseased conditions.

Walter L. Pyle.

1931 Chestnut Street,
Philadelphia.

TABLE OF CONTENTS.

FIRST PART.

GENERAL THERAPEUTICS.

CHAPTER I.

PAGE

Methods of Diagnosis 3

Clinical diagnosis; Anatomico-pathologic, microscopic, and bacteriologic diagnosis; Experimental diagnosis; Serum-diagnosis; Therapeutic diagnosis; The method of Arning and Klein for demonstrating the spirochæta of Schaudinn; Living spirochæta; Experimental diagnosis; Sero-diagnosis; Injections of tuberculin; Von Pirquet's cuti-reaction; Lautier's modification of cuti-reaction; Epidermal method of cutaneous diagnosis; Ophthalmo-reaction; Technic of ophthalmo-reaction; Sero-diagnosis of syphilis; Therapeutic diagnosis; Mercurial treatment; Sodium salicylate; Guaiacol.

CHAPTER II.

Constitutional Treatment 14

Importance of constitutional treatment in ocular affections; Arteriosclerosis; Iodids; Nitrites; Milk diet; Anemia; Leukocythemia; Diabetes; Albuminuria; Syphilitic affections; Lymphatism and scrofula; Preparations of iodin; Mercurials; Mercurial inunctions in traumatic infections of eye; Sympathetic ophthalmitis; Silver antiseptics.

CHAPTER III.

Extraoral Medication 23

Inunctions; Hypodermic medication; Stomatitis; Symptoms of intoxication; Soluble salts of mercury for injection; Oil of biniodid; Intravenous injections; Technic of intravenous injections; Phlebitis; Enesol or salicylarsenate of mercury; Arsenical preparations; Atoxyl; Arsacetin;

PAGE

Potassium iodid; Pilocarpin injections; Sodium salicylate injections; Quinin; Colloidal silver, collargol; Antitoxic serums and tuberculin; Antitetanic serum; Antiplague serum; Iron, arsenic and iodin; Hetol; Rachidian and epidural injections; Bier-Tuffler's method; Lumbar puncture; Intrarachidian injection of colloidal mercury; Method of Cathelin.

CHAPTER IV.

INTRAOCULAR AND SUBCONJUNCTIVAL INJECTIONS 39

Rationale; General effects; Sympathetic ophthalmitis; Infective ulceration of cornea; Action upon choroid; Myopic choroiditis; Retrobulbar neuritis; Diseases of ciliary body and iris; Contraindications; Action of subconjunctival injections; Technic of subconjunctival injection; Indications for subconjunctival injections; Corneal leukomata; Interstitial keratitis; Hypopyon keratitis; Sympathetic ophthalmitis; Chorioretinitis; Episcleritis or iritis; Salicylates; Opacities of crystalline lens; Infiltrations of sclera; Iodate of Sodium; Glaucoma; Injections of sterilized air; Guaiacol; Serums.

CHAPTER V.

SERUM-THERAPY 51

Phagocytosis; Opsonic index; Antitoxic serum; Paraspecific serotherapy; Pyocyanase; Activity of serum estimated by antitoxic units; Anaphylaxis; "Serum-sickness;" Antipneumococcic serum; Serpiginous ulcer of cornea; Technic; Results; Antitetanic serum; Deutschmann's serum; Antistreptococcus serum; Simultaneous employment of several sera; Vaccins; Hypopyon keratitis; Infected penetrating wounds of the cornea, ciliary region, or sclera; Infective complications of operation for cataract; Oral administration of sera; Prophylactic employment of serum; Tuberculins; Opsonic theory; Opsonic index; Method of employing Tuberculin T. R.; Subconjunctival injection of tuberculin; Important clinical observation; Guaiacol; Oral administration; Instillation into conjunctival sac; Oxydases, metallic ferments, and colloidal metals; Staphylase; Colloidal metals; Warmed horse's serum; Hemophilia; Hemorrhagic affections of the eye; Bacteriolytic agents; Pyocyanase; Bile; Antiformin and thalianin; Hemolytic serum;

PAGE

General remarks upon serotherapy; Roemer's jequiritol serum; Ehrlich's side-chain theory; Organotherapy; Adrenalin; Thyroid-treatment; "Antithyroidin"; Pituitary body; Parenchymatous keratitis; Retinal hemorrhages; Rheumatism; Lamb's liver; Extract of uveal tract; Extract of ciliary body; Extract of retina; "Optocine"; Vitreous body of rabbits; Pulverized crystalline lenses; Spermin and testicular extract; Bone-marrow and spleen-pulp; Raw meat.

CHAPTER VI.

Diaphoretics, Revulsives, Purgatives, Heat, and Cold, Etc. 82

Vapor baths and dry heat baths; Warm packs; Pilocarpin sweats; Revulsives; Derivatives; Leeches; Wet cupping; Purgatives; Laxatives; Calomel; Diuretics; Milk diet; Antipyretics; Narcotics; Antispasmodics; Stimulants; Physical agents; Heat and cold; Cataplasms; Linseed-meal poultice; Mercurial poultice; Vapor douches; Moist heat; Steam; Thermophore; Dry heat; Thermoaerophore; Iced compresses; Cold moist dressings; Priestnitz dressing; Alcohol dressing; Iodin; Mercurial plasters; Carbolic plaster; Stasis hyperemia; Bier's method.

CHAPTER VII.

Phototherapy 96

Electric-light baths; Arc lamp; Sun's rays.

CHAPTER VIII.

Electricity, Electrotherapy 101

Indications; High-frequency currents; Constant current; Electrolysis; Bipolar electrolysis; Medicamentous electrolysis; Galvanocautery; Electromagnets; Volkmann's magnet; Sideroscope.

CHAPTER IX.

X-rays and Radium 109

X-rays; Neoplasms; Trachoma; Tuberculosis of conjunctiva; Radium; Dermatoses and superficial neoplasms; Lupus; Chancre; Chalazion; Uveitis; Trachoma; Nervous disorders.

CHAPTER X.

PAGE

Hydrotherapy, Mechanotherapy 120

Medicamentous corneal massage; Vibratory massage; Pressure-massage of Domec.

CHAPTER XI.

Local Medication, Anesthetics, Analgesics 133

Powders; Ointments; Oily collyria; Aqueous collyria; Ocular anesthetics; Cocain; Subconjunctival injections; Mydriatic action; Subcutaneous injections; Cocain-poisoning; Eucain B.; Tropacocain; Holocain; Stovain; Alypin; Novocain; Lusemin; Ocular analgesics; Orthoform; Anesthesin; Acoin; Sodium salicylate; Aspirin; Quinin; Antipyrin; Pyrenol; Pyramidon; Phenacetin; Dionin; Peronin; Codein; Heroin; Morphin; Adonidin.

CHAPTER XII.

Vasodilators, Vasoconstrictors 157

Dionin; Adrenalin; Cocarenalin; "Homorenon;" Anterenol.

CHAPTER XIII.

Mydriatics and Cycloplegics, Miotics. 173

Atropin; Scopolamin; Homatropin; Duboisin; Hydrobromate of methyl-atropin; Cocain; Ephedrin; Mydrin; Eumydrin; Euphthalmin; Miotics.

CHAPTER XIV.

Drugs Modifying Conjunctival Secretions. The Silver Compounds 179

Antiseptics; Carbolic acid; Mercuric chlorid; Mercury cyanid; Caustics; Silver nitrate; Protargol; Protargolage; Zingage; Argyrol; Ophthalmoblennorrhea; Silver salts; Savonnage; Sophol; Argonin; Sulphophenate of silver; Itrol; Actol; Collargol; Lavements; Electrargol.

SECOND PART.

SPECIAL THERAPEUTICS.

CHAPTER XV.

PAGE

DISEASES OF THE ORBIT 197

Orbital periostitis; Osteoperiostitis; Abscess; Tenonitis; Sinuses; Enophthalmos; Dislocation; Pulsating exophthalmos; Exophthalmic goiter; Strabismus; Paralysis; Ptosis; Trigeminal neuralgia; Blepharospasm.

CHAPTER XVI.

DISEASES OF THE LACRIMAL APPARATUS 203

Glands; Dacryoadenitis; Mikulicz's disease; Congenital imperforation; Excessive lacrimation; Probe; Dacryocystitis; Electrolysis; Sac; Mucocele; Prelacrimal tumor; Complications.

CHAPTER XVII.

DISEASES OF THE EYELIDS 211

Solar erythema; Eczema; Prurigo; Acne rosacea; Erysipelas; Zona ophthalmica; Xanthelasma; Wounds; Tetanus; Styes; Boils; Chalazion; Edema; Emphysema; Malignant pustule; Hard chancre; Epithelioma; Tuberculous ulceration; Blepharitis.

CHAPTER XVIII.

DISEASES OF THE CONJUNCTIVA 219

Irritation; Congestion; True conjunctivitis; Pneumococci; Staphylococci; Phlyctenular conjunctivitis; Savonnage; Ophthalmoblennorrhea; Ophthalmia neonatorum; Protargolage; Iritis; Arthritis; Gonococcal infection; Argyrol immersion; Buller's shield; Metastatic gonorrheal conjunctivitis; Beef-serum; Lenicet; Acetate of aluminium; Prophylaxis of ophthalmia neonatorum; Alcoholic con-

PAGE

junctivitis; Diphtheritic conjunctivitis; Spring catarrh; Tuberculosis of conjunctiva; Parinaud's infective conjunctivitis; Granulous conjunctivitis, Trachoma; Follicular conjunctivitis; Salts of silver; Copper sulphate; Surgical treatment of trachoma; Galvanocautery; Thermocautery; Resection; Expression; Grattage; Granulous infiltrations; Forceps; Triple-bladed knife; Jequiritol; Xerosis; Xerophthalmia; Pemphigus; Pinguecula; Pterygium; Hyaline degeneration; Amyloid degeneration.

CHAPTER XIX.

Diseases of the Cornea and Sclera 254

Wounds and infections; Infective organisms; Keratitis dendritica; Keratitis stellata; Galvanocautery; Corneal infection; Infective ulceration of cornea; Serotherapy; Infective traumatism of eyeball; Wounds of ciliary region; Burns; Keratitis; Lymphatic; Phlyctenular; Pustular; Eczematous; Fascicular; Strumous; Pannus crassus; Marginal ulcer; Infective ulcer; Superficial arborescent keratitis; Herpes febrilis; Zona ophthalmica; Vesicular keratitis; Pemphigus; Macular keratitis; Keratitis punctata; Filamentary keratitis; Acne rosacea; Aspergillary keratomycosis; Marginal ulcerations; Lepromata; Rodent ulcer; Neuroparalytic keratitis; Keratomalacia; Xerosis of cornea; Deep keratitis; Parenchymatous, keratitis; Interstitial keratitis; Striated keratitis; Rheumatic parenchymatous keratitis; Traumatic mesokeratitis; "Hutchinson's triad"; Corneal opacities; Corneal leukomata; Opaque staphyloma; Diseases of the sclera; Episcleritis; Posterior sclerochoroiditis; Scleritis; Sclerosing keratitis; Episcleral nodosities.

CHAPTER XX.

Diseases of the Iris and Ciliary Body, Iritis, Iridocyclitis, Iridochoroiditis 295

Pathologic evolution; Treatment; Syphilitic iritis; Rheumatic iritis; Gonorrheic iritis; Tuberculous iritis; Guaiacol; Local indications; Intravenous injection; Iodic medication; Sympathetic ophthalmia; Treatment; Enucleation; Panophthalmitis; Surgical treatment of iritis; "Seclusion pupillæ"; Iridectomy.

CHAPTER XXI.

PAGE

Diseases of the Crystalline Lens 320

Congenital aphakia; Coloboma; Lenticonus; Ectopia; Hyaloid artery; Congenital cataract; Zonular cataract; Pyramidal cataract; Removal of lens; Discission; Extraction; Wounds; Traumatic myopia; Astigmatism; Rupture of zonule of Zinn; Subluxation; "Tremulous iris"; Luxation; Traumatic cataract; Senile cataract; Spontaneous resorption; Medicinal treatment; Surgical treatment; Technic of cataract operation; Preliminary iridectomy; Precautions; Corneal incision; Minimum of instruments; After-treatment; Accidents during operation; Loss of vitreous; Dislocation of lens; Hemorrhage; Prolapse of iris; Glaucomatous complications; Infective complications; Secondary cataract; Crystalline lens removed in high myopia; Paracentesis; Extraction.

CHAPTER XXII.

Treatment of Glaucoma 346

Pathogeny; Iridectomy; Necessity of operation; Prodromal glaucoma; Irritative glaucoma; Posterior sclerotomy; Chronic glaucoma; Sympathectomy; Cyclodialysis; Miotics; Hydrophthalmus; "Paradoxical glaucoma"; "Sympathetic glaucoma"; Results of iridectomy; High-frequency currents.

CHAPTER XXIII.

Diseases of Vitreous Body, Choroid, and Retina. . . . 363

Mouches volantes; Hemorrhages; Fundus oculi; Chronic hyalitis; Synchysis; Cysticercus; Vitreous infections; Diseases of macula; Subconjunctival injections; Pigmentary choroiditis; Dionin; Suppurative choroiditis; Inadequate blood-supply; Anemia of retina; Uremic amaurosis; Embolism of central artery; Massage; Thrombosis of retinal veins; Hemorrhagic retinitis; Specific chorioretinitis; Relapsing central retinitis; Retinitis proliferans; Atrophic macular retinitis; Albuminuric retinitis; Diabetic retinitis; Leukemic retinitis; Septic metastatic retinitis; Pigmentary retinitis; Retinitis pigmentosa sine pigmento; Retinal phototraumatism; Retinal electrocution; Commotion retinæ; Detachment of retina; Con-

PAGE

tusion of eyeball; Myopic detachment; Moderate detachments; Grave detachments; Puncture; Electrolytic puncture.

CHAPTER XXIV.

Diseases of the Optic Nerve 394

Retrobulbar neuritis; Pathogeny; Etiologic factors; Therapeutic indications; Conclusions; Specific neuritis; Optic neuritis; Intracranial disease; Surgical intervention; Trephining; Lumbar puncture; Vertebral trepanation; White atrophy; Gray atrophy; Tumor of hypophysis; Oxycephaly.

FIRST PART.

GENERAL THERAPEUTICS.

CHAPTER I.

METHODS OF DIAGNOSIS.

The methods of precise diagnosis are of especial importance in modern ophthalmic practice. They may be classified as follows:

1. **Clinical diagnosis,** which is the most important and most commonly employed method. It is attained only by a judicious study of the complaints of the patient and of the physical signs, general and local, either perceived by our senses or revealed by special instruments, such as the plessimeter, stethoscope, sphygmograph, tonometer, thermometer, radiograph, etc.

2. **Anatomico-pathologic, microscopic, and bacteriologic diagnosis,** as upon the examination of the secretions from the chemical and bacteriologic point of view, the microscopic examination of pieces of tissue obtained by excision or scraping, etc., the recognition of gonococci, bacilli tuberculosis, spirochæta pallida, etc.

3. **Experimental diagnosis** by transplanting to susceptible animals the malady observed; as, for instance, tubercle to the rabbit or guinea-pig, syphilis to the monkey, etc.

4. **Serum diagnosis,** or all tests which seek to provoke a biologic reaction by means of vaccins, immunized animal serum, or attenuated cultures of microbes; as, for instance, the reaction to tuberculosis by hypodermic injections, the inoculation of skin wounds, the cuti-reaction of von Pirquet, the ophthalmo-reaction of Wolff-Eissner-Calmette (the conjunctiva), the sero-diagnosis of Wassermann and Neisser, etc.

5. **Therapeutic diagnosis,** which is as old as clinical diagnosis, *naturam mortorum curationes ostendant.*

For full descriptions of the modern precise methods of clinical diagnosis, the reader is referred to one of the many excellent text-books on this subject.

It is, however, in this connection, deemed advisable to discuss several important recent additions to our diagnostic armamentarium.

The method of Arning and Klein for demonstrating the spirochæta of Schaudinn is as follows:

In order to meet with success in the search for the spirochæta, one must examine patients who have undergone no treatment by mercury or iodids. The suspicious part is carefully cleansed with a bit of wool soaked with ether or petrol. It is then scraped or rubbed with the angle of a piece of glass until there is collected on the edges of the cover-glass, blood or blood mixed with serum. The presence of blood is absolutely necessary.

By thrusting to a depth of 5 mm. a narrow blade, spirochætes have sometimes been found in cured hard chancres, although the superficial layers had not shown the organisms.

The serum mixed with blood obtained in the manner described is spread on a cover-glass first carefully freed from grease by alcohol and ether. The preparation is fixed by passing it thrice above a flame, and is then stained by the rapid method of Rona-Preis. A mixture is made of distilled water, 10 c.c., and Giemsa's liquid, 10 to 15 drops. Four or five times this solution is poured over the cover-slip, and each time the slip is slightly warmed. In order to avoid applying too much heat to the specimens, the authors recommend that a grease-mark be made half a centimeter from one of the ends of the cover-slip. If too much heat be then applied, the line of grease melts. The spirochætes are to be sought for by an oil-immersion lens.

In searching for the **living spirochæta** the authors place a drop of physiologic salt solution upon a cover-slip, very clean and freed carefully from grease. A drop

of blood-serum, obtained as previously explained, is lifted with the platinum loop and mixed with the drop of saline solution. The preparation is covered with a glass slip, care being taken that no air-bubbles are imprisoned, and lutted down by means of paraffin. Arning and Klein have been able to convince themselves that in such preparations, kept in the dark at room temperature, the spirochætes may remain alive for as long as four weeks, an observation confirmed by Hoffmann. Preparations of living spirochætes are especially interesting to examine with the new special illuminating apparatus now made in Germany. The latter, indeed, may with advantage replace the ultra-microscope.

When the authors search for **spirochætes in sections** they adopt Levanditi's method.

The results obtained have been as follows:

Chancres examined, 140; positive results, 136. Secondary affections examined, 247; positive results, 235. Among the patients who were examined, in thirty-two the certain clinical diagnosis was impossible, and it was only the discovery of the spirochæta that allowed the existence of syphilis to be affirmed. In eighteen doubtful cases, the absence of the spirochæta suggested a diagnosis of soft chancre, although in two of these cases the subsequent appearance of secondary symptoms showed the existence of true syphilis.

These brilliant results show the great value of a simple and rapid method of searching for Schaudinn's spirochæta.

Experimental diagnosis may be considered permissible in certain superficial lesions of the eye. After inoculating the cornea and the anterior chamber of the rabbit to reproduce the lesions which will enlighten us as to the origin of the affection, it is sometimes possible to find the initial organisms in the inoculated organs, as, for example, spirochætes or tubercle bacilli.

In cases of iritis of doubtful etiology, it has been

advised that there should be withdrawn with an aseptic syringe a few drops of aqueous humor, for the purpose of injecting it into the anterior chamber of the guinea-pig or the rabbit. By such a method one may discover the tuberculous origin of iritis (Gourfein).

We have, however, as will be discussed later, methods quite as practical as the foregoing, but much less dangerous for diagnosing tuberculosis. It is hardly justifiable to induce a patient to allow the anterior chamber to be opened simply for purposes of diagnosis. On the other hand, whenever one believes that an injection of air into the anterior chamber is likely to have a favorable therapeutic effect, the opportunity should be seized to utilize the aqueous humor for the establishment of an experimental diagnosis. The withdrawn fluid may be injected into the anterior chamber of an animal, and may also be examined microscopically by means of a smear preparation.

Sero-diagnosis is so recent and so interesting a conquest that it merits adequate discussion in works upon opthalmic therapeutics.

If we may look upon the local and general reaction set up by **injections of tuberculin** as a certain proof of the existence of tuberculosis, it is important to indicate the main principles of this valuable element of diagnosis.

If we inject about 0.001 grm. of Koch's tuberculin into the subcutaneous tissues of a person affected with tuberculous iritis, keratitis, or, indeed, any other malady of which tuberculosis is suspected of being the cause, we observe a febrile reaction more or less marked, which betrays itself by a rise in temperature of one or sometimes of two degrees centigrade, while at the same time the local lesion or its surroundings become markedly hyperemic, and more or less lively pain is experienced by the patient. Dependent on the degree of the affection and, especially, on the individual resistance, it is sometimes necessary to give a second or third injection of tuberculin before the desired reaction is provoked.

There is an even more practical means of proving the existence of tuberculosis, especially in those cases in which the clinical signs point to that diagnosis; namely, commencing treatment with very feeble doses of tuberculin T. R. or of Koch's new emulsion. There are injected every other day progressive and stronger doses, and at the end of several days the reaction will be produced, which may be local or general, but is less violent and less dangerous than with the foregoing method.

Von Pirquet's cuti-reaction may also be advantageously employed. It is merely necessary in this test to scarify the skin, and then to rub the selected locality with a solution of tuberculin. Soon the region of the tiny incisions becomes red and slightly swollen, as one may observe in false vaccination (*fausses vaccines*).

Lautier's modification of cuti-reaction is simpler and less disagreeable for the patient. The technic is very simple. A bit of wool is saturated with three drops of a 1 per cent. solution of tuberculin and applied to the outer surface of the arm. In order to facilitate diffusion of the liquid and to ensure prolonged contact with the epidermis, the wool is covered with a small square of gutta-percha tissue, and kept in place with wool and several turns of a bandage. The dressing is not disturbed for forty-eight hours. At the end of this time the dressing is removed, when in tuberculous adults, as well as in children, there is seen an hour after having taken off the dressing that a small erythematous and papular area has developed in the place where the tuberculin was in contact with the skin. This region has a slight coppery hue, trenching upon sound skin. The boundaries of the area are clearly thrown into relief by the neighboring parts. The reaction obtained by these means may be strong, medium, or feeble, and in the last case one sees merely a slight redness, slightly wrinkled and in relief with the surrounding parts. Mahe-Desportes (*Thèse de Bordeaux*, 1908) concludes: 1. That healthy subjects never present cuti-reaction by this pro-

cedure. 2. That tuberculous subjects generally react, and that this cuti-reaction is parallel to the ophthalmo-reaction—that is to say, that an individual who reacts strongly to the one test will also do so to the other, and *vice versa*. 3. That in all cases in which cuti-reaction fails, ophthalmo-reaction will also fail.

The epidermal method of cutaneous diagnosis is effected by injecting a drop of a solution of tuberculin into the dermis, immediately beneath the epidermis. If the subject be tuberculous, a lively reaction will manifest itself on the following day.

The ophthalmo-reaction was discovered simultaneously by Wolff-Eissner, in Berlin, and by Calmette, in Lille. The method is valuable in general diagnosis, but in ophthalmic practice it should not be used, for if a slight tuberculous lesion of the cornea or iris is present it may set up serious complications gravely endangering the sight of the affected eye. Moreover, in the absence of all tuberculosis, the ophthalmo-reaction may provoke a conjunctivitis difficult to cure, especially when a follicular state of the mucous membrane already exists; and still more so when the individual is affected with trachoma, even of slight degree.

An attempt has been made to avoid these complications by using weak solutions of tuberculin. The dose recommended by Calmette was 1 per cent., and it has been proposed to use in children a strength of 1/2 per cent. But until more numerous experiments have been made, the ophthalmologist will be well advised to abstain from employing the ophthalmo-reaction. At the same time, the cuti-reaction, as well as the hypodermic injection of tuberculin, is capable of rendering great service in ophthalmic practice.

In concluding as to the value and proper place of the tuberculin tests, we can do no better than quote Wolff-Eissner, who wisely says: "The discovery of the local reactions to tuberculin and their diagnostic employment has

opened up a new era in medicine. These reactions constitute an important method, but they are of no significance if they are not seconded by clinical observation. To limit oneself to the ophthalmo-reaction or to the cuti-reaction and to ignore clinical investigations would be at once a fault and a danger; the physician should be on his guard against exaggerated and too enthusiastic an appreciation."

The technic of the ophthalmo-reaction, according to Calmette, is as follows: Before placing a drop of a 1 per cent. solution of tuberculin in the inner corner of the eye, the following precautions are necessary:

1. To determine that no lesion, however slight, exists in the eye or the eyelids, in order to avoid a reaction which exceeds the desired end, and may even compromise more or less an organ which is already the seat of a preëxisting microbic infection.

2. To avoid absolutely all blinking at the moment when the tuberculin is instilled, otherwise the liquid may be rejected before it has had time to produce its effect, and erroneous if not actually false conclusions may result. Accordingly, care should be taken to throw back the patient's head and also to keep the eyelids separated for several moments after the application.

3. To advise the patient not to rub the eyelids after the drop has been placed in the eye, since that may falsify the results. In case of necessity, an occlusive bandage may be applied.

4. According to the precepts of Calmette, to avoid all abnormal inflammation (blepharitis, conjunctivitis) by using only tuberculin precipitated by alcohol and perfectly aseptic. Never under any circumstances to employ glycerized tuberculin, on account of its causticity.

By conforming scrupulously to the foregoing rules, which are clear, precise, and easy to follow, one may depend upon the reliability of this test.

The sero-diagnosis of syphilis depends upon the search

for antibodies and syphilitic antigens by the biologic method of Bordet and Gengou. These authors have found that whenever one places a serum rich in bacterial antibodies—as, for example, antityphoid, anticholera, or antiplague serum—in contact with the microbe that has produced the antibodies, two phenomena take place: first, the antibody fixes upon the body of the microbe, in a way that is strictly specific; and, secondly, as a consequence of this fixation, the same antibody absorbs the hemolytic complement.

These data will show how the most various antibodies may be looked for in the body fluids and tissues, and will serve equally well to show how microbes or their products may be discovered in infected organs or culture-media. It is especially in the diagnosis of syphilis that the method has been employed. As the result of researches made in common with Neisser and Bruck, **Wassermann** has shown that the reaction of the deviation of the complement allows one to identify the antisyphilitic antibodies and antigens derived from the *treponema pallidum* in the humors and tissues of men and of monkeys affected with syphilis. If one desires to make certain whether a given subject has or has not been infected with syphilis, the serum is warmed to 58° C. for a quarter of an hour (destruction of the complement), and then mixed in variable quantity with the same volume of extract of a syphilitic liver. Then a minimal quantity of guinea-pig serum, rich in the hemolytic complement, is placed in the tubes, and the mixture is kept at a temperature of 38° C. for two hours. As soon as this period has passed, one places in the tubes the hemolytic amboceptor of the rabbit and the red blood-corpuscles of the sheep. Should the serum under examination really contain syphilitic antibodies, there will be no dissociation of the red corpuscles, which will retain their hemoglobin. If, on the other hand, hemolysis occurs as in the test-tubes, it may be concluded that antibodies are absent from the serum.

The apparent complexity of this method vanishes when it has been tried several times. From its faithful employment a certain number of facts have been gathered with regard to the presence of antibodies and antigens in syphilitic subjects.

Neither Wassermann nor his collaborators, nor the observers who have controlled their experiments, have succeeded in finding the antigens or antibodies of syphilis in healthy individuals, save in a few very exceptional cases. On the contrary, in the great majority of cases of human syphilis and experimental syphilis, syphilitic antigens and antibodies have been discovered, sometimes in the blood, and at other times in the tissues. Wassermann and Neisser, in 163 cases of florid syphilis, obtained positive reactions in 75.5 per cent., and in latent syphilis in 58 per cent. The researches of Wassermann have been confirmed by Citron, Mayer, and Fleishmann.

The close relationship between syphilis and general paralysis and tabes are too well recognized to render it necessary to enumerate the arguments that have led practitioners to class the latter among the so-called para-syphilitic processes. This relationship has been rendered even more intimate by the discovery of syphilitic antibodies in the cerebrospinal fluid of those affected with tabes and general paralysis. Wassermann and Plaut, who have sought for these antibodies by Bordet and Gengou's method, found that a positive reaction could be obtained in 88 per cent. of the cases of syphilitic general paralysis.

From a clinical point of view, it would be difficult to exaggerate the importance of the sero-diagnosis of syphilis. Wassermann's method will often allow us to resolve problems with which clinical work alone would be inadequate to deal. Very frequently does clinical enquiry, despite the perseverance of the observer, furnish only indecisive information with regard to the specific antecedents in cases in which certitude would be so useful in determining the proper treatment. Again, it would often

be of service to decide whether treatment has ended the infection, so that the patient may safely marry. Lastly, it often is desirable to know whether we may safely confide a baby to a wet-nurse who denies all history of syphilis. In spite of our incomplete acquaintance with the value of Wassermann's sero-reaction, this reaction may be very helpful in answering these and cognate questions.

A. Leber (*Berlin Ophthalmological Society*, March 19, 1908), in the course of a communication on Wassermann's sero-diagnosis in affections of the eye, reached the following results: In sixteen cases of avowed syphilis of the eye, a positive result was obtained in 93.7 per cent. In ninety-five doubtful cases, the result was positive in 42.1 per cent. The result was positive in 84 per cent. of thirty-one cases of interstitial keratitis; in 38 per cent. of forty-eight cases of iritis; in 26 per cent. of twenty-three cases of choroidoretinitis; and, lastly, in 59 per cent. of twenty affections of the cerebrospinal axis.

Thanks to the kindness of Dr. Levaditi, the writer has had occasion to apply the Wassermann sero-diagnosis at the Pasteur Institute in several cases in which the diagnosis of an ocular affection was impossible by clinical methods. The data thereby obtained have been of the greatest service in the conduct of treatment, and have certainly contributed to the rapid cure of the case.

Therapeutic diagnosis often allows one to make what may be called a retrospective diagnosis. For example, should a doubtful affection yield very quickly to **mercurial treatment** the conclusion might follow that syphilis was the cause. This is not always true, for sometimes a parenchymatous keratitis is cured by mercurial treatment, and, later, the tuberculous origin of the disease becomes manifest. The same remark applies to **sodium salicylate,** which quickly relieves acute rheumatic affections, but may also be valuable in many other affections, among them sympathetic ophthalmitis.

Thanks to subconjunctival injections, which permit

us to apply the remedy *loco dolenti*, we may often obtain valuable diagnostic indications. In a case of episcleritis, we may hesitate between a diagnosis of rheumatism, syphilis, or tuberculosis. The rapid cure after one or two injections of salicylates, mercury, or **guaiacol** often furnishes us with the key to the etiology of the disease. Syphilis, it is true, may be recognized by Wassermann's method. When the reaction is negative, a deep subconjunctival injection of 1 c.c. of a 2 per cent. solution of guaiacol is made. The reaction is relatively slight, and the pain lasts barely five minutes (guaiacol is analgesic). After three or four days, when the redness and chemosis due to the injection have disappeared, if the affection is tuberculous, the surgeon will be pleased to find a considerable improvement, whether the case be one of episcleritis, iritis, parenchymatous keratitis, or even an affection of the deeper membranes of the eye.

The specific action of guaiacol upon tuberculosis of the eye is so marked that its subconjunctival injection may give great relief in cases in which the hypodermic injection of tuberculin has been followed by a violent ocular reaction, as shown by redness, pain, and sometimes even by a very evident rise in tension. The pain, under these circumstances, disappears some hours after the injection.

In two cases of double optic neuritis from cerebral tumor in which inunctions of guaiacol brought about the disappearance of the headache, vomiting, and neuritis, the inference was that the encephalic lesions were of tuberculous origin (Darier, Arnold).

CHAPTER II.

CONSTITUTIONAL TREATMENT.

The Importance of Constitutional Treatment in Ocular Affections.—If it is necessary to make an etiologic diagnosis, it is because nowadays we are no longer contented with purely symptomatic treatment. It is of the greatest importance to treat the local affection at the same time as the underlying constitutional cause. The constitutional cause may proceed from a chronic infection or intoxication of the entire organism, which has little by little set up a general disturbance of the nutrition and of the vitality of the tissues. These disturbances may be transmitted by heredity, with different modifications, but with a type always peculiar to themselves. By its trophic reflexes the nervous system plays an important part in all these troubles of nutrition.

To Bouchard's thinking, that which is called "arthritism" is nothing more than a disease of debility of nutrition. To others, it represents a kind of rheumatismal heredity (an atavistic infection still imperfectly understood), which predisposes to gout and to a number of diseases bound to it by the alternations and frequent coincidences among the members of the same family.

In the many affections that are called arthritic, experience has shown us that alkalies are useful; that sodium salicylate and lithia are indicated, and, in particular, that a special hygiene suits such patients—as, for example, local and general massage, vapor baths, exercise in the fresh air, etc.

Arteriosclerosis is often found among aged arthritics, and it represents the almost natural limits of the evolution of the arterial system. Whether or not it be a product

of hypertension, it is none the less the common and ultimate end, when senility has completed its effect. Different causes may favor or hasten the evolution of the process (Rohmer).

The ocular complications of this general pathologic condition are frequent: hemorrhages, thrombosis or retinal embolism, opacities of the vitreous, marginal ulcerations of the cornea, and so forth.

The first treatment in these cases is proper hygiene. Those predisposed should avoid overwork and seek rest; they should practise physicotherapy, take exercise with method and moderation, adopt chamber calisthenics, massage, life in the open air, and open windows. Diet should, in general, be moderate and not too heavy or highly seasoned, and easily digestible. The use of meat, alcohol, tea, and coffee should be moderate, and meals should be numerous and small in order to avoid sudden elevations of arterial tension liable to follow copious repasts. Obesity should be met by limiting the use of fat, amylaceous food, and even meat, and by taking fruit and vegetables that contain little nourishment.

The iodids are the most important medicinal agents in cases of arteriosclerosis. Since iodids render the albuminoid molecules more easily oxydizable, they redress one of the nutritive vices of the arthritism, while by lymphagogic action they improve the drainage of the tissues and diminish the arterial tension by reducing the work of the heart (A. Robin). The potassium salts are muscular stimulants and act in this sense upon the myocardium. It is therefore to potassium iodid that one has recourse when there is cardiac asthenia. Otherwise, the sodium iodid is preferable. The dosage should always be very weak, since the treatment must be continued for a long time, and arthritics are, in general, very sensitive to the iodids. One should prescribe 0.25 grm. or at the most 0.50 grm. of the iodid, and that for ten days only. After an interval of ten days, during which other agents for

lowering tension may be administered, the iodid is again given.

The nitrites are vasodilators which diminish the arterial tension while they augment the extent of the vascular area. Sodium nitrite may be prescribed in doses of 0.05 grm. four times a day. Every ten days this remedy may be alternated with sodium iodid. Trinitrin and amylic nitrite are powerful vasodilators that may be prescribed with prudence in cases of embolism or thrombosis of the retinal arteries. Recently, electric currents of high frequency have been much recommended for the purpose of lowering arterial tension.

A milk diet, to which may be added 0.50 grm. of theobromin a day, is the best stimulant of diuresis. As general measures of hygiene to be followed by a person with arteriosclerosis, may be mentioned prolonged stays at the seaside, care being taken while there to lead a placid and regular life. It is remarkable to see how quickly aged urban dwellers become alert at the sea-side. They absorb much more oxygen, and that allows them to burn up organic toxins, while at the same time the emunctories, especially the skin, are much more active. From all this results an easier circulation, with less fatigue of the heart. The wind and the fresh and saline atmosphere stimulate, and the skin reduces undue transpiration. But when the wind is strong and cold, they are best indoors. Sleeping in a recumbent position with open windows does away with all fatigue, while prolonging the cure. Cold baths, as well as all causes of chilling, should be avoided.

The different forms of **anemia** have many relationships to diseases of the eyes, but the treatment of those conditions is too well known to call for discussion in this place. The serious lesions due to **leukocythemia** may be treated advantageously by opotherapy, or rather serotherapy, as well as by radiotherapy.

It is unnecessary to insist upon the treatment of **diabetes** or **albuminuria.** It need merely be said that the

ophthalmic surgeon should always obtain the help of a medical colleague in the management of the ocular complications of these diseases.

The general treatment of **syphilitic affections** of the eye will be described when speaking of mercurial medication. It is nowadays recognized that syphilis is caused by the *spirochæta pallida* of Schaudinn. It represents a type of infection which, at first local, speedily becomes general. Nevertheless, when we see the primary lesion at its commencement (the material proof may be obtained by microscopic examination), it is the duty of the practitioner to apply such local treatment as may suffice to prevent the generalization of this terrible infection. Metchnikoff has recommended under these circumstances prolonged friction of the chancre with calomel ointment. But before that is done, it would be advisable to excise or to cauterize the ulcerated surface, and then to inject deeply several drops of a solution of mercury cyanid, 1 : 1000 and then to make prolonged mercurial inunctions over the whole lymphatic territory, and especially over the inguinal glands, twice a day. These local interventions would be completed by an energetic mercurial course, either by inunction or intravenous injections, alternated with injections of atoxyl or, better, of arsacetin (Neisser).

Syphilitic infection acts not only upon the individual infected, but if cure is not promptly obtained, upon his offspring also by the direct transmission of the spirochæta, as has been proved by the anatomic examination of hereditary syphilitic infants. The specific inheritance may betray itself by a series of typical hereditary stigmata that should be well understood by the practitioner, so that when he meets with them he may resort to proper mercurial medication without delay.

As regards tuberculosis, an infective disease well understood to-day, although it may be questioned whether or not the children of tuberculous parents carry the Koch bacillus, all authors admit that such children are very

readily affected with tubercle and that the heritage they have received from their parents has profoundly damaged their general state. Scrofula may be called the daughter of tuberculosis; but alcoholism or syphilis in the parents may produce lesions apparently scrofulous. It is certain that scrofula is characterized by a condition of profound organic decay, with very marked involvement of the lymphatic system. It is recognized, however, that the lymphatic system is the first part to be involved by all the infections.

Lymphatism should be looked upon as an intermediate stage, which is just as often acquired as hereditary. In infants it frequently originates from defective hygiene and bad feeding. It is marked by insufficiency of the vascular and lymphatic capillaries, predisposing to lymphatic stasis, eruptions, glandular enlargements, and to lesions of all the mucous membranes. In these cases there is perhaps an insufficiency of the suprarenal capsules, such as is known to exist in rickets.

The affections of the eye connected with lymphatism and scrofula are very numerous, and include phlyctenular conjunctivitis and keratitis, blepharitis, etc.

A strict hygiene, open-air life in warm but not damp regions, sea air, saline baths, abundant and wholesome food, cleanliness, hydrotherapy, and gymnastics are indicated in these conditions. **The preparations of iodin** (*lymphagogues par excellence*) are to be advised above all other remedies. They may be administered in the form of iodotannin, alternately with cod-liver oil, which, provided it be well-borne, is, as it were, the specific for lymphatism and scrofula. Whether the oil acts by its contained extract of liver, by its iodin, or by its fat, is a question that it must be left for the future to decide. Quinin, a powerful tonic and vasoconstrictor, given as the *liquor quininæ* or the extract of quinquina, is a valuable remedy in lymphatism. Very good results are obtained from a combination of iron with iodin, as in the syrup of the

iodid of iron, to which may be added with advantage arsenic iodid in the dose of 0.01 grm. to 0.02 grm. a day.

The following formula is capable of rendering real service in cases which prove rebellious to all the measures mentioned above:

Mercury bichlorid	0.05
Potassium iodid	0.06
Alcohol	6.
Syrup of orange flowers	40.
Distilled water	120.

One dessertspoonful three times a day, according to the age of the patient.

The medicine should be taken for five days in succession, and repeated after three days' rest. It may be asked in this connection, does the success of this treatment prove that hereditary syphilis is the cause of scrofula and lymphatism?

All these medicaments, judiciously combined and changed with one another and combined with good surroundings, give happy results, although the latter are temporary, because relapses are the rule in all affections dependent upon a general lymphatic or strumous state. Frequent changes of air are of the greatest importance. A scrofulous subject sent to the sea-shore need stay only until his weight has noticeably increased. Several stays, each extending from one to two months, are likely to do more good than a single prolonged visit. It sometimes happens that a first visit to the sea is badly borne, and in this case it should not be protracted, but it should be remembered that a second visit often proves more profitable than the first.

The mercurials, in the treatment of diseases of the eye, merit particular attention. Empiricism has recognized in mercury a most valuable agent, which must be universally employed despite the fact that its action cannot be explained satisfactorily. When properly administered, the mercurials constitute one of the most precious

weapons in our therapeutic arsenal. By modern pathogenic theories, we are to-day in a position to form a more exact idea as to their therapeutic action.

Mercury acts locally when employed in the form of yellow ointment or calomel in keratitis, etc., as a disinfectant of wounds when the sublimate solution or cyanid solution is used. As a general medicament, it often acts as an antisyphilitic, but in many cases it has a very marked bactericidal, microbicidal, and antiseptic action, by provoking a more abundant production of phagocytes and also in modifying the blood-plasma. These qualities must be considered as among the more important properties of mercury.

It is not correct to state that mercury has invariably a general debilitating effect. On the contrary, in small doses, it exercises a tonic action upon the heart; it augments the blood pressure, increases the number of red blood-corpuscles, and increases the body-weight. It is this peculiar stimulant property of mercurials in almost homeopathic doses which explains the good effects of the mercurial treatment so widely adopted in England in the ocular manifestations of scrofula, etc.

Administered in large doses, however, the action of mercury is quite otherwise. Under these circumstances, its effect upon the heart is without doubt hyposthenic; it lowers the blood pressure, reduces the number of red blood-corpuscles, and lowers the percentage of hemoglobin by its powerful hemolytic action.

For many years the mercurial treatment of the most diverse affections of the eye has passed as the current coinage of therapeutics. Moreover, it was the only one which yielded results before the advent of sodium salicylate, aspirin, and certain other agents, including among them serums, tuberculin, and guaiacol, but one is obliged to return in many cases from the salicylate to the mercury, although nowadays with a little more method and discernment.

Quite recently, Schirmer has praised the treatment of **traumatic infections of the eye by mercurial inunctions,** carried to saturation. This method has been recommended, with much conviction, by Hirschberg in **sympathetic ophthalmitis,** and we have personally adopted the treatment both before the introduction of subconjunctival injections and since.

In these cases mercury acts most likely by a profound modification in the constitution of the blood, which renders the tissues and the liquids of the organism unsuitable for the development of the microorganisms responsible for the traumatic infection and its corollary, sympathetic ophthalmitis. The same effect, it is true, can be obtained by another antiseptic almost equal in virtue to mercury, *viz.*, **silver.** Collargol, or colloidal silver, used as an ointment by prolonged and repeated frictions, stays traumatic or postoperative infections possibly as well as mercurial inunctions. Here, too, antidiphtheritic serum acts similarly.

These facts are significant in showing that mercurial and silver inunctions modify the constitution of the blood by accelerating oxidation, and by neutralizing toxins. Experiments have recently shown that metals in the colloidal state act as oxido-exciting agents, provoking the rapid and complete oxidation of toxins (tetanus, diphtheria, etc.). The effect of these metals upon phagocytosis is equally worthy of study. Hence there is properly suggested the very important point in pharmacodynamics that mercury does not act solely as an antisyphilitic.

Another virtue of mercury which was admitted by ancient writers and which is certainly not without interest is its alterative, resolutive, and dissolving action on the most diverse exudations. In fact, it is known that all mercurial solutions possess a potent hemolytic power; moreover, we now possess the proof, both clinical and experimental, of this dissolving power. In fact, in the calcareous infarcts of the kidneys in mercurial intoxi-

cation one may see a conveyance of dissolved osseous substance arrested by the renal filter. Experiments upon animals have shown that the nephritis consecutive to acute poisoning by mercury is due to an irritation of the excretory elements by calcareous salts carried by the blood.

CHAPTER III.

EXTRAORAL MEDICATION.

Inunctions.

Inunction constitutes the most efficacious and the speediest way of inducing mercurial saturation. Inunction is therefore indicated in cases in which an intense mercurialization of the entire organism must be obtained with the least possible delay; as, for example, in certain cases of iritis, iridocyclitis, or iridochoroiditis, accompanied by violent inflammatory phenomena, whether they be due to syphilis or to traumatic infection, as in sympathetic ophthalmitis.

Inunctions are also invaluable in cases in which, owing to the refusal of the patient or other reason, subcutaneous or intravenous injection is forbidden. For the purpose of securing rapid action, inunction may be combined with hypodermic injection. To these may be added subconjunctival injections when the latter are indicated by the gravity of the local lesions, and when the general administration of mercury has brought about only enough improvement to show that such treatment though efficacious is inadequate. Under such circumstances, one or two local injections may be followed by rapid cure. In such cases subconjunctival injections give a needed impetus at the opportune moment, and have provoked a supreme effort on the part of the *natura medicatrix*.

Although mercurial inunctions have a prompt and efficacious action when carried out under the direction of the practitioner, their effect becomes irregular and illusory when they are left in the hands of the patient. A method so inconvenient and repulsive is always avoided by the

sufferer unless properly guided and disciplined by his medical attendant. Mercurial ointment which has vasogen or lanolin as its base, keeps well and is better absorbed than the familiar Neopolitan ointment. For an adult, 4 grms. and for a child, 2 grms. of the medicament should be rubbed into the skin daily. The proper amount for a single inunction should be prepared and wrapped in wax-paper. Such a packet of the ointment is only opened when it is to be used.

The method is as follows: Before going to bed, the patient selects the place for the application, and then cleanses the skin with wool soaked in alcohol, or, even better, in tincture of soap. The ointment is then rubbed into the skin until it has almost disappeared. Finally, the parts are covered with a sheet of waxed paper and a wool dressing, kept in place all night. Next morning all traces of the soiled ointment are removed by soap and warm water. On the same night the inunction is repeated on some other part of the body. The general effect of the mercury will soon be obtained, but in urgent cases the inunctions may be made night and morning. It is well to avoid using the inunctions on the hairy or exposed parts of the body.

In certain subacute or chronic affections of the eye, frictions may be practised upon the forehead and around the orbit, and their effect may be heightened by hot applications in the shape of poultices or hot wool. These applications, made at night, have the additional advantage of provoking a local hyperemia, which favors absorption. The mercurial poultice, as described, is a good method of treating interstitial keratitis.

Hypodermic Medication.

Many different salts of mercury, soluble and insoluble, have been employed for hypodermic injection. The insoluble salts should be prescribed with great caution, if

not eschewed altogether. At the beginning very small doses should be used, for there exist idiosyncrasies with which we must reckon under penalty of serious intoxication or even of death itself. Many cases have been published of a fatal result following the injection of insoluble salts of mercury, as, for instance, subsequent pulmonary and cerebral embolism. Massive injections must never be made unless the patient's tolerance has been fully established by progressive injections of the soluble salts. Under the conditions described, injections of calomel or of gray oil, made once a week only, may render great service.

In order **to prevent stomatitis and other complications,** the following precautions are recommended by Queyrat:

1. To examine the urine, and if albumin is found, to reject the use of the insoluble salts of mercury.

2. To place the patient's mouth in the best condition, as by prohibiting tobacco, alcohol, and spiced foods, and by using a solution of potassium chlorate (2.5 per cent.), and by cleansing the teeth with soap and a soft brush.

3. To examine the gums prior to each injection. To suspend the injections if the gums are swollen, and also if a nodosity has followed the last injection made into the buttocks.

4. To adopt a careful **technic,** as by employing a needle of 6 cm., plunging it into the muscular tissue, and by refraining from injection in case blood issues from the instrument.

5. To avoid the production of postoperative nodules, since these, by storing up the mercury, frequently cause stomatitis. This is best effected by making the injection into the muscle, and by not allowing the mercury, while withdrawing the needle, to diffuse along the injection-track.

If **stomatitis** supervenes, it must be treated from the first by the following measures:

1. By the absolute suspension of all methods of mercurial treatment.

2. By building up the patient's constitution with suitable diet (milk if there be albuminuria), quinin, coffee, etc.

3. By giving tone to the heart by injections of caffein.

4. By irrigating the mouth every hour with solution of potassium chlorate (2.5 per cent.), carbolic lotion (1 per cent.), or neutral hydrogen peroxid, used pure or diluted with a quarter part of boiled water.

5. By painting any ulcerations that may be present with tincture of iodin.

6. By injecting sea-water or colloidal platinum to combat secondary infections and the intoxication of the organism.

7. If the nodules and the stomatitis do not improve, by extirpating the former, after radioscopic examination, for the purpose of assuring oneself that they are caused by a collection of mercury and not by effusion of blood. The elimination of the mercury may be favored by sulphur baths and the administration of potassium iodid.

The following formula may be used with all confidence, provided it is prepared aseptically:

Calomel	0.5
Camphor	1.0
Guaiacol	1.0
Sterilized olive oil	10.0

Each dose of 1 c.c. contains 5 cgrms of calomel. The camphor and the guaiacol render the injection almost painless.

The gray oil is also reliable. It is made as follows:

Purified mercury	40.0
Sterilized lanolin	25.0
Oil of vaselin	q. s. 1 or 100 c.c.

Each syringe of 1 c.c. contains 0.40 volumes of metallic mercury.

Serious mishaps are never met with after the injection of soluble salts if the patient is seen daily or every other

day, for the treatment can be at once suspended if there be any reason for thinking that it is not well tolerated.

The earliest **symptoms of intoxication** complained of by patients undergoing the injection of soluble mercurial salts are pains in the abdomen, colic, cramp in the stomach, sometimes even bloody stools, and rarely vomiting. The first cases of intolerance observed by the writer after the hypodermic injection of a centigram of sublimate occurred in two gouty subjects, who both complained of colic and bloody stools. Since this observation, attention has been directed to the matter, and this untoward action has been more frequently noticed. It is probable that such idiosyncrasy is due to an inadequacy of the renal functions (Darier).

Young subjects in excellent health may show this intolerance toward mercury, no matter what form is given. Most disastrous results would occur to these patients if instead of an ordinary dose of a soluble mercurial salt, a massive injection of calomel or of gray oil or of the yellow oxid were given. Even death might supervene.

It should be said that experience has shown that the intolerance is merely relative, and that by employing small doses and gradually increasing them, it is possible to accustom the patient to support sufficiently large doses of mercury. Instances of intolerance, it is true, are rare, but their existence should be recognized. The physician should always distrust the advice of those who claim that 5 grms. of sublimate may be injected at a sitting.

In certain very grave cases one may progressively reach 2 cgrms. of sublimate or 3 cgrms. of mercury cyanid, but such doses can rarely be tolerated for long without inducing colic and diarrhea, in which case the amount must be reduced immediately.

It is well to note that in almost every case the toxic effects of mercury do not interfere with treatment. On the contrary, improvement in the eye disease is often more

rapid and manifest following this involuntary intestinal disturbance.

There is not a great deal to choose between the many **soluble salts of mercury** that have been recommended **for injection.**

Injections of the **oil of biniodid**, to which Professor Panas gave the preference for several years, have yielded good results, although they are neither less painful nor more active than injections of an aqueous solution of the cyanid. On the other hand, they are less easily asepticized.

Watery solutions of the biniodid with sodium iodid and of mercury dibromid are now praised as causing very little pain.

During the last fifteen years the writer has given the preference to the **cyanid**, on account of its solubility, its rapid absorption, and the slight amount of pain produced by its injection. It has, moreover, the advantage of not precipitating cocain, as does the bichlorid, so that by adding cocain or acoin, the injections may be rendered momentarily painless; and acoin has a deep and very lasting anesthetic action. The other cyanids of mercury have more often provoked the phenomena of intolerance and intoxication than the simple cyanid which is also more stable. more soluble, and more easily obtained in most drug stores.

The injections are made with a 1 per cent. solution, which is injected progressively until 1 cgrm. of cyanid is used every day. Intensive effects are thus obtained very quickly, but symptoms of intolerance may be produced at the end of several days.

Before each injection, the gums should be inspected, and the patient asked whether he has experienced any colic or diarrhea. As soon as the least colic is felt (what may be called the "reactional limit" of the treatment) the dose must not be increased. It should be remembered that intestinal complications are instantly cured by an injection of morphin.

Intravenous Injections.

The intravenous injection of the soluble salts of mercury constitutes the last word in the rational therapeutic application of mercury. The author, after a long period of skepticism with regard to its value, has become during the last fifteen years a determined partisan of the method, which he now adopts almost to the exclusion of the other modes of administration.

Clearly, intravenous injection is a delicate and even difficult proceeding for the inexperienced, but practised by a physician trained in the principles of antisepsis and of serious clinical experiment, it presents advantages of the first order, such as absence of all pain and of all local lesions (infiltrations, nodosities, etc.). It is also rapid, sure and precise in action, and is devoid of late secondary effects, such as may sometimes occur in intramuscular injections.

The solution to be employed should be limpid and absolutely aseptic, and above all, free from cocain or any other analgesic liable to act too powerfully upon the heart and the nervous centers. Experience has demonstrated the harmlessness and efficacy of the following solution:

Mercury cyanid	0.33
Sodium chlorid	0.08
Sodium phosphate	0.07
Sterilized and distilled water	100.

Two to three centimeters of the solution are to be injected into one of the veins at the bend of the elbow, and care should be taken to make the injection very slowly.

The author has made thousands of intravenous injections without the least complication, except rarely a slight local swelling when a little of the liquid has passed outside the vein. The penetration of large bubbles of air into the veins of the arm is without danger. There has even been injected unwittingly a syringeful of air without causing the least inconvenience to the patient. Extremely nervous patients may feel some apprehension when the

first injection is made, especially if the liquid be pushed too quickly into the vein and they happen to perceive that the practitioner himself is not too sure of his work. But this trifling and rare inconvenience is largely counterbalanced by the very great advantages of intravenous injections.

The technic of intravenous injections is simpler and quicker than that of hypodermic injections. The patient need never be undressed. Individuals in whom the veins are difficult to find are uncommon, but in them, *faute de mieux*, we must resort to subcutaneous or intramuscular injections.

In order to make the vein stand out we first apply one or two turns of a tight bandage to the upper part of the biceps muscle, and, during the production of the venous stasis, the part to be operated is cleansed with wool soaked with chloroform, alcohol, or sublimate. The needle, which should be fine and made of iridized platinum, is brought to the glowing-point in a flame. The patient is seated opposite the practitioner, with his extended arm resting upon the latter's knee. The vein is steadied by the index finger or thumb of the surgeon's left hand, while with the other the needle is thrust obliquely through the skin into the vein in the direction of the blood-current—that is to say, from below upward. Before making the actual injection, the piston is slightly withdrawn from its socket for the purpose of seeing whether blood rises in the barrel, and to that end the instrument should not be quite filled with the mercurial solution, so as to allow the piston a little play. If upon slight aspiration blood rises in the syringe, then the needle must be in the vein. The bandage around the arm is next slackened, and immediately the liquid is injected slowly into the vein, a process that should occupy four or five seconds. Occasionally the patient speaks of a feeling of stimulation, and sometimes complains of a peculiar taste in the mouth.

After the injection is made, the needle should be quickly withdrawn. The puncture is compressed with a morsel

of wool, and, finally, the tiny orifice made by the needle is hermetically closed by means of a drop of collodion. After a certain number of injections, it often becomes necessary to change the vein selected in the first instance, or to return to hypodermic injections, so as to give a rest to the veins, which might otherwise become obstructed.

FIG. 1.—Intravenous Injection.

Injections should be made alternately into each arm, so as not to make unduly great demands upon individual vessels. After many punctures, the veins may become thickened and so narrow that it would be difficult or impossible to make fresh injections. This is, indeed, the chief objection that can be raised against the intravenous method. It is, however, always possible to resort to the hypodermic route whenever the intravenous method ceases to be available. After a month or two of rest, when the veins have

again become permeable, the intravenous injections may once more be adopted.

Complications are excessively uncommon, and practically the only one known is that caused by an injection clumsily made outside the vein. Under these circumstances, a veritable hypodermic injection has merely been made, but into a part of the body richly endowed with vessels and nerves and consequently very sensitive. A slight amount of practice will suffice to avoid this inconvenience, since it is easy to see when the liquid does not enter the vein and diffuses beneath the skin. An indurated swelling then forms. When this occurs, it is better not to persist, but to withdraw the needle and make the injection into the other arm.

Infective **phlebitis** has never been observed to follow the injection, and would be scarcely possible unless the needle had not been previously heated. During the last fifteen years the author has never witnessed any serious accident. He has heard of an injection of cocain, given by error, which provoked prolonged syncope, but not a fatal result. Such mistakes might occur equally in the hypodermic method.

There have never been seen complications produced by intravenous injection more serious than those of hypodermic injections. It is nevertheless certain that the two methods, and especially the first, should be applied only by practitioners of experience. Modern medicine entails great responsibilities, to meet which the practitioner must bring profound knowledge to bear, acquired at the bedside of the patient.

Of Baccelli, the promoter of intravenous injections, Virchow wrote: "That which Lister did for the surface of the body, Baccelli has done for the blood." Baccelli says that when injected directly into the veins, the medicaments come into immediate contact with the virus which infects the blood, and are carried with lightning rapidity to all organs and tissues. In the syphilitics, the action of subli-

mate upon the vascular walls, the favorite site of luetic changes, is prodigiously rapid when it is employed by intravenous injection. In obliterating endocarditis notably these injections act so promptly and powerfully that they immediately reopen the vessels.

These several considerations substantiate the advantages of intravenous injections, the *technic* of which is so simple. Every kind of accident can be avoided by a little attention and care on the part of the practitioner. With a better knowledge of the method the applications of intravenous injection have become wider and wider, so that it is now applied not only to sublimate but also to all other remedies. By their employment the practitioner may judge with mathematic exactitude the dose that enters into action. The remedies dissolved, carried directly by the circulation, develop their action with astonishing rapidity.

Whether hypodermic or intravenous injections of mercury cyanid be adopted, one must always inquire before making a fresh injection whether the patient has suffered from colic or diarrhea after the last injection, and in that case the doses must be diminished or the injections be made less frequently. It is advisable after a first series of injections to allow a month for repose before resorting to a second or even a third series. In certain attacks of slow and insidious evolution, such as interstitial keratitis, iridochoroiditis, and choroiditis, it may be necessary to practise in the course of two or three years more than 200 to 400 injections.

In order to prevent rapid tolerance of the organism to medicaments, it is sometimes advisable to modify the method of application or the particular salt employed. Such alternations of medicaments are occasionally very useful. For example, a first series may be made of thirty to forty intravenous injections of 0.01 of mercury cyanid, and this may be followed, after an interval of a month, by a second series of biniodid (0.01 to 0.03, progressively).

Lastly, should a third course be deemed necessary, as when dealing with a form of tertiary syphilis accompanied by rebellious cutaneous complications or deep osseous changes, we may call to our aid a new and interesting salt of mercury, namely, **enesol** or **salicylarsenate of mercury.** This product, at once very soluble and rapidly eliminated by the urine, is seventy times less toxic than the biniodid. It contains 38.46 per cent. of mercury; 1 cgrm. of enesol is equal to 0.0087 of mercury biniodid; 3 per cent. solutions of enesol may be injected almost without pain. One c.c. contains 0.0115 of metallic mercury, which corresponds with 0.026 of the biniodid.

The timely combination of mercury and arsenic may produce better results than arsenic by itself, the action of which upon anemia must not be lost sight of in this connection. Intravenous injections, first of 2 c.c. and then of 3 c.c., may be made without hesitation and with favorable therapeutic results. In the same way the 1 : 1,000 solution may be employed subconjunctivally with less pain than is produced by the cyanid.

Resume.—When it is desired to obtain a prompt and complete result with mercury in diseases of the eye, treatment should be by inunction, carried out under the immediate superintendence of the practitioner, and by hypodermic or, better, by intravenous injections, which permit one to ascertain the individual susceptibility and to avoid grave intoxications. After such treatment, there may be resort to massive injections of the insoluble salts of mercury which, since they need be made but once a week, allow the patient a greater degree of freedom. Finally, when the desired result has not been produced by the means named above, it is advisable to employ local applications, as by the subconjunctival injection of mercury cyanid or enesol.

Arsenical Preparations.—That mercury is the true antidote to syphilis is well known. It is capable not only of causing all symptoms to disappear, but also of destroy-

ing the actual virus, a point fully demonstrated by Neisser and Metschnikoff's experiments upon monkeys. Moreover, Uhlenhut, Metschnikoff, and Neisser have established the fact that certain arsenical preparations are able to destroy the syphilitic poison completely without harm to the animal experimented on. Thus **atoxyl,** injected into the monkey from five to thirteen days after the inoculation of syphilis, prevents the disease from breaking out. Most of the animals remain in good health, and, a significant fact, may again contract the disorder. In addition to the preventive action, atoxyl yields an obvious curative action in syphilis in monkeys, be it early or late. In man atoxyl acts in the same way, although not to the same extent as mercury in the primary and secondary stages. On the other hand, in malignant tertiary syphilis, atoxyl has sometimes yielded remarkable results, especially in those who bear mercury badly.

Unfortunately, as the result of treatment by atoxyl, atrophy of the optic nerve has been observed, due probably to impurities in the particular preparation employed. It is therefore not prudent to recommend atoxyl. This had led Ehrlich to seek another arsenical preparation, and to recommend **arsacetin,** which is ten times less toxic than atoxyl, and which in solution does not decompose even after prolonged boiling.

In the monkey, arsacetin manifests a curative action superior even to that of atoxyl. After many experiments upon monkeys, Neisser has for some time used arsacetin for the cure of syphilis in his patients. It acts like atoxyl, but without provoking optic atrophy or other nervous disturbances. Although arsacetin is inferior to mercury in its therapeutic effects, yet it possesses a distinct action, and may render great service when alternated or combined with mercury. In patients affected with myocarditis or nephritis, it is better to avoid arsenical treatment, or, at least, to employ it with much circumspection.

Arsacetin is prescribed as follows: 0.50 of the remedy,

as a 10 per cent. solution, is injected on two consecutive days in each week, and the injections are repeated until 12 grms. of the medicament have been administered. At the same time mercury may be given by injection of gray oil or of calomel, 40 per cent. (Neisser). Ehrlich has shown that different preparations of arsenic do not act in the same way upon the trypanosomes.

An alternative method of treating syphilis of the eye is by employing iodin, as by administering **large doses of potassium iodid,** which acts particularly well in tertiary manifestations. This may be combined with a series of **pilocarpin injections,** which produce salivation, transpiration, and an augmentation in all the secretions, and consequently a rapid elimination of toxins and of medicines which have been given in excess. Certain preparations of iodin, solutions of very unstable mineral salts, when injected into the veins, bring nascent iodin into contact with the blood, and thereby possess a powerful therapeutic action as regards syphilis, tuberculosis, and scrofulosis without provoking the least symptoms of intolerance. In this way a **daily injection of 0.08 of iodin** may be made, care being taking to add a little caffein as in intravenous injections of **sodium salicylate** (Mendel).

As a general method, the administration of medicaments by intravenous injection may render great services in many affections. Thus, Mendel has obtained favorable and rapid results by injecting 0.5 of **sodium salicylate** twice a day in rheumatism, and thereby has avoided accidents caused by doses of 4 to 6 grms. of the salicylate taken by the digestive tract (see rheumatic iritis).

Formula:

Sodium salicylate	10
Caffein	1
Sterilized water	100

Three to 6 c.c. to be injected every day.

Quinin applied intravenously may be very useful in

the ocular complications of pernicious fevers. The following formula is recommended by Baccelli:

Quinin hydrochlorid	1
Sodium chlorid	7.5
Sterilized water	100

Three to 5 c.c. to be injected daily.[1]

The intravenous injection of quinin has a very favorable action in many syphilitic affections. Nappe has related fifteen cases of this kind. The fact becomes the more interesting when it is remembered that in some patients it is often necessary to suspend mercurial treatment.

Colloidal silver, collargol, and the other **metallic ferments** have a surer and more rapid action when applied intravenously than when used as inunctions or when injected beneath the skin.

Antitoxic serums and tuberculin have been injected into the veins by Baccelli and by others, but it is by no means easy to make such an application in children. **Antitetanic serum,** which should be given as quickly as possible, may with advantage be injected into the veins, while **antiplague serum** should always be administered in that way.

The intravenous applications of **iron, arsenic,** and **iodin** are of an interesting nature.

Hetol (sodium cinnamylate) in doses of 0.01 a day by intravenous injection has a very favorable action upon the heart in tuberculous affections.

Drugs contraindicated in intravenous injection are such powerful agents as strychnin and pilocarpin, and most of the anesthetics.

Rachidian and Epidural Injections.

When it is desirable to act more directly upon the nervous centers, the injection of drugs by the rachidian or epidural route is likely to prove of great practical value.

[1] This is equivalent to 0.30 to 0.50 of quinin. If this dose is exceeded, the phenomena of intoxication may be observed, namely, bitter taste in the mouth, vertigo, ringing in the ears, small pulse, etc.

Bier-Tuffier's method of rachi-anesthesia has rendered great service in cases in which an operation has to be performed on the lower part of the body and general anesthesia is contraindicated. In this connection, however, it must be noted that paralysis of the sixth cranial nerve has been observed not infrequently after this method of anesthesia.

Lumbar puncture, discovered by Corning, of New York, has been introduced into practice by Quincke. It is most useful in the diagnosis of diseases of the nervous centers, and may even yield valuable therapeutic results in the same affections. Several cases of stasis optic neuritis have already been improved or actually cured by the operation, but the rachidian route of administering medicines or serums has scarcely been explored as yet, although cases of tabes accompanied by abdominal or vesical crises have been promptly relieved by the **intrarachidian injection of colloidal mercury.** At the present time it seems desirable to adhere to the **method of Cathelin,** who injects the solutions not into the medullary canal itself but only into the sacral opening lying below the ending of the dural culdesac (**epidural injection**). By this plan he obtains a less energetic local action as well as one that is less dangerous than that obtained by intradural or rachidian injection. A needle, 6 cm. in length, is thrust into the membranous triangle which connects the coccyx to the sacrum, and 5 to 10 c.c. is injected of a solution which contains sodium chlorid and cocain, 2 per cent. In this way one obtains an analgesia, more or less marked and involving more or less the lower half of the body. Many cases of incontinence of urine have been cured by these means.

As regards the ophthalmologist, the sacral route may be useful for administering mercurial injections in tabetic atrophy of the optic nerve, when such is accompanied by vesical crises or incontinence of urine.

CHAPTER IV.

INTRAOCULAR AND SUBCONJUNCTIVAL INJECTIONS.

The further we advance, the more precise we become, so much the more we strive to apply a remedy to the diseased organ, and to limit, as much as possible, the fight of the medicament against the pathogenic agent to the infective focus itself.

Intraocular injections have their special indications. They are employed in those desperate cases in which everything has been tried to save an eye which is believed to be absolutely lost. Unfortunately, they have occasionally been followed by grave consequences, which naturally make us hesitate to use them in every-day work.

Haab, of Zurich, has recently recommended the introduction of **iodoform** into the eyeball, for the purpose of preventing or combating infection, panophthalmitis, or sympathetic ophthalmitis. Such a serious procedure should be adopted only in grave cases, in which there is no hope of saving the eye by less active measures. Indeed, several cases have been reported in which sympathetic ophthalmitis occurred after iodoform had been introduced into the wounded eye.

On the other hand, **subconjunctival injections** never lead to loss of sight, and their only disadvantage is the pain they are likely to cause.

Empiricism is not the sole basis of local therapeutics. There is a foundation of important anatomic and physiologic laws, which are now adopted not only in ophthalmology but also in every branch of medicine. Minor surgery now demands a large share in affections formerly looked upon as belonging to the realm of the internist. Even affections that depend upon a general disease such

as syphilis, tuberculosis, or rheumatism have, aside from their general indications, local treatment of the first importance.

A primary or secondary infection localized in an organ so important as the eye should, if possible, be attacked locally, without at the same time losing sight of the general indications furnished by the malady.

Instillations of sublimate, 1:1000, in the conjunctival sac, already practised by Scarpa, have recently been reinstated by Gallenga, who has obtained good results by this means.

Rationale.—To cause the antiseptic agent to penetrate into the infective focus itself or into its immediate surroundings, so as to irrigate and to render aseptic all the lymphatic territory in which the morbid process is billeted, should be the aim of treatment in every infective disease of a well localized character. By the arrangement of its lymphatic system, the spaces of which are in intimate communication, the eye lends itself admirably to such local treatment. It is well known that even a very dilute solution of atropin, when dropped into the conjunctival sac, is resorbed by the lymphatics, and penetrates into the aqueous humor. By instilling a few drops of this aqueous humor into the eye of another animal, mydriasis is produced. By injecting beneath the conjunctiva a solution of fluorescein, one may see not only the aqueous humor become green but also the sector of the cornea and even of the crystalline lying next to the site of injection take on a pronounced green color.

In face of these facts, is it not logical to conclude that the most certain means of making soluble remedies penetrate the interior of the eye is to inject them beneath the conjunctiva?

General Effects.—Local therapeusis is indicated whenever it is necessary to act with promptitude and energy. There is no better example than sympathetic ophthalmitis, of which the sole treatment until recently has consisted

in enucleation and mercurial salivation. No matter what pathogenic theory of sympathetic accidents be accepted, if general mercurial treatment be efficacious, the local application of mercury will *a fortiori* be even more so, a fact already proved by cases reported by Gallenga, Secondi, Reymond, Abadie, Rogman, Coppez, Darier, Sourdille, and other writers. Had subconjunctival injections done no more than to establish, under certain conditions, the curability of **sympathetic ophthalmitis,** they would have constituted a precious therapeutic advance.

In secondary infection, late, traumatic or postoperative, taking place through vicious cicatrices, filtering cicatrices, subconjunctival injections have yielded results which the older methods could not secure with any like the same rapidity. These facts constitute, in a sense, the purest and most conclusive experience, which show the powerful efficacy of antiseptics injected beneath the conjunctiva in well-localized infections free from coincident phenomena, liable to obscure observation. The simplest infection of the eyeball itself is that produced by an infected erosion of the cornea. The ordinary form is the infective ulcer of the cornea. In such cases the subconjunctival injection of mercury cyanid is the most certain as well as the most efficacious antisepsis.

With serotherapy, the galvanocautery, and subconjunctival injections, every **infective ulceration of the cornea,** taken in time, should be promptly cured, which was assuredly not the case with the older remedies.

Subconjunctival injections have, as it were, an elective **action upon the choroid.** In choroiditis or choroido-retinitis, which is central, recent, and not too deep, the truly remarkable action of the injections may be studied almost mathematically. In fact, the metric scales allow of the progressive amelioration of vision being controlled exactly, while, on the other hand, the ophthalmoscope shows us with precision how the anatomic lesion evolves and retrogrades. Senn has recently published a long

study dealing with the action of subconjunctival injections in cases of **myopic choroiditis.** He recognized a specific action under these circumstances in this method of local treatment. Having made comparative trials with sodium chlorid and mercury cyanid, Senn concludes that the latter is clearly the better, and he recommends a 1 : 5,000 solution as at once the most active and the least painful to employ.

It should be the same for diseases of the optic nerve, especially in certain cases of **retrobulbar neuritis,** although there anatomic considerations warn us that we cannot expect *restituo ad integrum* when too large a nnmber of the nervous fibers has undergone atrophy. We cannot look forward to a positive result except in cases in which the optic fibers have been merely compressed or paralyzed temporarily. In other words, cure can be looked for only in cases in which the infective or toxic inflammatory process is recent and has not determined complete atrophy.

In gray *tabetic atrophy* the results amount to practically nothing. In *white atrophy*, the result of old inflammatory processes, sight may sometimes be slightly improved, but only to a limited degree. In optic neuritis symptomatic of a serious intracranial affection, the effect of the subconjunctival injection of sublimate has sometimes been very manifest, but nearly always ephemeral. In such cases the cause of the disease must be suppressed.

The indications for subconjunctival injections would be singularly incomplete did we fail to mention **diseases of the iris and ciliary body.** In traumatic ectogenous infections, characterized by iritis, iridocyclitis, and even iridochoroiditis, the effects of local treatment are superior to those of general treatment, unless it be by serotherapy The same is true of all the numerous diseases produced by endogenous infection, as from syphilis, tuberculosis, rheumatism, blenorrhagia, etc., when the effects of general treatment have lost their potency. In many of these

affections subconjunctival injections often prove themselves a most valuable auxiliary to general treatment, although by themselves they do not constitute a complete treatment. In the different syphilitic manifestations in the iris and the ciliary body, reliance may be placed upon the good results that may be obtained by the subconjunctival injection of sublimate. Several cases of gummatous iritis, treated by this means at the right moment, have been cured with great rapidity, and it has been the same in certain cases of long-standing iridochoroiditis which proved rebellious to persistent general treatment.

Contraindications.—In acute and violent syphilitic iritis general treatment is the first indication. The same applies to **all the acute inflammatory processes of the iris and the ciliary circle,** whether their etiology be syphilis, rheumatism, or otherwise. Prolonged clinical observation has led to the conclusion that, for the time being, subconjunctival injections are contraindicated when there is present circulatory stasis, rendering absorption of medicaments difficult or impossible by the obstructed lymphatics. Under such circumstances mercury cyanid injected beneath the conjunctiva will act as an irritant, more harmful than useful, and producing intense pain and chemosis.

This important contraindication once established, by following with care the clinical indications, and by selecting the most favorable moment and the best medicament, we may not only avoid the inconveniences spoken of above but may also obtain very favorable results.

The action of subconjunctival injections has been theoretically explained on physiologic grounds. According to Wessely, they act simply as a revulsive which provokes by reflex action an intraocular vasodilatation. Granted that this be true for injections of sodium chlorid, it is certainly not for injections of adrenalin, cocain, dionin, tuberculin, and antidiphtheritic serum, or for injections of mercury cyanid in syphilis, sodium salicylate in rheumatism, of hetol, iodoform, or guaiacol in tuberculosis.

Every one of the injections named possesses in addition to its revulsive effect also an action which can be described as truly specific.

Wessely sums up the result of his work in the following words:

"In rabbits, subconjunctival injections do not act upon the intraocular fluids by osmosis any more than they do by accelerating the lymphatic flow or by provoking an afflux of leukocytes. They act simply as do all other revulsives when brought into contact with the conjunctiva. Their action manifests itself reflexly upon the vessels of the ciliary body, which become dilated and allow of the transudation of a greater quantity of albumin and consequently of antibodies of the most various kinds. From the therapeutic standpoint, they should not be employed in cases in which the natural reaction is sufficiently strong, as in serious ulceration of the cornea, acute iritis, etc. On the contrary, when we have to do with a chronic process, not associated with too marked a reaction, as in chronic iridocyclitis and in keratitis at the beginning and toward the end, it is advisable to provoke a salutary reaction by means of subconjunctival injections."

It is to be noted that precisely the same indications for the employment of subconjunctival injections are furnished by clinical observation.

The principle should be fully recognized, namely, that the subconjunctival injection is to be regarded neither as a panacea nor as a trivial intervention. It is an exceptional means, a little quasi-surgical operation, as it were, which should be adopted in earnest only when simpler means will not suffice or when a rapid and intensive effect must be obtained, as in cases in which grave complications are apprehended.

The following is the general **course of events after a subconjunctival injection** has been administered:

1. At first there ensues local irritation due to removal of the aqueous humor through the canal of Schlemm and

the spaces of Fontana from anisotonicity of the fluids (A. Darier).

2. This irritation sets up, moreover, hyperemia of the ciliary body and consecutively the fresh secretion of aqueous humor, richer in albumin and antibodies (Wessely).

3. An isotonic equilibrium is thereby brought about, which allows of the resorption of some of the substances injected, which then act locally, according to their individual pharmacodynamic properties, as anesthetics, mydriatics, lymphagogs, antiseptics, etc.

This way of explaining the action of substances injected beneath the conjunctiva should lift local treatment from the apathy into which it has fallen. The method is now practised not only by ophthalmologists but by all medical men, at whose head is to be found the illustrious Bouchard.

The technic of subconjunctival injection is very simple. It requires but a Pravaz syringe, armed with a fine curved needle of platinum-iridium, which should be sterilized in a flame just before it is used. The solutions for injection must also be sterile, a point upon which it is scarcely necessary to insist; and when the temperature is low, they should be warmed to 32° or 36° C. This simple precaution renders them at once less painful and more readily absorbed. Instruments are quite unnecessary. Neither speculum nor forceps is called for, and indeed it would only serve to frighten the patient.

The patient is directed to look downward and inward as far as he can, and by pushing the upper eyelid backward, the surgeon exposes the upper and outer equatorial portion of the eyeball, which presents the largest and least sensitive part of the ocular conjunctiva. The needle is then introduced superficially under the conjunctiva, as far as possible from the cornea, and tangentially to the surface of the eyeball, so as to pass beyond the equator of the globe. The liquid injected must not be allowed to return to the limbus, where it might detach or obstruct the pericorneal vascular circle. Trophic disturbances of the

cornea and conjunctival cicatrices may follow injections practised too near the cornea. Again, when a full syringeful of liquid has to be injected, care should be taken to pass the needle far backward, so as to inject the fluid into the retrobulbar tissue, well behind the equator of the eyeball.

By the use of cocain-anesthesia and a fine and well-sharpened needle, the prick of the instrument is generally not felt. A few drops of a 1 per cent. solution of acoin, added to the liquid for injection, renders the operation painless for a time that varies directly with the quantity of acoin and inversely with the strength of the solution chosen for injection.

Subconjunctival injections should not be repeated too often. Nature must be allowed time to effect repairs. Fresh injections should not be undertaken, unless the indications are very urgent, as long as swelling or chemosis is present.

Injections of sodium chlorid up to 2 per cent. are so quickly resorbed that they may be repeated every day or every second day.

Indications for Subconjunctival Injections.—The first indication was given by Rothmund, who many years ago recommended the subconjunctival injection of sodium chlorid for the clearing of **corneal leukomata.** This indication is still in force for recent corneal infiltrations, but for old leukomata and for calcareous infiltrations better results are obtained by alternating applications of dionin with injections of lithium benzoate, according to the following formula:

Lithium benzoate	2
Sterilized water	100

One c.c. to be injected once or twice a week.

In some cases of **interstitial keratitis** at the beginning or the end, as well as in infiltrations of the cornea in some of the less serious cases of infective keratitis, a rapid clearing

of the cornea may be sometimes obtained by the injection of sodium chlorid:

Sodium chlorid	2
Sterilized water	100

One c.c. to be injected, according to the intensity of the reaction, every day, every second day, and then twice and, finally, once a week.

When we have to deal with deeper infection, as **hypopyon keratitis,** it will be advisable to use the cyanid of mercury after having first made an experimental injection of sodium chlorid:

Mercury cyanid	0.02
Sodium chlorid	2.00
Sterilized water	100.00

One c.c. to be injected every two or three days.

This 1 : 5000 solution is usually well borne, especially if a few drops of acoin be added to it. Some surgeons, however, prefer to inject one or two drops of a 1 : 1,000 solution. The result is almost the same. But it is better not to employ concentrated solutions, at least without special indications, such as is furnished by **sympathetic ophthalmitis,** when one may, after enucleation, inject into the depths of the orbit as much as 1 c.c. of a 1 : 1,000 solution of mercury cyanid (Abadie).

The 1 : 5,000 solution is that employed in the treatment of macular **chorioretinitis,** myopic or otherwise.

The following solution is useful in rheumatic **episcleritis or iritis,** when after some intravenous injections of **salicylate,** inflammatory phenomena are mitigated, and it is desirable to effect a rapid cure:

Sodium salicylate	2
Sterilized water	100

During the last few years potassium iodid has been much praised in the treatment of **opacities of the crystal-**

line lens. Badal recommended it to be used by means of eye-baths. Verdereau and Pflugk have obtained better and more rapid results by injecting subconjunctivally twice a week, 1 c.c. of the following solution:

Potassium iodid	1
Sterilized water	100

The same solution is of service in gummatous **infiltrations of the sclera,** when it may be used alternately with mercurial injections, but at an interval of several days, so as to avoid the formation of the biniodid salt.

A preparation of iodin which possesses very valuable indications is to be found in the **iodate of sodium,** which can be used without pain, and which has a quality that neither potassium nor sodium iodid possesses:

Sodium iodate	0.1
Sterilized water	100.0

Sodium iodate is a remarkable reducer of tension in many conditions—as, for example, in **glaucoma** symptomatic of any kind of iridocyclitis, in glaucoma from *seclusion pupillæ* following tuberculous keratoiritis, syphilitic iridocyclitis, in glaucoma from too rapid swelling of the needled lens, or from traumatic cataract, and, finally, in certain cases of absolute glaucoma, in which there has been practised the operation of iridectomy without success. In all these cases, after one to three subconjunctival injections of 1 c.c. of sodium iodate (1 : 1,000), tension may fall in the course of three days from +3 to +1 or to normal.

Those who see in subconjunctival injections merely a means of stimulation or of counterirritation have vaunted the employment of one and the same therapeutic agent for the most varied affections. Thus Peschel has praised the almost universal use of alcoholized water, 15 per cent. Exactly the same effects have been claimed for injections of sodium chlorid.

Injections of sterilized air would yield identical results, but they should be specially reserved for affections of

the cornea and the iris which are believed to be of tuberculous origin. In order to make these injections, one employs a syringe, the capacity of which is 3 c.c. It is filled with air by means of simple aspiration while the middle third of the needle, which is of platinum, is kept in the flame of a spirit lamp.

Injections of sterilized air are especially indicated in scrofulous affections of the eye, which, however, is no positive proof that such affections are of a tuberculous nature. They are useful in cases of severe phlyctenular keratoconjunctivitis, accompanied by photophobia. In such cases, as also in traumatic keratalgia, an injection of air twice a week brings about the prompt disappearance of the photophobia and a decided improvement. The treatment, indeed, is demanded by patients. In trachomatous pannus, injections of air would be useless. The interstitial keratitis of hereditary syphilis is little benefited by injection of air; but when the affection is due to tuberculosis, it is markedly improved. Episcleritis and sclerotizing keratitis of tuberculous origin are also benefited.

Guaiacol.—The true specific in tuberculous affections of the eye is guaiacol. This is so true that one can be almost certain that an episcleritic nodule or an iridic lesion, which has been treated in vain with mercury or salicylate, is really tuberculous if it improves or is cured after two or three subconjunctival injections of the following solution:

Guaiacol cacodylate	.2
Sterilized water	100

The **guaiacol reaction** is possibly even more conclusive than the cuti- or the opthalmo-reaction.

The specific action of guaiacol on tuberculous lesions of the cornea, sclera, and conjunctiva is all the more useful in that the subconjunctival injections are scarcely painful and not painful at all if two or three drops of alypin be added.

The serums—antitoxic, antitetanic, antidiphtheritic, etc.—may be profitably employed as subconjunctival in-

jections. This method of administration has a marked advantage over that by the mouth. Subconjunctival injection has the advantage possessed by all local interventions, and will at the same time bring about hyperemia of the ciliary body, together with a more copious afflux of antibodies into the aqueous humor (Wessely).

CHAPTER V.

SERUM-THERAPY.

Modern ideas of treatment have been completely revolutionized by the dominant part played by infection in pathology. At first, antiseptic agents were sought as a means of combating the infective elements, and then in certain cases, when an attempt was made to render the organism more resistant by means of attenuated viruses, there was found in antitoxins and antibodies the means of neutralizing microbic intoxications; and during the last few years new therapeutic vistas have been opened by the theory of phagocytosis.

Phagocytosis, which may be estimated by studying, according to Wright's methods, the **opsonic index** of the blood, is one of the principal means whereby the organism defends itself against the inroads of infective agents. It is, however, a mistake to attempt to make a universal explanation by phagocytosis. The macrophages and the microphages undoubtedly form the *troupes d'élite* of the sanitary police of the body, but it is now recognized that each of our elements has its own proper means of defense, which play an important *rôle*, and it is the collectivity of all the elements of defense that constitutes what may be called the "vital energy of the tissues."

The aim of treatment should be to stimulate this vital energy in the fight against such infective maladies for which we do not at present possess a specific **antitoxic serum.** The ideal method of treatment would be to oppose each infective disease with a specific serum, in accordance with the laws so well established by Pasteur.

At present, we possess few sera the action of which is really specific. Meanwhile, ought we not to find out

whether certain antitoxic serums do not possess, in addition to their purely specific action, therapeutic properties that may be utilized in infections of a less serious nature or that have some analogy with the specific infections spoken of above?

When an animal has been actively immunized against a toxin as potent as that of diphtheria or tetanus, all the anatomic elements are placed in a state of defense distributed, each after its manner, in the circulation—antitoxins, immunisins, and antibodies. The glandular elements, such as the thyroid, suprarenals, spleen, liver, testicles, and lymphatic nodes, as well as the nervous, muscular, and osseous tissues, are all in a state of organic hyperactivity. It is easy to conceive that the serum of such an animal will be rich in elements of defense of all sorts, and that, injected into an individual with an infective malady, no matter what the nature, will assist him to overcome the particular ailment. It cannot be doubted that a specific serum, such as that of diphtheria, will have more chance of success in a diphtheritic infection; but the same serum is sometimes found to be active against other infections, as by streptococci, staphylococci, meningococci, colon bacilli, etc.

Paraspecific serotherapy should therefore count in the future as an important means of general and prophylactic treatment, augmenting the means of defense of the organism in all infections, local or general. The easiest serum to procure, and the one most worthy of confidence, is the antidiphtheric serum of Roux-Behring, and it should be adopted until such time as deeper researches have furnished us with more precise indications with regard to the respective merits of the different serums.

Many experiments of a purely empirical nature have already been made in this sense. By means of antidiphtheritic serum there have been treated, not without some success, pneumonia, bronchopneumonia, a number of non-diphtheritic anginas, and different kinds of septic accidents.

At the same time this paraspecific serotherapy has not yet earned the right to a definite place in our therapeutic arsenal. And yet the practitioner may derive great benefit from it and sometimes surprising success, if he only recognizes the potent eutrophic, stimulant, and anti-infective properties possessed by the Roux-Behring serum, which under those circumstances acts as a kind of *opothérapie sérique de défense générale.* It goes without saying that paraspecific treatment should be reserved for infections, the specific sera of which have not yet been discovered.

The antidiphtheritic serum is the only specific serum that has been recognized in ocular therapeutics. The influence of this remedy is shown to advantage nowhere better than in the eye, where false membranes can be seen to melt away, almost like snow in the sun, when the infection is purely diphtheritic. In the cases of mixed infection, of course, the action of the serum is less sure and less rapid. It is necessary, then, to understand how to combine the action of different sera, or to assist them by local applications. It should be added that the direct bacteriolytic action of **pyocyanase** (a vaccin prepared from old cultures of the B. pyocyaneus) has been recently praised.

The Roux-Behring serum is a sovereign remedy in diphtheria of the conjunctiva, especially when the cornea alone is infiltrated without its epithelium being destroyed. When the cornea is already ulcerated, serotherapy, on the contrary, does not invariably succeed in arresting the ulcerative process, and perforation, followed by prolapse of the iris and escape of the crystalline lens, has often been observed, in spite of the administration of very large doses of the serum. Intervention has then been too late, or one has had to deal with malignant forms of exceptional virulence. *A fortiori*, there is little need for astonishment if serious ulcerations of the cornea sometimes fail to respond to paraspecific therapy.

The activity of a serum is estimated by antitoxic units—that is to say, one unit is capable of immunizing a guinea-

pig of 250 grms. against a dose one hundred times stronger than the lethal dose of diphtheria-toxin. According to Behring, the smallest therapeutic dose should be 500 units, the ordinary dose 2,000. In very serious cases 3,000 units are given at a time. In France, the Roux serum is delivered by the Pasteur Institute in flasks which contain 10 c.c., of which the total activity amounts to 1,500 to 2,000 units. That is the dose ordinarily employed in France for a first injection. These injections are repeated every day or every other day until the desired result is attained. Some authors praise much higher doses, given once or twice.

The injection is made into the lateral walls of the abdomen or in the vicinity of the kidneys. Such a minor operation is scarcely painful, and not at all dangerous. The only complications are erythema around the puncture, and in 3 per cent. to 4 per cent. of the cases erythemato-purpuric eruptions, with edema of the lower extremities, and pains in the joints. These symptoms pass away in the course of a few days, and their disappearance may be hastened by the administration of calcium chlorid or lactate.

An individual who has been treated by serum is from that moment sensibilized (**anaphylaxis**) as regards that particular serum, with the consequence that if another injection be made, even a year afterward, complications, much more alarming than those originally observed, are liable to appear. Before we give serum we must, therefore, find out if the patient is in a condition of anaphylaxis, or, in other words, whether he has already been treated with serum. The so-called **"serum-sickness"** is never observed after serum has been given by the mouth, but it is not yet certain whether this mode of administration is as efficacious as that by injection.

In nondiphtheritic infections of the eye the Roux serum is given as described—that is to say, 10 c.c. is injected beneath the skin of the flank for three consecutive days.

In cases of especial gravity, 1 c.c. of the serum may also be injected subconjunctivally on the first day.

If improvement is not marked after three or four injections, during the interval there is time to cultivate the microorganism present in the eye, for example, the staphylococcus; and under such circumstances paraspecific treatment may be replaced by active immunization by injecting a staphylococcic **vaccin,** *i. e.*, a sterilized culture of the staphylococci, in accordance with the principles indicated by Wright.

In ocular affections the great importance of the organ which is diseased forbids the practitioner to content himself with general specific or paraspecific treatment. Under no circumstances must he neglect local measures. It is better that he should cure his patient by employing several measures without knowing exactly which has been the curative agent than run any risk of the serum acting inadequately or too late.

Antipneumococcic Serum.—In the treatment of infective ulcers of the cornea Rœmer has used a serum that, in his hands, has already yielded most encouraging results. **Serpiginous ulcer of the cornea,** or infective hypopyon ulcer, is one of the most formidable affections of the eye. Thanks to the galvanocautery, subconjunctival injections, and Saemisch's section, many of these cases may be cured, although not without a more or less pronounced leukoma. Rœmer believes that, taken in time, the progress of such an ulcer may be immediately stopped by an injection of antipneumococcus serum, a method as free from pain as it is from danger.

According to the researches of Uhthoff and Axenfeld, it is believed that the pathogenic and specific agent of infective ulcer of the cornea is to be found in the pneumococcus of Fraenkel-Weichselbaum. This microorganism occurs sporadically not only in the conjunctival sac, but also in the pharynx and nasal fossæ, and it may become virulent after the smallest abrasion of the corneal epithe-

lium, more particularly if the lacrimal passages happen to be diseased.

Upon the specificity of the pneumococcus, Rœmer has based his therapeutics. It is already known (Fraenkel was the first to demonstrate the fact) that after a pneumococcal infection, an immunity, at all events of a more or less relative description, persists for a certain length of time. Antipneumococcus serum has already been prepared by Pane in Italy and by the brothers Klemperer, and many attempts to produce pneumococcic immunization have been made by its means. It was only after Rœmer's researches, however, that it became definitely established that pneumococcal immunity was the outcome of antibodies possessed of a specific bacteriolytic action. In this way the abrupt crisis of pneumonia is explained. But when an insignificant *foyer*, as an ulcer of the cornea, is concerned, the body fails to conquer it, because the development of the antibodies does not take place upon a large enough surface.

By means of a potent antipneumococcus serum, Rœmer has succeeded in proving that rabbits may be absolutely immunized against the pneumococcus. Even after the most virulent inoculations, he failed to produce in rabbits the least inflammatory reaction as regards the cornea. Ulcus serpens, however, cannot be produced very readily in the rabbit, but in monkeys who, like man, are subject to suppurations of the cornea, Rœmer managed to provoke a state altogether refractory to pneumococcal infection of the cornea.

Immunization or vaccination against the pneumococcus, however, would be of no practical utility, especially in so far as concerns the infective ulcer of the cornea. It is of much more consequence to know whether antipneumococcus serum is capable of putting an end to evolution of the corneal ulcer. That also has been demonstrated by Römer, at first on animals and then on man, preferably in young subjects, and especially when the disease was taken at the

beginning. That Rœmer's results have not been confirmed by all who have tried his serum, is easily understood when the extreme variability of the pneumococcus in respect of virulence is considered.

Technic. — Rœmer proceeds in the following way: Every ulcer of the cornea is from the first examined microscopically, and an estimation, as exact as possible, is made of the virulence of the microbe. From a purely prophylactic point of view, serum is injected, even before the pneumococcus has been identified bacteriologically. Up to the present Rœmer has injected daily into the flanks 10 c.c. of his serum. In order to obtain surer results, Rœmer recommends that passive and active immunization should be practised simultaneously—the former by the subcutaneous injection of 10 c.c. of serum, and the latter by injecting at the same time into muscular tissue a unit of sterilized culture of pneumococci, the effect of which is to provoke an active production of antibodies, which then join forces with those contained in the 10 c.c. of serum.

Results.—In the course of an interesting monograph dealing with the treatment by serum of infective diseases of the eye, Axenfeld has collected 185 cases of serpiginous ulcer treated with Rœmer's antipneumococcus serum. The series included seventy-four cases published by Rœmer himself and 111 others by various writers. Of the total number of cases brought together by Axenfeld, those of the first degree appear to have benefited more by the serum than others of more serious type and not treated so early. The last-named were seldom cured. Something of the same sort is observed as regards all the therapeutic measures employed against this formidable disease. At the same time, cases cured by serum alone, like those treated by subconjunctival injection, appear to present thinner leukomata than those treated only by the galvanocautery.

It may be said that in the presence of an infective ulcer of the cornea the practitioner should at once make

an injection of serum from the first day—that is to say, before the result of the bacteriologic examination is known. In most of the cases a notable improvement will be apparent from the beginning. But it often becomes necessary to apply local treatment simultaneously, in order to keep up the effect of the general treatment by serum.

It is unfortunate that Rœmer's serum is difficult to obtain. But clinical experience has proved that the same result can be obtained with antidiphtheritic serum, antitetanic serum, or even simple serum taken from an animal fed upon yeast (Deutschmann). This is what we have ventured to call "paraspecific serotherapy," which, despite the criticism that it lacks experimental control, will render great service to a practitioner who understands how to take the part of each therapeutic agent placed in action.

Antitetanic serum may possess special indications in ocular therapeutics. Several cases of fatal tetanus following wounds of the eyelids have been published. It is therefore indicated in the treatment of wounds suspected to be contaminated with earth to practise at once a series of injections of antitetanic serum of 10 or rather 20 c.c. every day. The effects of this treatment are not absolutely certain; but, since the method is quite free from danger, it is better to take so simple a precaution than to risk fatal termination to a wound of apparently trifling nature.

Deutschmann's serum is a new and universal curative serum. It is obtained in the following way: Animals are fed upon progressive doses of yeast, which determines an accumulation of protective or preservative substances in the blood. Serum obtained from animals fed in this way endows the human organism with increased resistance in the fight with pneumococci, staphylococci, streptococci, etc., or their toxins. Deutschmann's serum, like the Roux-Behring product, when injected into muscular tissue, improves the patient's general state, lowers febrile tempera-

ture, and provokes a salutary and non-dangerous crisis. As is the case with every serum, it sometimes gives rise to serum-sickness (*Serumkrankheit*), as shown by cutaneous eruptions.[1]

Neisser has recently shown that Deutschmann's serum, by augmenting phagocytosis, would stimulate the action of leukocytes against staphylococci. That interesting fact proves that the serum really possesses immunizing properties, although it is not invariably capable of curing a grave infection any more than other nonspecific sera. Serotherapy must be combined with such local measures as are likely to have a favorable effect.

Antistreptococcus Serum.—Great expectations, even in ocular therapeutics, were at first raised by Marmorek's serum. Thus Boucheron (*Société d'Ophtalmologie de Paris*, 1897) obtained good results in suppuration of the lacrimal sac without local treatment. The action of the serum was evident within thirty-six hours of the injection. Favorable results were also obtained in rheumatic affections of the eye, especially in cases of iritis. But results of this kind, it is necessary to note, have also been obtained by means of nonspecific sera.

Menzer (*Münch. med. Woch.*, 1904) reports favorably on the use of his antistreptococcus serum, in cases of acute and chronic rheumatism, superior, he claimed, to those of all other treatment, particularly when cardiac complications existed.[2]

Marmorek has found that streptococci, no matter of what strain, yield the same toxin which belongs to the group of diastases destroyed by a temperature of 70° C. Schaeffer (*Praktischer Arzt.*, 1907) has obtained remarkable results in the treatment of erysipelas from Menzer's antistreptococcus serum, when the injections are made early. The same product should have a good effect in puerperal infections. Polano (*Centralblatt für Gynecologie*, 1905) has

[1] How to avoid these complications may be learned by consulting *La Clinique Ophtalmologique*, 1908, No. 16.

[2] Collargol and metallic ferments produce analogous effects.

endeavored to combat streptococcal infections in gynecology by active prophylactic immunization. This he accomplishes by the injection of an attenuated culture of streptococci, obtained from the human body.

A method of this kind should satisfy three conditions: 1. It should be harmless; 2. its efficacy should have been demonstrated by experiments on animals; and 3. its clinical success should be vouched for. These points have been established by Polano with cultures furnished to him by Merck, of Darmstadt.

Rogman also has praised the prophylaxis of post-operative infections of the eye by the **simultaneous employment of several sera.** The practice is to be recommended, since it is more simple to watch attentively patients who have been operated on and at the least sign of infection to practise a liberal paraspecific treatment with the serum that is available, without, however, neglecting all the classic measures, such as the galvanocautery, subconjunctival injections, etc. Then, if the infective organism can be identified, we may endeavor to cope with it by a specific serum or vaccin.

Antistreptococcus serum may render valuable aid in cases of diphtheria complicated by a streptococcal infection.

Vaccins.—In addition to the various sera (passive immunization), there are extensively used vaccins (active immunization). The latter have enjoyed considerable popularity since the appearance of Wright's work on opsonins. When faced by an ocular infection, nothing is more natural than to try to obtain a pure culture of the infective organism in order to extract from it a vaccin, which is then injected so as to immunize actively the body against the baneful results already brought about by the said infection. The action of vaccins should be controlled by the systematic observation of the opsonic index (*see* Tuberculin). The objection to these active immunizations lies in the fact that if the therapeutic dose be

exceeded, an exacerbation of the infective phenomena may be provoked.

This method has been tried more particularly in England, whence Maddox and Mayou have, respectively, reported several encouraging results, obtained either by employing the staphylococcal vaccin supplied by the Jenner Institute of Preventive Medicine or else by preparing a vaccin, according to Wright's method, by means of a pure culture obtained from the patient himself. Zur Nedden has treated sympathetic ophthalmitis by the injection of blood-serum derived from a patient affected with that disease. The product, however, is extremely difficult to procure, and zur Nedden's results still await confirmation.

In the same class we may include the therapeutic subcutaneous injection of fluid obtained by lumbar puncture of patients suffering from cerebrospinal meningitis. Two patients are known to have been cured by this plan.

Conclusions.—Apart from the specific indications afforded by diphtheria, tetanus, and hydrophobia, all the sera enumerated, viz., Deutschmann's serum, antipneumococcus serum, antistreptococcus serum, and antistaphylococcus serum, have manifested no true specific action. All of them may be said to act more or less efficiently. But none of them has shown the least superiority from the therapeutic standpoint over what we have termed "paraspecific serotherapy." The last-named, even if its results have not yet been adequately explained by experiment, has now been tried so often that it may be fearlessly asserted that while awaiting the possession of chemical products which correspond with the intimate composition of antitoxin and antibodies, those which are accumulated in antidiphtheritic serum may suffice to endow the organism, invaded by any kind of infection, with a means o defense which is sometimes powerful enough to allow it to emerge from thé fray as a victor.

In infective **hypopyon keratitis,** when taken at the

outset, antidiphtheritic serum (about 2,000 Behring units) will bring about cure with the smallest possible leukoma, and will do it better than either antipneumococcus serum or Deutschmann's product. When the ulcer is more advanced, larger, deeper, or of greater virulence, then paraspecific treatment will bring about rapid disappearance of the pain and more or less marked arrest of the ulcerative process. But in order to effect complete cure, local measures, as the galvanocautery, paracentesis of the anterior chamber, and subconjunctival injection should be adopted. These act by stimulating the nutrition of the corneal stroma, by provoking a more marked afflux of antibodies from the ciliary circle into the aqueous humor, and, especially, by leading to a clarification of the infiltrated parts of the cornea.

Infected penetrated wounds of the cornea, ciliary region, or sclera, with manifest signs of iridocyclitis, even when associated with traumatic cataract, if taken at the beginning, yield in a remarkable way to the influence of three or four injections of 10 c.c. of serum (6,000 to 8,000 units of Behring).

Among the numerous cases of this kind personally treated during the last four years, not one failed to be benefited by serotherapy. It goes without saying that the local treatment of the infection by antiseptics and other applications is always valuable.

In the **infective complications of the operation for cataract,** happily so rare now, the results are so much the more favorable the sooner paraspecific treatment by serum is applied. More than thirty such cases have so far been reported, and of these, four only were not cured, on account of the gravity of the infection or the tardiness or the timidity of the practitioner. But all have been benefited in some measure by serotherapy.

Thanks to paraspecific therapy, it may now be claimed that most traumatic or postoperative infections may be promptly checked and cured provided they are treated early.

Oral Administration of Sera.—Less hesitation need be felt in having recourse to serotherapy, since it is known that the serum need not necessarily be administered by hypodermic injection. The following may be prescribed:

Antidiphtheritic serum..... 10 c.c. (2,000 units)
Sterilized water..... 110 grms.
A tablespoonful to be taken every hour or every alternate hour during the time the infection lasts.

In this way serotherapy may be applied at the slightest warning, as soon as one sees the wound become infiltrated, the iris change in color, or the aqueous become cloudy. Should the patient be in somewhat violent pain, there will be noticed relief at the end of four hours, and also a marked improvement in the state of the eye. The calmative effect upon pain is much more marked and rapid (half an hour) when the serum has been injected into a vein. Injected beneath the skin, serum acts somewhat more quickly than when given by the mouth, although the difference is not great. Nevertheless, the hypodermic method is to be preferred when one is not certain about the patient, who may not take the medicine or may use an inert product.

Administration by the mouth has the advantage in that it apparently does not provoke serum sickness. In suitable cases the subconjunctival injection of serum (1 c.c. or 200 units) assists the action of the serum remarkably, but the injection must not be repeated for fear of anaphylaxis.

The prophylactic employment of serum is not to be recommended. Even if a primary infection is thereby avoided, infection may be produced later or after a secondary operation, and under those circumstances anaphylaxis is to be apprehended or the organism may have become accustomed to the medication if serum has been given by the mouth.

All these considerations indicate that, in paraspecific treatment by serum, we have an ophthalmic conquest

that complements the work of Daviel, von Graefe, and Lister, although asepsis has prevented many infections, until now no means have been at our disposal to cure them in the majority of cases. Unhappily, there must always be some exceptions, as among old and debilitated subjects or in cases of excessive virulence.

Tuberculins.

The study of tuberculous affections of the eye is to-day of the greatest possible practical interest. The differential diagnosis is facilitated by the peculiar reactions undergone by an organism affected with bacillosis under the influence of Koch's tuberculin.

The cornea, iris, and uveal tract, including the choroid and even the retina, are often the seat of tuberculosis, but until recently exact diagnosis was almost impossible. It is only since inoculations of guinea-pigs, or well-made autopsies (**biopsies**), and especially reactions to tuberculin have demonstrated the tuberculous nature of the lesions, that treatment, based upon more exact diagnosis, has been able to advance with a more certain step.

After the enthusiasm excited by Koch's discovery, an equally exaggerated reaction occurred. But truth must always be sought between the two extremes, and it was in ophthalmology perhaps that tuberculin retained its prestige longest. Since 1890, numerous cases of iritis and keratitis have been treated and frequently cured by tuberculin, and the general and local reaction set up by tuberculin has often served as the basis of the diagnosis of ocular tuberculosis.

Experience has shown that tuberculosis of the iris, experimentally provoked in animals, may be checked by injections of tuberculin, although that observation has not gone unchallenged. In the course of a clinical and experimental work published in 1898, Zimmermann admitted that a specific antituberculous action was possessed by

tuberculins, a conclusion reached also by Doenitz in a remarkable work conducted under the direction of Koch himself.

Schieck studied the action of tuberculin T. R. in five cases of tuberculous iritis. Enslin obtained a typical febrile reaction in eight cases of interstitial keratitis, together with a local reaction in some instances, by the injection of 1/10 to 3 mgrms. In another series the same author elicited the tuberculin reaction in five among twenty-four cases of interstitial keratitis.

A good resumé of all published cases will be found in the excellent monograph of Gamble and Brown. There may now be said to be a general agreement with regard to the action of tuberculin, both as a means of treatment and also as a precious element in diagnosis.

Von Hippel has published twenty-four cases of tuberculosis of the iris or cornea mostly improved or cured by tuberculin. But the duration of the treatment was always very long. Three to six months, with fifty to seventy injections, are in general necessary, while relapses are not rare, although the last-named can usually be cured by a fresh series of injections. The results obtained by von Hippel have been confirmed by many authors, so that it may now be claimed that, thanks to tuberculin and guaiacol, many tuberculous affections of the eye may be cured, and that in the future eyes will be saved that formerly would have been sacrificed.

It is difficult to say if immunizations, active and passive, really act by producing a toxic immunity, or by increasing the cellular resistance, or, lastly, by acting directly upon the bacteria themselves by some specific substance. Wright gives a novel explanation. The theory, however, is in reality of little consequence. The important point is to remember that we can secure active immunization by injecting in the diseased subject weak doses of sterilized cultures of the causative microbe, thereby stimulating the resistance of the organism by phagocytosis, the production

of antitoxins, bacteriolysins, and so forth. It was by the empirical observation of active immunization that Jenner endowed us with vaccination. The facts have been established scientifically by the works of Pasteur, Behring, Roux, and others. Lastly, by means of passive immunization we can directly administer to the patient considerable quantities of antitoxins and antibodies, capable of neutralizing the effects of the infective malady, and for that it suffices to inject the patients with serum from animals actively immunized.

Roemer does not hesitate to combine the effects of active immunization by injecting a sterile culture of pneumococci, with those of passive immunization by the daily injection of antipneumococcus serum. To his mind, it is definitely established that pneumococcal immunity is provoked by antibodies which possess a specific bactericidal action. In this way he explains the crisis observed in pneumonia when the antibodies become abundant enough to lead to the death and disappearance of the infective elements.

As regards tuberculosis, the experiments on immunization, both active and passive, are not quite conclusive, despite the numerous works published on the subject.

The interesting discoveries of Metschnikoff upon the rôle played by the phagocytes in the fight between the organism and infective agents have provoked numerous contradictory researches.

The Opsonic Theory.—If one adds an immunizing serum to a mixture of leukocytes and bacteria, phagocytosis becomes more energetic, and as many as twenty microorganisms may be counted in each leukocyte, whereas if normal serum has alone been added to the mixture, phagocytosis will be much less and the leukocytes will be found to have englobed but a few organisms.

According to Wright, this result produced by immunizing serum is due to the particular action of a substance which he has called **"opsonin"** (from *opsona*—I prepare

the ways), and which renders the microbes more attractive to the leukocytes. The quantity of opsonin contained by the blood of an individual should give us the measure of its resistance to this or that bacterium; this quantity depends upon the reaction of the organism to the stimulus provoked by the bacteria. In the case of local infection, the quantity of opsonin is below normal, and that is just the reason why the infective elements have been allowed to become fixed in the tissues, and remaining thus localized they fail to excite antibodies enough to destroy them. But if at this moment a small quantity is injected of a sterilized culture of the causal microorganism, the amount of opsonin is promptly augmented and the general reaction of the body finally reaches a point when discovery becomes possible.

The amount of opsonin contained in the blood of an individual is the measure of his resistance against the bacteria in question. The **opsonic index** may be determined by calculating microscopically the number of bacteria absorbed by a single leukocyte: *a*. in the presence of normal blood-plasma; *b*. in the presence of the plasma of the patient. The quotient obtained by dividing *b* by *a* gives a fraction which represents the opsonic index. The careful observation of the opsonic index has enabled Wright to institute a treatment of tuberculosis which appears to be full of promise.

The opsonic theory would explain very well the action of tuberculins. Trials of immunization with tubercle bacilli have been made, but they had to be abandoned, as the bacillus remained intact in the tissues without undergoing resorption, and merely provoked the production of local abscesses. These bacilli possess a fatty envelope, which explains their resistance to chemical reagents, as well as their difficult resorption. Koch succeeded in rupturing this envelope by purely mechanical means, without any chemical agent, and without any great elevation of temperature. He managed to divide them and to pul-

verize them to such a point that in the fine powder thus obtained no bacilli could be found with the microscope.

When this bacillary powder is dissolved in water and centrifuged, a liquid of yellowish color and a white precipitate are obtained. The latter is dried, triturated again, dissolved in water, and centrifuged. By repeating this operation several times, one succeeds in reducing the bacilli into a series of slightly opalescent solutions. The first of these solutions contains the soluble toxic substances of the bacilli, and was called by Koch tuberculin O or T. O. The other liquids contain only insoluble matters in a state of fine suspension—the so-called new tuberculin or T. R., of which 1 c.c. includes 10 mgrms. of solid substance.[1]

Method of Employing Tuberculin T. R.—In general, treatment is commenced by very small doses of tuberculin (1/500 mgrm. of the solid substance), and if reaction be produced, the dose is diminished still further.

Tuberculin T. R. is furnished by Messrs. Meister, Lucius, and Bruning, of Hoechst, near Frankfort. The Pasteur Institute of Paris also supplies a tuberculin in **ampoules** which contain the same quantity (10 mgrms.) as the flasks of tuberculin T. R. Each flask of 1 c.c., therefore, contains 10 mgrms. of active substance. In order to make a first injection of 1/500 of a mgrm., this solution must be diluted 5,000 times. This is done in the following way: Three divisions of a pipet of 1 c.c., divided into ten equal parts, are filled with the original T. R. solution. To this is added twenty-seven divisions of a sterilized 20 per cent. solution of glycerin. In this manner there is obtained a dilution of three-thirtieth, that is one-tenth or 10 per cent., of which 1 c.c. contains 1 mgrm. of the active substance. Of this solution there is taken 1/10 c.c. and added to it enough glycerin solution to make an exact total of 10 c.c. In this way a solution is obtained, of which 1 c.c. contains 1/100 of a mgrm. of T. R. By injecting

[1] For purposes of preservation, 20 per cent. of glycerin is added to the above liquids.

one-fifth of a Pravaz syringe of 1 c.c. one employs 1/500 of a mgrm. of T. R.

This feeble dilution keeps for at least fifteen days without alteration, provided it is stored in the cold and away from light. It must not be used after it becomes cloudy or flakes form in it. It need scarcely be said that all pipets and bottles employed in making the dilutions must be carefully sterilized. Injections, which are only slightly painful, may be made in any part of the body —between the shoulders, in the buttocks, or even around the orbit. Since the febrile reaction often does not manifest itself until the second day, it is advisable to make the injections only every second or third day.

Before treatment with tuberculin is commenced, the temperature must be studied for several days, and an injection must never be made if there be the least trace (38° C.) of fever. The temperature should be taken four times a day, and as soon as the least rise (0.05) is observed the injections must be discontinued until the temperature has fallen to normal. When massive doses of 5 mgrms. of the active substance have been reached, injections should be made only once a week, but it is rare that doses as high as these are necessary.

The question of the local injections of tuberculin is a very delicate one. They are capable of giving interesting results. The violent reaction set up by the injection may have a salutary effect by provoking an abundant vascularization of the sclerosed cornea, followed by a partial clearing and appreciable sight. Under any circumstances, the **subconjunctival injection of tuberculin** should not be undertaken except with great prudence and in very feeble doses (1/10,000 of a mgrm. at the most), and especially after the ground has been prepared by a long series of hypodermic injections. Indeed, before making the injection beneath the conjunctiva, it is advisable to practise it around the orbit under the skin of the temple or eyebrow.

The following **important clinical observation,** should it be confirmed by a series of similar cases, would have a very considerable therapeutic significance. In three patients treated by tuberculin we have been able to check the local symptoms of irritation set up by tuberculin by practising one or at the most two injections under the conjunctiva of 1 c.c. of a watery solution of **guaiacol,** 1 : 100.[1] It has been known for long that guaiacol is almost a specific in tuberculosis, so that this local application is at once a proof of the antituberculous properties of guaiacol and a kind of counter-proof to the reaction set up by tuberculin. In a case of ocular hypertonus, the violent pain provoked by tuberculin disappeared rapidly under the influence of a single subconjunctival injection of guaiacol.

May it not be concluded from these facts that guaiacol, administered conformably to a well-studied determinism, is capable by itself of curing tuberculosis of the eye? Under any circumstances, tuberculin will always be valuable as a means of diagnosis, and we can now employ it with the more assurance since we have in guaiacol a means of checking any congestive complication produced in infective foci by its administration.

Oral Administration.—The encouraging results obtained by antidiphtheritic serum administered by the mouth allow one to hope that tuberculin may also be given in that way. Interesting observations have already been published by several English authors with regard to this point.

It is possible that ocular tuberculosis might be successfully treated by the **instillation into the conjunctival sac** of progressive and ascending doses of tuberculin, commencing with a 1 : 500 solution, and as soon as a reaction has been provoked, it might be checked by the instillation or the subconjunctival injection of guaiacol.

[1] Solution to be made by heat. On cooling, it remains clear and the guaiacol is well dissolved.

Oxydases, Metallic Ferments, and Colloidal Metals.

All the interesting clinical results obtained by specific or paraspecific serotherapy should certainly be controlled by experiments upon animals. But while awaiting therapeutic experiments, it can already be seen that the effects produced by serotherapy will very probably be shortly explained by physicochemical actions brought about in the organism under the influence of certain biochemical agencies, analysis of which is probably not far distant.

Oxydases of animal or vegetable origin have an action somewhat analogous to that of the serums. It has been proved by Sieber that the oxydases neutralize the toxins of tetanus and diphtheria not only *in vitro* but also in the body of the animal.

The staphylase praised by Doyen is the active diastase of the ferments or yeasts of beer or of wine. He recommends its use by hypodermic injection and by the mouth. The antipurulent powers of staphylase become very evident in the treatment of chronic dacryocystitis.

The colloidal metals of silver, platinum, palladium, etc., on account of their oxydo-reducing action on the elements of the organism, have received the name of "metallic ferments." The nature of the metal appears to be indifferent—that which is essential is the physical state of division of the metal. This accounts for the fact that Bardet (*Bulletin général de Thérapeutique*, 1907) found that colloidal silver obtained by Bredig's process—that is to say, by the aid of an electric current—was much more active than collargol obtained by chemical means. In every instance these metallic ferments show a therapeutic action which has a great analogy with that obtained by treatment with paraspecific serum.

As regards the organism, incompletely oxidized products become toxic, and in order to render them harmless, it suffices to burn them in a more complete manner. It

is known, however, that microbic toxins are attenuated or even destroyed by oxidation. The following conclusions are warranted by Sieber's experiments relative to the action of **oxydases** upon toxins: 1. Oxydases of animal or vegetable origin neutralize the toxins of tetanus and of diphtheria, but are without action upon abrin. 2. The destructive action of oxydases upon toxins is manifested not only *in vitro* but also in the animal body.

A. Robin and Bardet then thought that artificial oxydases would favor the oxydo-reducing hydrations of the human body, and thereby check the phenomena of infection or of morbid intoxication. They studied the action of the diastases by comparing their effect with the action of colloidal solutions, vegetable oxydases, and of certain therapeutic sera. All of these products visibly and intensely augmented the exchanges and brought them to perfect oxidation, as much from the point of view of respiratory chemistry as from that of urinary chemistry. The increase in the amount of urea and of uric acid is sometimes enormous in grave infective conditions, thus provoking the salutary crisis which ends infective maladies at the moment when they tend toward cure.

Robin and Bardet also investigated antidiphtheritic serum and simple horse's serum as means of oxidation. Of the two, the action of the antidiphtheritic serum was always the more marked, but was invariably identical with that obtained by the colloidal metals. One may hope, therefore, that many of the more profound maladies of nutrition, the cause of which is still unknown, may be benefited by the methodical employment of the metallic ferments or of bodies which contain them.

According to Credé, Netter has already experienced the happy results that may be obtained by the employment of collargol, which acts rather as a diastase than by the antiseptic virtues of its contained silver. It will be apparent later, while studying the salts of silver, how important collargol is to the ophthalmologist as much in its local

applications (de Lapersonne, Meyer, Godts) as in its general applications by inunction (Trousseau, Leloutre, Beauduoin). When studying the treatment of iritis we shall also have occasion to see the persistent antiseptic action possessed by silver in the colloidal state (Darier).

The specific action hitherto attributed to mercurial inunctions is probably of the same order as that of collargol. Under any circumstances, serotherapy and treatment by oxidizing agents should be studied with as much care by ophthalmologists as by other practitioners.

Apart from true serotherapy, there are other therapeutic measures which aim at strengthening the defensive powers of the body, mostly by favoring phagocytosis.

Most substances, as aleurone, peptonized bouillon, nucleinic acid and the nucleinates, physiological salt solution, and the different normal sera, attract polynuclear leukocytes by chemotaxis, and increase their number, and are able consequently to help us in dealing with infections. Among the substances capable of drawing polynuclear leukocytes to a given point and of increasing their number, one of the most active is **warmed horse's serum.** Its employment as a local remedy is very simple, and it has the advantage of exciting no inflammatory reaction and of causing no pain, as do nucleinic acid and the nucleinates. Lastly, it is nontoxic, as is nuclein and its derivatives; indeed, it is actually less poisonous than ox-serum.

Leukocytosis may be obtained by isotonic saline solution, but in order to get a less accentuated effect, a larger quantity of the liquid must be employed. Warmed horse's serum will be found to be more efficacious in cases of grave infection, to help in the elimination of mortified tissues following burns, contused wounds, gangrene, etc., at least during the first dressings. Treatment by the non-immunized horse's serum exposes the patient to serum sickness if the product be given subcutaneously. If administered by the mouth, this is not the case, but, on the other hand, it then appears to be ten times less active than

paraspecific therotherapy (Paton). Nevertheless, it may render service, like an artificial serum the use of which has been praised in the treatment of toxic amblyopia, etc.

In speaking of a work by Weill on hemophilia, Broca remarked that normal serum injected into the veins of a person affected with **hemophilia** modified for about a month the morbid phenomena of that disease. Antidiphtheritic serum has the same properties. It is possible, therefore, that serotherapy may render service in **hemorrhagic affections of the eye,** such as hemorrhagic glaucoma, relapsing vitreous hemorrhages, etc., and may facilitate operations upon patients suffering from hemophilia, leukemia, etc. Serum applied to the bleeding wound would arrest hemorrhage better than any known hemostatic.

Bacteriolytic Agents.

Apart from antitoxic serum, which combats the effects of infection, there are also agents which possess a distinctive and direct action upon the microorganisms. For example, **pyocyanase** is a cytase which has the power of destroying and of rapidly digesting a multitude of bacteria, and that not only *in vitro* but also in the organism itself if it be injected hypodermically. It is prepared from three-weeks-old cultures of the B. pyocyaneus, by filtration, and then by evaporation at 25° C. *in vacuo*. It is a bacteriolytic ferment which does not lose its activity even when heated to a temperature of 100° C. Its activity has been tested in the treatment of diphtheria, by vaporizing it over the membranes three times a day. All the cases treated in this way recovered, although one need not on that account abandon serotherapy, to which pyocyanase may become a powerful local auxiliary. By means of pyocyanase, one may in the course of two or three days free the conjunctival and the lacrimal sac from staphylococci, streptococci, and pneumococci. The same remark applies to the gonococcus, but only during the first few

days of the infection, before it has invaded the depths of the tissues. Pyocyanase should be the best prophylactic and abortive of the gonococcal infection.

Bile is another agent that should have powerful bacteriolytic properties. Rabbit's bile should dissolve pneumococci promptly. Gabriélidès and Morax have applied this fact in the treatment of pneumococcal ulcerations of the cornea. Although a very painful agent to apply, bile may prove itself to be a valuable local remedy.

Some chemical agents, such as **antiformin and thalianin,** also possess bacteriolytic properties.

Hemolytic Serum.

Hemolysis is well known nowadays. If an animal be injected with blood from another species of animal, a substance known as **hemolysin** is formed in the organism, and this substance has the power of dissolving the red blood-corpuscles of the animal from which the blood was taken. The more frequent the injections of the foreign blood, the more abundant becomes the production of the hemolysin.

Roemer has suggested that by collecting the blood of such an animal it might be possible to prepare from it a hemolytic serum capable of hastening the resorption of intraocular hemorrhagic exudations. By injecting such a serum into the vitreous body of a patient affected with vitreous hemorrhage, a certain result was obtained. Under similar conditions Enslin, however, observed serious complications. In a personal experience we did not obtain an encouraging result when the serum was injected subconjunctivally in a case of hemorrhage into the retina and vitreous.

Filatow has injected normal serum into the vitreous humor and anterior chamber of dogs, rabbits, and other animals. The eye of the dog remained indifferent to the injection of serum derived from the rabbit and dog; the

eye of the rabbit supported equally well serum from the rabbit and guinea-pig; serum from the dog, the wolf, and the tortoise provoked in the rabbit a local reaction, which manifested itself by iridocyclitis and vitreous opacities, lasting from thirty to fifty days. As complications were observed retinitis, retinal detachment, and cataract. In a second series of experiments Filatow injected hemolytic serum into the vitreous humor of the dog and of the rabbit, and found that, even in small doses, iridocyclitis and fibrinous exudations resulted. Consequently, he advises against the employment of injections of hemolytic serum as recommended by Roemer in the treatment of vitreous hemorrhages.

General Remarks Upon Serotherapy.

Specific serotherapy is a desideratum in all infections, the diagnosis of which can be speedily and strictly made. But when an organ so delicate and precious as the eye is concerned, one must often act before the necessary bacteriologic investigations can be completed. Under such circumstances the practitioner should not hesitate to have recourse to paraspecific serotherapy, using for the purpose the serum that it is easiest for him to procure, without prejudice to the particular information that may be furnished to him later by the bacteriologic examination.

When matters are urgent, the serum may be administered by endovenous injection or by injection beneath the skin, which is the classic means and the most popular up to this time. For several years Chantemesse has praised rectal administration, and he has been followed by J. Porter Parkinson, W. S. Fenwick, and others. Lastly, Paton, Darier, Horth, and Latham have maintained that administration by the mouth is the simplest and most practical method.

Hypodermic or endovenous injection is certainly the surest and most rapid means, as well as the most scientific,

but if it should be definitely established that the digestive tract allows of the absorption of antitoxins or antibodies and at the same time destroys the substances that produce serum sickness, sometimes so disagreeable a complication, then this should lead on the one hand to vulgarization of the method and paraspecific serotherapy, on the other to the treatment of many infections, against which one now hesitates to practise the hypodermic injection of serum.

Roemer's Jequiritol Serum.

By making graduated solutions of **abrin** in glycerin, Roemer has devised a more scientific way of applying the old Brazilian treatment of granulations by jequirity, recommended several years ago by de Wecker, and given up by many on account of the dangers it presents when applied by inexperienced hands. To begin with, Roemer convinced himself that by the repeated instillations of weak solutions of abrin one could obtain a local, and then a general, immunization, so that a dose which gave rise to a first reactional inflammation failed to produce the same effect when applied a second time. It was necessary to employ considerably stronger doses to elicit a fresh reaction of equal intensity. After many experiments, he found an initial medium dose capable of producing in man a reaction sufficient to provoke a vascularization of the cornea and of the leukomatous or pannous parts. Since individual reactions varied infinitely, it was necessary that the initial doses should be very weak. Roemer understood this perfectly well, but he went farther in foreseeing cases in which too violent a reaction was likely to be produced, and in recognizing the necessity of cutting short such an excessive reaction. Thanks to an antitoxic serum obtained from animals rendered refractory to abrin, the so-called "jequiritol serum," one is now in a position to check in a few hours, by simple instillations, the most severe inflammation produced by jequirity or abrin.

For the future it is therefore justifiable to provoke such conjunctival or corneal reaction as may be necessary, without fearing the complications to which the eye was once exposed by the use of unduly strong doses of jequirity. It goes without saying, however, that a certain apprenticeship must be served by every beginner, since the experience of others counts for little as regards the use of jequiritol.

The fundamental basis of **Ehrlich's side-chain theory** rests on the proposition that living protoplasm, according to the nature and physiological importance of each cell, possesses receptors which vary in number and in kind. These have a maximal chemical affinity toward certain specific groups of nutritive elements, which after having been utilized by the living cell, may be reconstituted. A preliminary dose of tetano-toxin, capable of impressing without destroying the cerebral cells, provokes the production of antitoxins, which immunize in part by consecutive inoculations. Too feeble doses of jequiritol likewise postpone the jequirity reaction; the antitoxin is produced by the affected cells. It is the special merit of antitoxins that they serve, in a measurable degree, to subtract and to eliminate specific toxins from organs or poisoned cells. It is in this way that they cure.

Jequiritol may be profitably employed in the treatment of pannus of the cornea, whether scrofulous or trachomatous in origin.

Organotherapy.

Adrenalin.—Suprarenal capsule extract, now replaced by a synthetic chemical product known as "adrenalin," has demonstrated the importance of opotherapy in eye work. In cases of serious bleeding, which nothing would arrest, good results have been obtained by the intravenous injection of 8 per cent. saline, with the addition of 10 drops of adrenalin (1:1,000) to each liter of the solution (Latzko).

Thyroid-treatment has some importance in different affections of the eye, more particularly in exophthalmic goiter. If it be conceded that Basedow's disease is caused or aggravated by an excessive action of the thyroid gland, it is natural to suppose that an antithyroid serum would have an inhibitory action upon the phenomena of hyperthyroidism. Moebius obtained his **"antithyroidin"** by collecting the serum of animals (rams) from which the thyroid glands had been removed. Good results have been obtained by many authors by the administration of 10 to 30 drops of the product thrice a day.

Diabetes sometimes presents several of the symptoms peculiar to Basedow's disease—nervous excitement, profuse sweats, etc. By means of antithyroidin Lorand (*Therapie der Gegenwart*, 1907) has succeeded in improving all these symptoms, as well as the glycosuria. Even when given as a single dose of 5 drops, antithyroidin possesses hypnotic powers. It considerably augments leukocytosis and the opsonic index. On the contrary, in animals with thyroid insufficiency, the opsonic index is much reduced (Fassin-Marbé).

The thyroid gland should possess marked influence upon the functions of the **pituitary body.** In some cases of optic atrophy due to compression of the chiasma by the hypertrophied pituitary, powdered thyroid gland has been given with the idea of reestablishing the normal functions of the pineal gland. In **parenchymatous keratitis** in scrofulous subjects powdered thyroid has also been given with success.

Retinal hemorrhages have been observed by Best in animals from which the thyroid gland has been removed, and this has given him the idea of prescribing thyroid in cases of intraocular hemorrhage. Angelucci has adopted this treatment, with a measure of success, in several instances of ocular hemorrhage. Lévy and Rothschild believe that certain forms of **rheumatism** are due to insufficiency of the thyroid gland, while Diamantberger has

used thyroid in doses of 0.25 to 2–3 grms. with success in chronic rheumatism.

Lamb's liver has been recommended by Trantas (*La Clinique Ophtalmologique*, 1879) in a daily dose of 200 grms. in hemeralopia (Sicherer, Fabry). In slight cases, especially when associated with epithelial xerosis, cod-liver oil appears to act in the same way (Stephenson).

Extract of the uveal tract has been tried, but without striking result, in the treatment of retinitis pigmentosa (Darier, 1895). In 1898 Dor praised the action of a liquid **extract of ciliary body** used as a subconjunctival injection against sympathetic ophthalmitis. R. W. Doyne (1903) recommended **"optocine,"** *i. e.*, an **extract of retina,** in a number of diseases of the retina.

Lagrange (*La Clinique ophtalmologique*, 1898) gave internally a glycerin extract of the ciliary and vitreous bodies in affections of the vitreous humor and detachment of the retina. The same extract has been administered in asthenopia and ocular fatigue. But these experiences appear to have fallen into oblivion.

In the treatment of detached retina Deutschmann has for several years injected into the affected eyes the **vitreous body of rabbits,** triturated with saline solution (one of the former to one-half of the latter). The reaction liable to be set up by the injection is combated by atropin and mercury. The operation may have to be repeated on several occasions. Deutschmann appears to have had favorable results in truly desperate cases.

Koenigshoeffer, and, after him, Roemer, have tried to resolve immature cataract by means of the **pulverized crystalline lenses** of young animals. This interesting study is still being carried on.

Spermin and testicular extract have still their advocates in the treatment of optic atrophy and exophthalmic goiter. Dor, junior, has cured by this means five cases of ocular asthenopia in children who had outgrown their strength. **Bone-marrow** and **spleen-pulp** have been successful in the

treatment of grave anemia. Almost identical results have been obtained by **raw meat,** which should have a good effect in hemophilia, where it may replace the serum praised by Weill as favoring coagulation of the blood (Gubb). Calcium chlorid, gelatin (2 grms. a day), and arsenic alternating with iron, should form, as it were, the happy complement in the treatment of the hemorrhagic diathesis.

CHAPTER VI.

DIAPHORETICS, REVULSIVES, PURGATIVES, HEAT AND COLD, ETC.

Diaphoresis.

Diaphoretics in many different forms have always been employed in ophthalmology whenever it was wished to hasten the resorption of pathologic exudations in iritis, long-standing iridochoroiditis, vitreous opacities, and in affections of the retina and choroid, especially when these affections were of rheumatic, gouty, syphilitic, or scrofulous origin.

Vapor baths and dry heat baths, taken two or three times a week, are of classical efficiency, although they may advantageously be replaced by light baths. The naked patient is placed upon a seat, beneath which is a lighted alcohol lamp, and completely covered with a heavy woolen coverlet. The patient remains for half an hour in the bath. When he perspires freely, he is put to bed, where he is massaged and rubbed with warm cloths, and the process may be aided by giving at the same time warm drinks which contain a little sodium salicylate or potassium iodid.

This is a very practical method of treatment, since it can be followed without the patient being forced to leave his own house. As the effect of the baths is energetic and sometimes very weakening, they should be taken not oftener than twice or thrice a week. In the interval, tonics, in addition to the general treatment indicated by the nature of the disease, may be administered. Among cardiacs or old people, the bath should, to begin with, last a very short time, or it may even be replaced by **warm packs** (moist or dry), with diaphoretic beverages.

Pilocarpin Sweats.—Since the discovery of the extraordinary properties of pilocarpin, most of the other methods of inducing diaphoresis have become less important. The injection beneath the skin of 0.01 to 0.02 gr. of pilocarpin hydrochlorid will produce salivation and profuse perspiration, the effect of which is very valuable in a number of ocular affections. This is likely the best method of treating toxic amblyopia, and at the same time it gives an interesting point in diagnosis, as for some minutes after the injection the patient often experiences an improvement in his sight. The improvement becomes more marked if a little strychnin be added to the solution, which has the further advantage of allowing treatment to be kept up longer:

Pilocarpin hydrochlorid	2
Strychnin sulphate	0.5
Water	100

One-half to 1 c.c. for injection, *i. e.*, 0.01 to 0.02 of pilocarpin and 0.0025 to 0.005 of strychnin.

By this means an injection may be made every other day. The first should be of 1/2 c.c. The maximum effect once obtained, the dose should not be increased, since there exists no such thing as tolerance toward pilocarpin. On the contrary, the sudoriparous and salivary glands become more and more excitable, so that doses must be diminished or the intervals between them lengthened. Strong doses are apt to provoke nausea, which does more harm than good.

In general, a course should consist of about a dozen injections in the course of a month or six weeks. The patient is then treated, according to the particular indications, with potassium iodid, sodium salicylate, etc.

Revulsives and derivatives have always enjoyed the popular favor. Common household ophthalmic measures are mustard foot-baths and the application of blisters to the temple or to the back of the ear. A seton has

rendered service in optic neuritis. Rubbing the temple or the forehead with eau de Cologne or other evaporating or cooling solutions is useful in pain about the eyes; but one must understand how to vary these several applications.

Unquestionably, the most energetic derivation is the local depletion of the blood, such as can be obtained by the application of **leeches** or cupping-glasses in the neighborhood of the eye. The importance of these measures has been denied by many writers, because they failed to understand the theory on which their action could be explained. Long years of practice, however, have convinced us that in acute iritis or iridocyclitis, when the congestion is so intense that atropin remains without effect, rapid relief can be obtained and the pupil be markedly dilated by the application of three to six leeches to the temple, according to the age and vitality of the patient. In myopic chorioretinitis, in hemorrhages into the anterior chamber, the vitreous body, or the retina, a couple of leeches applied every five days to the mastoid will promote resorption of the blood and sometimes effect a marked improvement in vision.

Wet cupping has an analogous effect and may usefully replace leeches, the application of which is repugnant to many patients. Before applying leeches or cups, the skin of the part should be well washed. Bleeding should be allowed to continue for as long as possible and in many cases encouraged by hot fomentations, as compression with wool steeped in stypticin or antipyrin will always suffice to check excessive bleeding. The use of perchlorid of iron is not necessary.

Purgatives and laxatives are of undoubted use in many affections of the eye. It is well known that constipation and the resulting coprostasis are common causes of the most various kinds of intoxication. Anemic conditions, often of very serious nature, may result from intestinal intoxications. Recurrent hemorrhages into the vitreous

body of young subjects may have no other cause than constipation.

Constipation should be met at first by such hygienic measures as cold douches, massage, and vegetarian diet. Purgatives should be given only as the last resort. At the same time **purgation** is useful at the beginning of almost all acute affections of the iris and ciliary body, when it acts by intestinal derivation. In such cases **calomel** should be given, since it acts not only as a purgative but also as a stimulant of the hepatic functions. In order to avoid the accidents sometimes provoked by calomel, when it is not promptly evacuated, it is well to prescribe scammony with it as follows:

Calomel }
Scammony } equal amounts.

Three-tenths to 0.75, according to age, of each of the above medicaments to be administered in a cachet. One cachet to be taken two days following, if the effect is not too energetic the first day.

Purgation is often indicated in patients who have been wounded or operated, and in such cases calomel, as in the formula above, or castor oil, may be administered. It is important to attend to the condition of the bowels in children affected with chronic conjunctivitis, keratitis, or blepharitis, and in these cases it is not a bad plan to give a mild purgative every ten days. The same remark applies to the ocular congestions so common among arthritics and rheumatics. Neuralgia and headache due to errors of refraction are often exaggerated by constipation; especially is this true in women.

Diuretics, like diaphoretics and purgatives, are useful in affections connected with the uric acid diathesis. **Milk diet** is the primal diuretic measure and we should always attempt to enjoin it in albuminuric and gouty patients.

Among the most popular diuretics may be mentioned potassium nitrate (2 grms.), sodium bicarbonate (1 to 5

grms.), and piperazin, and the numerous medicinal drinks, such as dog's grass, cherry, etc.

Amblyopia due to tobacco and alcohol is often improved by diuretics used in alternation with the other treatment. The best diuretic effect can be obtained by waters containing but little mineral matter.

Antipyretics, under which head we include quinin, have many indications in ophthalmic practice, although they are prescribed more frequently to relieve neuralgia than to reduce temperature. Quinin, in doses of from 0.50 to 1 grm., is given in neuralgia of the trigeminus and in the keratalgia of iritis. But it must not be forgotten that such doses cannot be tolerated by every patient. The drug should be administered cautiously and the dose must not be increased if ringing in the ears occurs, as it is likely to do under such circumstances. Antipyrin (2 to 5 grms. a day) is an analgesic, the effect of which rapidly passes off, although the remedy frequently causes skin eruptions. Pyramidon has a more constant effect when given in a dose of 0.50 to 1 grm. daily. Phenacetin is given in doses of 0.50 grm. in cachet form.

Narcotics are useful, especially after operation, for the purpose of ensuring placidity and producing sleep. They are serviceable also in all painful affections of the eye, but the system speedily becomes accustomed to these medicaments. Extracts of opium (0.02 to 0.05) and Dover's powder (0.25 to 0.50) are the narcotics most commonly employed, but to relieve ocular pain hypodermic injections of morphin (0.005 to 0.02) or dionin (0.03 to 0.05) are preferable. Sulphonal (0.50 to 2.0) and chloral (2 to 6 grms. a day) are excellent soporifics. In obstinate headache aconitin (0.002 to 0.005) has often a powerful antineuralgic action.

The antispasmodics are headed by potassium bromid, which is much used in ophthalmic practice which includes the treatment of so many nervous patients. It is administered in doses of 0.05 to 2 grms. daily. The valerianate

of zinc and of ammonia, validol, and bromidia are excellent antinervotics.

Stimulants.—Strychnin is the chief stimulant. It renders the greatest service in amblyopia and atrophy of the optic nerve in the early stages, administered in doses of from 0.002 to 0.01, given hypodermically into the temple every third day. A good formula for such cases is the following:

Arsenous acid	0.001
Strychnin arsenate	0.001
Zinc phosphate	0.005
Iron sulphate	0.03
Extract of gentian	q. s.

Two to five of these pills to be taken daily.

Physical Agents.

Modern therapeutics tends more and more to profit from the study of physical agents. Many of these have been employed in former times and given up because their action was not fully understood.

Scientific researches have furnished us with the theoretical explanations of the action of Finsen's phototherapy, of radiotherapy, of Bier's hyperemia by stasis, etc. On the other hand, some of the simplest methods of treatment, such as heat and cold, which have always been employed by the practitioner, have been studied experimentally very little, and the manner in which they act upon inflammatory processes is not yet explained scientifically and no precise relative information can be found in the text-books.

The exact indications and contraindications of heat and cold in ophthalmic practice are still under discussion. Clinical experience is conclusive, but its interpretation is so delicate and its exact determinism so difficult that laboratory experiments are often necessary. It is very difficult to find a means of provoking experimentally an inflammatory process which could be graded exactly.

Schaeffer (Stuttgart, 1908) has adopted the following method. Catgut or silk threads are immersed in a bouillon culture for a determinate number of minutes. By means of a needle, two equal lengths of the impregnated thread are implanted into the subcutaneous cellular tissue of the same animal, care being taken to place them on exactly symmetrical points. The spots of entry and exit of the threads are sealed with collodion. In this manner an almost identical inflammatory process can be excited on the two sides, as Schaeffer has found by repeated biopsies. Under such circumstances it becomes a comparatively simple affair to treat one side by warm applications, such as poultices, compresses, thermophores, and hot air, and thereby to settle a number of questions of vital importance to the practitioner. All the experiments cannot be described in this place, although a résumé of them may be attempted, the reader being referred to Schaeffer's monograph for details and for reproductions of the microscopic specimens.

Heat.—It must be recognized that heat is the most certain means of provoking active hyperemia, and the idea that inflammation and suppuration are favored by it is very common. Experience proves that this view is altogether false. There is momentary augmentation of the swelling by hyperemia and active edema, but this is a salutary reaction which tends to bring about resorption of the morbid elements. If suppuration is already too far advanced, the hyperemia set up by hot applications will hasten resolution, but on this occasion by suppuration.

Schaeffer's experiments with heat have yielded such constant results that we may infer they would be the same in man, allowing for natural individual differences: thus, the skin of man is able to bear dry heat at a higher temperature than that of the rabbit.

Heat provokes an active hyperemia, with an acceleration of the blood current, even in the depths of the tissue. This hyperemia does not cease with the appli-

cation of the heat, but may persist long after (twenty-four hours or longer). A period of passive hyperemia succeeds the active hyperemia. If the heat be unduly high (above 43° C. for poultices and 48° C. for dry heat) the superficial vessels show alterations accompanied by small hemorrhages.

The lymphatic circulation, also, is accelerated in a constant way, producing an active edema. Here, too, a certain temperature must not be exceeded. For example, if dry heat is raised above 48° C., hyperlymphosis ceases abruptly; below that limit, on the contrary, lymphatic infiltration becomes evident in the deeper tissues, even in those lying beneath the layer of muscular fibers. Schaeffer admits, as does Kowalski, that special vasomotors exist for the lymphatics, as for the blood-vessels, since the active edema produced by heat does not resemble the passive edema resulting from stasis or compression.

Active edema accelerates the resorption of infiltrations, dissolves the leukocytes, and hinders their transformation into pus corpuscles. With the microscope, one may readily watch the leukocytes become diffluent and vague in outline, so as to resemble the "ghosts of leukocytes" (*leukocytenshatten*). As regards cataplasms, below 38° C. the effect is almost *nil.;* but above 43° C. it is quite the reverse. The more the applications are made near the beginning of the inflammation, the greater is their chance of preventing suppuration.

In short, the **action of heat** is characterized by: 1. An improvement in the circulation, which impedes the diapedesis of white blood-corpuscles. 2. If the leukocytes have already escaped, the lymphatic afflux returns them to the circulation. 3. Leukocytes incapable of regaining their vitality are dissolved in the lymph and for the most part disappear.

Hot applications should be made twice a day for one or two hours on each occasion. They may also be alternated with alcohol dressings. Dry heat obtained

by thermophores gives results identical with those obtained from moist heat, but insufflations of hot air do not act quite so well as cataplasms.

The idea that heat hastens the production of pus in abscesses is not exactly true; there is merely an increase in the serosity and not in the pus corpuscles.

In practice, whenever it is feared that an abscess may perforate the peritoneum or the meninges it is advisable to avoid hot applications or alcohol dressings

Heat favors resorption in cases in which it is desired to add to the local action of a serum the antibodies associated with hyperemia or hyperlymphosis. The same obtains as regards medicaments given by the mouth, which are likely to act better upon points rendered hyperemic by heat.

In ocular infections, therefore, it is always useful to employ local applications of heat, dry or moist, as well as general treatment by serotherapy or by the administration of remedies by the mouth, the skin, or the veins.

Methods of Applying Heat.—The simplest and certainly the most convenient method is by **moist compresses** of absorbent wool, covered with impermeable material, such as rubber tissue or paraffin paper, so as to prevent evaporation and dispersion of heat. The temperature of the liquid should be sufficiently high to heat the compress to about 42° C. at the moment when it is applied to the eye. There is no need of a thermometer to ascertain that fact, since an application of the compress to the back of the hand will enable one to determine whether the heat is supportable. The compresses are renewed every ten minutes for about an hour, night and morning, and perhaps in the course of the day if the patient feels the need for them.

The cataplasm or poultice also constitutes a very practical method of applying moist heat. The simplest and the best is the old-fashioned **linseed-meal poultice,** which is very emollient, very soft, and which adapts itself

well to the surfaces intended to be covered. Well packed into place by means of a thick layer of wool, it retains its heat for a long time. By first rubbing into the margins of the orbit some mercurial lanolin, one makes, as it were, a kind of **mercurial poultice,** which may be left in place all night. This constitutes a very practical and efficacious mode of applying mercury locally.

Vapor douches are commonly used in ophthalmology. They render great service in scrofulous keratitis, slight leukomata, blepharitis, chronic conjunctivitis, spring catarrh, etc. They act by heat and also by the more or less antiseptic **lavage** that they produce.

Recent Improvement in Applying Moist Heat.—Many appliances have been invented to replace hot compresses. One of the best is perhaps that designed by Maddox (*La Clinique ophtalmologique*, 1902), who intersects a round of flannel with a metallic filament, which conveys an electric current that maintains an almost constant temperature in the flannel previously moistened. The heat may be readily varied. Appliances constructed of metallic tubes forming round or oval plaques and conveying a current of hot water have been employed, but they are complicated and borne badly by the eye, in addition to which they lack flexibility and coaptation as regards the tissues.

Golescéanu (*La Clinique ophtalmologique*, 1905, No. 16) projects upon the eye by means of a bellows a mixture of air and of **steam** combined in such proportions as to obtain a moderate and constant temperature.

A simple means of keeping up the temperature of moist compresses as long as may be necessary is to cover them with a **thermophore** or caoutchouc bag filled with powdered sodium acetate. This chemical has the property of absorbing a great quantity of heat before it can pass from the crystalline to the liquid state. The thermophore is moistened for some minutes with boiling water, so that the salt becomes liquid, and is then applied over the eye previously covered with a moist compress. The same

appliance may serve for the application of dry heat, replacing the moist compress.

Dry heat presents few advantages over moist heat, although it may be preferable in many instances, especially when one has to deal with rheumatic affections. **Electricity** furnishes us with very practical means of applying dry heat. Maddox's apparatus, used dry, is useful, but a very simple plan when one is provided with electric current, is to apply to the eye, shielded by a layer of wool, an **incandescent lamp** of 8 to 16 candle-powers. Ostwalt (*Annales d'oculistique*, March, 1905) has praised a **thermo-aerophore,** by means of which a current of **dry, hot air** can be projected on the eye. A thermometer, fixed in the cavity which surrounds the eye, allows one to see what degree of heat has been reached by the air, which may be applied at 100° C., 150° C., or even 175° C.

Cold.—The action of cold, applied by a bladder of ice, has been known as long as that of heat. At first there is vasoconstriction, to which speedily succeeds a dilatation of the vessels, with slackening of the circulation and stasis, and reduction of all resorption. Inflammation is therefore reduced and more or less stemmed.

Schaeffer's experiences have confirmed the facts already established by clinical observation. Moreover, they have shown that not merely a diminution but an actual modification takes place in the inflammatory processes. He was able to prove that the arteries were little modified, (sometimes slightly contracted), while the veins, on the other hand, were everywhere dilated, and the circulation was much impeded. Although lymphocytes were few in the tissues, yet the dilated veins were full of them. There appeared to be a direct action of cold on the leukocytes, which, however, presented no microscopic changes. In opposition to that which is produced by the action of heat, cold has no prolonged effect. As soon as the application of cold is stopped, an intense reaction ensues. Iced applications, therefore, should always be continuous, and

in order to produce a favorable effect they should be applied without cessation from the beginning of the inflammation. They do not constitute a treatment, properly so called, but merely a means of relaxing the natural reaction of the organism and of paralyzing it in some way. Pain is rapidly reduced by such applications, but they leave diffuse infiltrations, which take a long time to resorb.

One can but agree with Bier when he says that it is much better to adopt the means that quicken the natural reactions of the organism. Heat also calms pain, but it has the additional advantage of hastening resorption.

In ophthalmology **iced compresses** are scarcely used except in blennorrhagic conjunctivitis, and even there they are sometimes dangerous and never to be depended upon. They have their indications, but these are rare. Gonococci are killed by a temperature of from 39° C. to 42° C. Copious lavage with a solution of permanganate warmed to 42° C. to 45° C. should certainly be more efficacious than iced compresses. The last-named, indeed, have the sole advantage of moderating the swelling of the tissues. They must be most carefully avoided in any case associated with false membrane.

According to Schaeffer's experiences, the action of **cold moist dressings** and of Priestnitz's dressing is less appreciable. The effect of moist dressings, covered with impermeable material, is very variable according to the duration of the application; the liquid employed to soak the dressing possesses little importance. To avoid the formation of a purulent focus, moist dressings must be changed as seldom as possible. **The Priestnitz dressing** consists of cold-water compresses covered with several layers of wool. They produce at first an increase in the inflammatory reaction.

Alcohol dressings act very differently according to the individuality of each animal. A compress of several folds is steeped in 95 per cent. alcohol, covered with impermeable material, such as gutta-percha tissue, and kept in place by

means of an occlusive dressing. The stronger the alcohol the more marked the results and the better the chance of preventing the formation of pus by provoking a strong hyperemia and an abundant flow of lymph, an action similar to that of heat. The action continues for several hours after the dressing has been removed. One application for an hour and a half of alcohol 95 per cent. has the same effect as one application of 70 per cent. alcohol for ten hours. The action upon the depths of the tissue is very marked, although it is believed that absorption of alcohol has nothing to do with this. It is, however, proved experimentally that the effect is much more energetic when 2 to 4 per cent. of salicylate or resorcin has been added to the alcohol.

Hot applications may with advantage be replaced by alcohol dressings in many instances, since the therapeutic action of the two is absolutely the same. The alcohol dressing may be termed an "autothermic poultice."

To summarize, the action of heat applied to the eye by moist compresses may be advantageously continued by the alternation of alcohol dressings and mercurial poultices. The indications for cold are very rare.

Revulsives such as tincture of iodin, blisters, etc., do not act by provoking a revulsion or a displacement in the inflammatory process. Like phototherapy and congelation (ethyl chlorid), they act by setting up an afflux of blood and lymph. The inflammatory reaction produced by **iodin** is very superficial, altering the epithelium more or less and bearing only upon the sub-epithelial tissues. The idea that irritation of the skin would set up a decongestion, an anemia of the deeper layers, is false; there is a subepithelial edema and a venous dilatation with more or less marked stasis. According to the experiences of Schaeffer, the action of this *soi-disant* revulsion is scarcely appreciable as regards inflammatory foci.

Mercurial plasters provoke a considerable accumulation of leukocytes beneath the epithelium, accompanied by

a rapid alteration of the cells. There is, in fact, a chemotaxic action of the mercury that has penetrated into the tissues. **Carbolic plaster** acts in the same way as the mercurial, but is more powerful. **Salicylic plaster** possesses scarcely any action.

Stasis Hyperemia.—This method has been used by Bier since 1893. Most authors explain its action by a stimulation of the defensive means of the organism against infective agencies. They assume that in the blood and the lymph resulting from the stasis there are antibodies or a stimulin, which excites all the cells to place themselves in a state of defense. The following steps have been observed: 1. Very marked venous tension and dilatation. 2. Persistence of the arterial pulse. 3. Cyanotic discoloration of the skin. 4. Heat of the skin. 5. The production of edema at the end of an hour or two. 6. The proof of this venous hyperemia may be obtained histologically by hemorrhage not accompanied by tissue changes.

Schaeffer has been able to prove by his experiments that stasis provokes a reduction in the number of the leukocytes, which become dissolved and disappear, thereby liberating a proteolytic ferment that gives a special action to the lymph.

The application of Bier's method to the eye offers certain difficulties. An elastic band may be placed around the neck, and left sufficiently loose to be supported by the patient for twelve to twenty-four hours. By this means photophobia and blepharospasm resulting from lesions of the cornea, such as keratitis parenchymatosa and eczematosa, have disappeared with the concomitant pain, at the same time that the ocular lesions have shown notable improvement. The best results have been obtained in cases of dacryocystitis and of styes, in which a suction apparatus may be directly applied.

CHAPTER VII.

PHOTOTHERAPY.

Phototherapy or heliotherapy has been adopted for some time in therapeutics after Finsen's very interesting experiments, but up to now its applications in ophthalmology have been on a very limited scale.

Daxenberg (*Wochenschrift f. Ther. u. Hygiene des Auges*, 1899) has praised **electric-light baths** in all cases in which the preparations of iodin, vapor, or dry heat have produced no effect in chronic affections of the cornea, sclera, iris, retina, or choroid, or vitreous body. Contrary to expectation, rheumatic iritis is rather made worse than better by electric-light baths. Personally, we prefer to combine these baths with local applications, heat, subconjunctival injections, etc. Winternitz also prefers to combine the light-baths with baths of warm air or of steam. In cases of iritis, parenchymatous keratitis, choroiditis, and opacities of the vitreous body, light-baths cannot be replaced by vapor-baths.

Doyne, of Oxford, employs phototherapy as a calmative to replace hot compresses in cases of cyclitis, iritis, etc. (*Ophthalmological Society of the United Kingdom*, 1901). He simply uses an ordinary electric incandescent lamp, which he applies close to the eyeball for from five to twenty minutes three times a day. Laquer, of Frankfort, has constructed a special apparatus which he calls **"Helidor,"** composed of six lamps, each of 16 c. p., thereby combining the effect of light and of heat (*Deutsche med. Wochenschrift*, 1901). The patients are placed in front of the appliance for fifteen minutes, three or four times a week. A lively redness of the skin, with slight perspiration, results from the exposure.

Sulzer (*Annales d'oculistique*, 1906) has praised phototherapy as practised by means of the Broca-Chalain **arc lamp,** to the action of which the eye, meanwhile kept open, is exposed for twenty to ninety seconds. The exposures are repeated at intervals of from eight to fifteen days. It appears that the actinic light at the same time that it reduces corneal sclerosis, frees the excretory paths of the intraocular liquids. Pupillary exudations become rapidly resorbed, and synechiæ ruptured. Sulzer concludes that physical agents are capable of improving the visual acuity of those affected with opacities of the cornea. Electrolysis combined with phototherapy he considers the best method to employ. But after having used the two methods comparatively, Sulzer is inclined to give the preference to phototherapy.

In 1906 Professor Eversbusch, of Munich, made trials with light as a means of treatment in affections of the eye. His results were published in two successive theses, namely, one by Koch in 1907, and the other by Kubota, which appeared in the following year. As the luminous source he employs a simple ampoule of about 20 c. p., which is held before the eye for five seconds, and then switched off, until the pupil has regained its normal diameter. These applications are repeated fifteen to twenty times, the applications being spread over weeks or even months. By this means in parenchymatous keratitis, deep keratitis, corneal ulcers, and descemetitis, the authors have obtained remarkable results. As shown by the reported cases, corneal infiltrations rapidly clear, and sight sometimes improves after each séance. This phototherapy, which is at the same time thermotherapy, acts by the chemical and the luminous rays, without our being able to say exactly which are the more active. The method is most practical and is easily applied, since nothing more is necessary than an ampoule and an electric current. It may readily be applied at the bedside, and if it be desired to use only the heat given out by the ampoule, the latter itself has

merely to be placed over the eye covered with a pad of wool.

Under any circumstances, there ensues a dilatation of the vessels, an augmentation of the nutritive exchanges and of the processes of oxido-reduction, together with an effect upon the intraocular fluids, as Kubota has shown by experiment upon the eye of the rabbit.

We may conclude that in phototherapy we possess a valuable means of hastening the resorption of corneal infiltrations and perhaps also of certain cicatricial leukomata.

When electric lamps are not available, we may employ gas or petrol light, and interpose between the luminous source and the eye a pasteboard diaphragm. In the orifice of the diaphragm we may insert an orange-yellow glass, which excludes the ultraviolet rays, or a convex lens, which concentrates the light and heat rays upon the sclerocorneal limbus. In this way the strength of the luminous source may be augmented if necessary.

Hertel (*Arch. f. Ophthal.*, lxvi, 1907) in an experimental and clinical study of the employment of light in ocular therapeutics, arrives at the following conclusions:[1] microorganisms of all kinds are killed in several seconds, while the normal cells of the part show much more resistance to the action of the rays. As the rays of long wavelength are harmful as regards the retina, the short wave rays must be employed in eye-work. The ultraviolet rays proceeding from magnesium sparks penetrate the cornea to a certain degree, but they are completely absorbed by the crystalline. The retina should be protected under these circumstances by the vitreous body, the crystalline, and the cornea. Hertel obtained very good results from phototherapy in twenty of forty-seven cases of infective ulceration of the cornea, which were followed by insignificant leukomata. It was necessary to subject the others

[1] As luminous source, Hertel employed induction sparks between different metallic electrodes, such as cadmium, zinc, and magnesium. The effect produced upon the tissues was examined with the microscope.

to the galvanocautery or to Saemisch's transfixation. The eye was exposed to the luminous rays for from three to five minutes every twelve or twenty-four hours. The first exposure provoked marked hyperemia, accompanied by a transient increase in the hypopyon. The technic, however, needs to be improved.

The sun's rays as a means of phototherapy calls for particular mention. Solar light is one of the chief factors in the maintenance of organic life. It is also a most powerful microbicide, a disinfectant, and a tonic essential to the maintenance of normal functions. All hygienic therapy may be said to be based upon air and light.

Solar light sets up a marked redness of the skin, and then by reflex action, an afflux of sudoral secretions. When unduly prolonged, this action provokes a solar erythema. The ultraviolet rays are absorbed by the blood at the surface of the skin, but there are radiations which penetrate more deeply, and the proof that such exist has been given by the work of Crooks, Röntgen, and of Curie. Sun-baths have long been employed in ocular therapeutics. When properly applied, they constitute one of the best ways of treating lymphatism and scrofula.

The local therapeutic action of the solar rays has been proved by Finsen, who carried out his original cures of lupus by concentrating the rays of the sun by the aid of lenses made of rock crystal, the heat of which he attenuated by passing the rays through a glass filled with water. It was later that Finsen replaced solar light by the electric arc.

For the relief of local tuberculosis, the action of sunlight has been most employed, and with much success.

Haberlin (*Münch. med. Wochenschrift*, 1907) has obtained encouraging results from insolation of wounds, which under the influence of light granulate, cicatrize, and become covered with epithelium.

Hirschberg has described a case of the cure of epithelioma of the external ear by light alone. Neoplastic cells,

very like microorganisms, are rapidly destroyed by the penetrating rays, but the normal cells may also suffer if the action be unduly prolonged. They defend themselves by interposing a layer of pigment. The pigmentation of those parts of the body exposed to the rays of the sun is therefore a means adopted by the organism for its defense.

The therapeutic action of the solar rays merits, then, thorough investigation, and astonishing results will be obtained by the practitioner who knows how to put them to the best use. In general, it is not necessary that the rays should pass through a glass plaque if one is to keep the effect of the ultraviolet rays. In order to localize their action, there may be used a pasteboard diaphragm, provided with a larger or smaller orifice and of a form adapted to the region about to be treated. The luminous rays can be localized upon a point no matter how small, such as an ulcer of the cornea. A greater number of rays may be converged upon the diseased focus by means of a rock crystal lens.

CHAPTER VIII.

ELECTRICITY.

Electrotherapy.

Indications.—Electricity has very precise indications in ocular therapeutics. Thus, the faradic current is particularly indicated in muscular paralyses, and when the muscular contractions begin to show themselves, it may usefully replace the galvanic current, which should always be applied at first.

Great expectations were based upon the effect of the electric current. By its employment it was hoped to modify the nutritive intraocular exchanges, to resolve opacities of the vitreous humor, and to make corneal or episcleral infiltrations disappear. Generally speaking, however, electric treatment has not proved itself superior to medicinal measures.

The best results are those which have been reported by von Reuss (*Klin. Monatsbl. f. Augenheilkunde*, 1901), who by electricity succeeded in calming the ciliary pain of iritis, iridocyclitis, etc. His method was as follows: In one hand he held an electrode, the other pole being held by the patient. von Reuss then passed his disengaged hand across the patient's eye, who should experience no shock but only a sensation of tingling and of very slight vibration. Relief was appreciable at the end of a few minutes. von Reuss believes that the faradic current applied in this way shortens the course of iritis and of keratitis, and in every case promptly relieves pain. In the treatment of scleritis, however, he prefers the galvanic current.

The use of **high-frequency currents** in ophthalmology is becoming more frequent, but this valuable method

of treatment has not been sufficiently studied. Truc, Imbert, and Marquès have treated by high-frequency currents a case of subacute hemorrhagic glaucoma, which iridectomy had failed to relieve. They obtained a notable reduction in tension and a marked improvement in sight.

The constant current, properly applied by an apparatus furnished with a galvanometer and a rheostat, should render real services. It must be borne in mind that *the positive pole, or anode, has a calmative action and the negative pole, or cathode, a stimulant action.* Applied to the eye, the current should not exceed 3 to 5 milliamperes, and the séances, which should last five minutes, should be held every day or every second day. The indifferent electrode is held in the patient's hand or applied to the back of his neck, while the other, anode or cathode, as the case may be, according to the effect desired, is applied to the eye or its surroundings, previously damped with tepid water, in order to heighten the conductivity of the tissues. In nervous affections electrotherapy acts not only upon the nerve-fibers and centers, but also by suggestion, especially in the numerous cases in which hysteria or neurasthenia plays an important part.

Electrolysis is one of the most valuable applications of the constant current is therapeutics. In ophthalmic practice, electrolysis is employed in feeble currents, of from 1 to 6 or 8 milliamperes. In trichiasis or distichiasis electrolysis yields extremely good results if the patient is able to bear the appreciable pain produced by the current. A very fine gold needle, connected with the negative pole, is introduced into each hair-follicle, one after the other, while the indifferent electrode (anode) is placed in contact with some other part of the body. A current of 3 milliamperes is allowed to pass for two minutes, when the current is reversed for an instant before withdrawing the needle, in order that it may come away more easily.

The pain produced by the passage of the current may

be lessened by rubbing the border of the eyelids with a 4 per cent. ointment of cocain or, perhaps better, by the marginal injection of a 1 per cent. solution.

H. Coppez and Gallemaerts (*La Clinique ophtalmologique*, 1902, No. 1) have recommended electrolysis in trachoma. They treat the trachomatous surface with a fine platinum fork provided with several teeth, and connected by the negative pole with a current of 2 to 3 milliamperes. Séances should be repeated five or six times or oftener if it be necessary at several days' interval, during which lavage and antiseptic friction should be applied. The results of this method of treatment are stated to be good and rapid. The same method has been applied by Coppez and Gallemaerts to trachomatous or phlyctenular pannus.

By Adler, Sulzer, and others electrolysis has been used in the treatment of opacities of the cornea. A tiny silver ball, connected with the negative pole, is passed over the surface of the leukoma for ten to twenty seconds, a current of about one milliampere being employed.

Good results may be obtained from electrolysis in the treatment of rebellious obstructions of the lacrimal passages. A silver probe, covered with insulating varnish when the current is not intended to pass, is employed. The instrument thus prepared allows the current to pass only when in contact with the spot where obstruction is believed to exist. It is connected with the negative pole, the positive being placed upon the patient's cheek or arm. A current of 4 milliamperes is allowed to pass for five minutes. After and before each séance a few drops of cocain or other anesthetic solution are injected into the canal.

Bipolar electrolysis (a needle attached to each pole being passed into the tissues) is often used in the treatment of nevus of the eyelids or face, in xanthelasma, etc.

In the hands of Abadie, Terson, and myself, electrolysis has sometimes yielded good results in the treatment

of detachment of the retina. A knife, constructed of iridized platinum, serving as the positive electrode, is passed into the sclera at the level of the detachment, and a current of 2 milliamperes is allowed to pass for two or three minutes.

Medicamentous electrolysis appears to have given interesting therapeutic results by making the particular ion indicated by the nature of the malady penetrate *loco dolenti*. In certain neuralgias of rheumatic origin a pledget of wool, saturated with a solution of sodium salicylate, has been placed over the painful point, and while the positive pole is applied to the affected spot, the negative pole is placed elsewhere. The current is opened and increased as much as can be borne by the patient and as much as is necessary to cause the pain to disappear (an hour or considerably longer). This method should be most useful in the treatment of a variety of ocular affections of rheumatic origin. Medicamentous electrolysis may be an excellent means of treating incipient cataract, saturating the anode applied to the eye with a solution of potassium iodid. Its effect should be as efficacious as that of subconjunctival injections, and it would have the added advantage over the last-named that it might be used by the patient himself every day.

Galvanocautery.

Paquelin's thermocautery and the red iron of former times have for long been replaced by the galvanocautery. The fine platinum points of the galvanocautery, which allow of a very exact localization of the cauterization, have rendered it possible to reach the interior of the eye, and in this way to attack grave infections at their beginning (Abadie, Darier, Peters, Baümler, etc.). But these deep cauterizations have the inconvenience of producing a cicatricial contraction, which may often be avoided by combining a less profound cauterization with general treatment

by paraspecific serotherapy. The galvanocautery is also most useful in the treatment of tumors of the eyelids, in trachoma, in some kinds of nevus, in ectropion, in scleritis and episcleritis, and, lastly, in conical cornea.

Forest, of New York, has invented an **electrocautery a froid,** the principle of which is absolutely new. The electric arc formed by a continuous current of 110 or, better, of 220 volts and thrown into the flame of an alcohol lamp produces an oscillatory current of high frequency. Upon a derived circuit are mounted the condenser and a self-induction coil. The frequency of the oscillations is about 300,000 a second. The potential of this current of high frequency and of feeble voltage is augmented by a multiplying spool. The cauterizing electrode is connected with one of the points of this apparatus, the particular point varying according to the intensity of the effect which it is desired to produce. This electrode is constructed of a platinum wire set in an isolating handle. Any form may be given to the wire, which is distinguished from the loop of the galvanocautery by the fact that it need not be arciform. The return wire being useless, the electrode may take the shape of a simple rectilinear wire of any given length or thickness.

The caustic action is produced only at the moment when the electricity comes into contact with the tissues. It remains limited almost to the region touched by it, and that constitutes the advantage of Forest's cautery, since, contrary to what takes place with the galvanocautery, there is a complete absence of radiation. The intensity of the current and consequently the intensity of the caustic action may be easily regulated by the aid of a special *manette.* This intensity is evidently inversely proportional to the surface of the electrode in contact with the tissues.

The electrocautery *à froid* may be used as soon as the current is established, its heating not being progressive as is the case with the other cauteries. Thus, the instrument is cold when the current passes, the conductivity of the

tissues in contact allowing the electrode alone to become hot. The electrocautery thus obviates the inconvenience presented by the contact of an instrument at a very high temperature with tissues which it is wished to preserve, while at the same time it allays the fear that a patient might feel at the sight of a glowing iron. Moreover, the wire is not likely to break, since it is never softened by the heat. Lastly, by reason of the capacity of the human body, the currents of high frequency proceeding from the electrode are propagated without the patient's experiencing any shock.

Forest's electrocautery fills an important gap in the applications of the thermal galvanocautery. It enables one, in fact, to carry out very delicate operations, such as the destruction of small cysts in the neighborhood of the eye, and to employ for the purpose an extremely fine electrode.

Electromagnets.

In the extraction of foreign bodies from the eye, the introduction of large magnets constitutes a marked progress. By large magnets foreign bodies may be mobilized in a manner not possible by the small magnets. Managed with prudence, they produce no disorder, and prepare the ground, so to speak, for the action of the small magnet in terminating the operation. The giant magnets of Volkmann and of Haab, respectively, are from this point of view instruments that can be surely and certainly managed, and in certain cases their employment gives extraordinary results. The patients retain sight equal to 1/3, 1/6, 1/8, 1/10. The removal of foreign bodies by the combined employment of the small and the giant magnet nearly always succeeds, especially when the intervention is undertaken soon after the accident. Practitioners summoned to accidents of this nature should never forget that success depends upon the rapidity with which the

foreign body can be extracted. Also the aid of the skilled skiographer should be summoned when possible. Observance of these facts will serve to lessen the relatively high high number of enucleations or exenterations after wounds by foreign bodies.

Lastly, in the removal of foreign bodies there is one rule which the surgeon must never forget, namely, that patience must be exercised. Once the presence of a foreign body is assured, attempts at removal must be persevered with until crowned by success. For example, the position of the patient and of the magnet must be varied, the current must be changed in direction and in intensity, the shape of the poles must be changed, the giant magnet must be replaced by the smaller instrument, and, finally, a wound must be made in the sclera when the foreign body cannot be drawn into the anterior chamber. In a word, the more certain the diagnosis, the more must attempts at extraction be persisted in, and success will follow the effort.

Until the year 1892 all efforts to extract magnetic foreign bodies were made with the *small electromagnet* introduced by Hirschberg about twelve years previously. This magnet is still most useful. Haab, Schlösser, Forster, and others then endeavored to profit from an electromotive force of greater intensity by employing large electromagnets. **Volkmann's magnet** is to-day the most popular. It weighs 25 kilograms, and has a length of about one meter. Its method of suspension, which is by means of a very solid iron gallows, allows it to be brought close to the eye of the patient, whether he be seated or lying down. The wires are wound in such a way that, with a current of 200 volts, two amperes only need be used.

Sideroscope.

For the diagnosis of intraocular foreign bodies the ophthalmoscope is most valuable, provided, of course, that the media remain transparent. When this is no longer

the case, stereoscopic radioscopy may give very exact information. When the foreign body is magnetic (iron or steel) the electromagnet may help toward diagnosis, since when applied to the eye it may provoke a sudden pain due to the mobilization it induces.

The sideroscope or magnetometer is the true touchstone as to the presence of particles of iron within the eyeball. Neither the electromagnet nor radioscopy allows of the same precision in diagnosis.

The principle of the sideroscope is based upon the fact that every magnetic foreign body causes the magnetic needle to deviate. A magnetic needle, suspended by a cotton thread, carries a tiny mirror, which reflects a light that can be seen to move, as soon as it comes near the smallest particle of iron. Indeed, the instrument is of such delicacy that the needle is deviated even by the vicinity of an electric tramway. In order to guard against this inconvenience, a magnet is arranged beneath the apparatus in such a way that the needle is kept perpendicular to the course of the tram-lines. An eye which contains the smallest particle of iron or of steel, as soon as it is brought near the sideroscope, deviates the needle together with its attached mirror, and the exact degree of the deviation is read off from a scale reflected in the mirror.

CHAPTER IX.

X-RAYS AND RADIUM.

X-Rays.

By means of the **X-rays,** it is now possible to recognize the presence of foreign bodies in the eyeball and its surroundings, and even, by combined stereoscopy, to determine their exact position. It will thus be seen that stereoscopy and radioscopy complement one another. But radioscopy not only affords a means to diagnose the presence of foreign bodies but also to recognize certain intracranial osseous deformities. For example, in some cases of atrophy of the optic nerve, an enlargement may be found of the sella turcica, which would lead one to think that atrophy was consecutive to compression of the chiasma by a neoplasm of the pituitary body. On inquiry into the history of such a case, one might find that the first symptoms included bitemporal hemianopsia, a characteristic sign of tumors of the hypophysis.

Since X-rays have led to loss of the cilia and eyebrows, and alterations in the conjunctiva, iris, and even the retina, it is clear that radiotherapy applied in the neighborhood of the eye should be undertaken with great care. The eye should always be protected by a leaden shell, and séances should be short and held at infrequent intervals.

X-rays have been also successfully applied in the treatment of different kinds of **neoplasm of the face and of the eyelids.** Their cytolytic action has been supplemented by the cicatrizing action of currents of high frequency. One should understand how to alternate and to superimpose the action of these potent physical agencies, and sometimes to complete them by surgical measures

when the tumor is widely diffused or difficult to affect by radiation. It may be said that radiotherapy constitutes the greatest progress yet made in the treatment of malignant tumors, and it may even be claimed that it is a specific form of medication, inasmuch as it produces cures such as have never been obtained before.

An excessive dose is the sole danger attached to this method of treatment. Properly administered, radiotherapy is never harmful.

Speaking generally, when a malignant tumor is suitable for operation, it should be handed over to the surgeon. As regards such epitheliomata of the face as have not extended beyond the dermis, radiotherapy should be preferred as a method of treatment, on account of the excellent æsthetic results thereby obtained. Whenever surgical intervention has been refused or postponed, radiotherapy should be tried. It should also be adopted in all instances of recurrence after operation. Finally, all inoperable growths should be treated palliatively by radiation.

Trachoma has been treated by X-rays with results quite as good as those obtained by the other methods of treatment (Mayou, Walsh and Stephenson, Bettremieux, Goldzieher, etc.). **Tuberculosis of the conjunctiva** has been treated by Sydney Stephenson by means of X-rays with rapid cure, and the experience has been repeated and confirmed by Aubineau and Chuiton. By Sulzer, Starr, Bennett, and Allport **spring catarrh** has been cured by radiotherapy. Pardo has treated by the X-rays cases of superficial and deep scleritis, and by this means has obtained better results than by other local measures.

Radium.

In the treatment of small neoplasms of the eyelids radiotherapy will be found preferable to the X-rays, on account of the difficulty of localizing the latter exactly.

The action of radium may be completed by the high frequency current. Radium presents the peculiarity of attacking, as it were, the pathologic tissues only, while respecting healthy tissues, as long as the dosage is properly adjusted to the end in view.

Mode of Application.—It is very necessary to know exactly the strength of the apparatus one employs; for its control, unhappily, is by no means an easy matter. That which is sold as pure radium is seldom really such, and the means of assay are often not available. On the other hand, every practitioner who desires to use radium may test the substance upon himself. He has merely to make a series of applications, of five, ten, and then fifteen minutes, on the outer surface of his forearm, noting for each exposure how long it takes for redness to appear, as well as the intensity of the redness and the length of time it takes to disappear. He can in this way assure himself as to what should be the duration of the pause in order that the therapeutic applications should remain in the non-dangerous zone. The minimum of activity which has an action upon neoplasms is that which is furnished by an apparatus provoking redness of the skin five or six days after an application which has lasted for twenty minutes. Such an apparatus contains 5 cgrms. of radium of 500,000 uranies spread over a surface of one-fourth of a square centimeter as an enamel varnish (Curie).

A milligram of pure radium (of 2,000,000 U.) contained in a very narrow tube of glass, should have almost the same action upon the tissues, since the glass absorbs many of the rays. In ophthalmic work it is convenient to employ an apparatus which can be readily applied to the conjunctiva and to the bottom of the fornices in cases of trachoma and of spring catarrh. As shown by the accompanying illustration (Fig. 2), the apparatus terminates in a ball as large as a small pea, the distal half of which is covered with enamel, containing 5 cgrms. of radium of 1,000,000 units.

Dermatoses and Superficial Neoplasms.—Radium may be regarded as a veritable specific for small epitheliomata of the skin of the eyelids and of the face. After a few sittings, nodosities melt and ulcerations become cicatrized, almost without leaving traces. But if relapses are to be avoided (always frequent in affections of this kind) the cure must be complete. If the glands are involved, the last-named must be subjected to X-rays and to the sparks from the high-frequency current. In severe cases surgical excision should precede treatment by radiotherapy.

Vicious cicatrices, keloids, are almost without exception much benefited by repeated applications of radium.

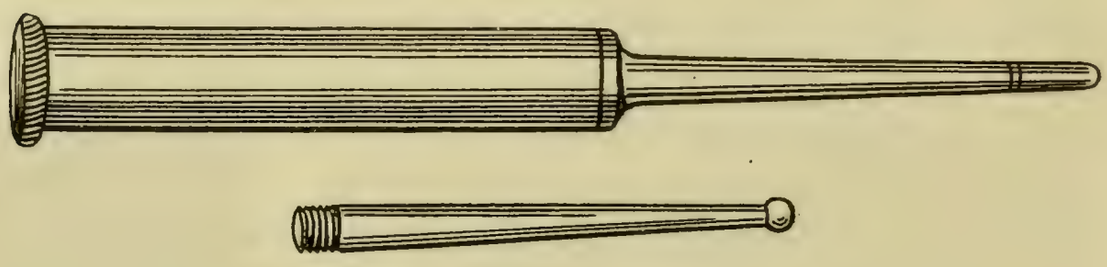

Fig. 2.—Radium Apparatus.

Small patches of **lupus** react very favorably to the influence of radium, although it would be unwise to treat lupus by this means if at all widely spread. At the most, one should treat by radium several small nodules which encroach upon the edge of the eyelids. Lupus occurring in syphilitic subjects yields rapidly to the repeated application of radium.

An indurated **chancre** of the eyelids can scarcely be treated with conspicuous success except by radium, which is the surest means of aborting the sclerosis if it is applied before the glands are involved. Radium at high activity and applied for a sufficiently long time brings about the rapid disappearance of the hardness of the chancre, together with the production of a supple and scarcely visible cicatrix.

Under the prolonged action of radiation, the capillaries undergo characteristic changes (Birsch-Hirschfeld). This point has been turned to profit in the treatment

of nevi, which can be cured by radium provided they are neither too thick nor too widely spread.

So far no author has mentioned the treatment of **chalazion** by radium. Nevertheless, in one of our patients two or three applications, each of from fifteen to twenty minutes, to the skin surface were enough to cause a chalazion of the size of a grain of wheat, to disappear in three weeks. The slight redness of the skin produced by the application did not last long, although it returned at intervals for two or three months.

Charles H. Williams obtained considerable improvement in a case of **uveitis** by one application of one minute, repeated two or three times a week for four months, with intervals of rest. He also obtained good results in a case of iritis with cloudiness of the aqueous humor, as well as in ulcers of the cornea.

In 1903, the author had encouraging results in cases of **trachoma** from radium, but no absolute statement can be made as to the value of the measure since the disease is rarely seen in Paris, and the cases that do occur are relatively benign. In 1905, Cohn, of Breslau, published several cases of cure, although, it is true, some doubt has been cast upon them. It is very difficult to be certain of the activity of radium when it is enclosed in a receptacle which may absorb the greater part of the radiations.

In order to decide the question of the value of radium in trachoma, one should be in a country rich in granulations, and choose a certain number of typical, classical cases in which isolated granulations occupy the culde-sacs and the tarsal cartilages. If possible, the cases selected should not have been subjected to treatment. Both eyes should be affected to the same degree, and one eye alone should be treated by radium. The other eye would then serve as a test. This is precisely what was done by Thielemann, who selected six patients from among the 120 who are treated every day in Koenigsberg, which is situated in the midst of a region infected by trachoma. None of

Thielemann's patients had been operated on; three had undergone no sort of treatment, and the other three had been subjected to medical measures. In order to make the conditions as nearly alike as possible, the eye not treated by radium was exposed to the air, with everted eyelids, for a time equal to that during which the radium was applied to the other eye. The ages of the patients ranged from seven to twenty-one years. The quantity of the radium, which was contained in a glass tube, was 2 mgrms. The radium tube was placed in contact with the everted eyelids for five, seven, and then ten minutes a day. To avoid all chance of danger, the cornea and the eyeball were shielded by a shell made of glass containing as much lead as possible. Beyond the radium applications no other treatment was employed.

The first result (seen in four cases) after seven or eight days of daily applications was a flattening along the inferior edge of the cartilage of the lower lid, the granulations were less marked, and in one case the granulations had even completely disappeared without leaving traces from that level. No changes manifested themselves as regards the upper lid until the tenth to the fifteenth day. The granulations looked smaller and harder, then, along the prominent border of the tarsal cartilage. To begin with, the granulations lost their yellowish-red appearance, then their prominence diminished and their limits became scarcely visible. The conjunctiva, no matter how pale it had been, assumed a rosy aspect in proportion as the granulations dwindled. The latter little by little came to resemble small hard nodules of a brownish-red color, scarcely projecting from the surface of the conjunctiva. Finally, the granulation was replaced by an obvious depression, a kind of dimple. The regressive evolution described above was always accompanied by conjunctival hyperemia, but secretion was never present. Lastly, of all the surface crowded with innumerable granulations there remained nothing except striæ, infiltrated folds, and more or less thickening,

as Thielemann was able to observe in one case on the thirtieth day. Granulations situated at the bottom of the culdesac were the tardiest to disappear, but those which remained longer than any others occupied the semilunar folds. Even on the forty-sixth day, these had not completely disappeared. The conjunctival epithelium had nowhere suffered destructive alteration; no granulation had emptied itself of its contents; no cicatricial furrow had formed.

As regards the eye not treated by radium, the granulous conjunctivitis had followed its course, which showed no signs of having been modified by contact with air or exposure to light. During the course of the treatment, no complication was observed in the eyes treated by radium, except in one case in which an attack of keratoiritis came on and disappeared in seven days without prejudice to sight and without relapse.

In order to complete these interesting clinical observations, which proved in the clearest possible way the macroscopic disappearance of the granulations, it was desirable that a more exact and scientific control should be established by microscopic examination. Thielemann fully understood the importance of this. In four of the cases he excised a flap of the mucous membrane in which, after treatment, there still remained the obvious infiltration mentioned above, and without wishing to draw general conclusions from cases, the number of which is still small, he found very considerable changes as compared with the untreated test cases. He was at once struck by the absence of all typical granulations, which had been replaced by a thickening of the fibrillary elements, with almost complete disappearance of Villard's cells and the nuclear bodies described by Leber as so numerous in all granulations. Lastly, here and there, small clumps of cells furnished the only indication of the vanished granulations. The thickness of the epithelium varied much, according to the regions, but in places it was three or four times thicker than normal. The ves-

sels were large and more numerous, but at the level of the atrophied granulations they were often blocked by polynuclear leukocytes.

After these experiences it is impossible any longer to deny the remarkably powerful action exercised by radium upon neoplastic granulations of the conjunctiva. From this we should not conclude that in radium we have the best method of treating trachoma. But in this novel physical agent we shall find a most valuable means to add to the treatment that has already proved its value, such as surgical exercises (Kohn, Selenkowski, Kardo, Szissojef, etc.).

Some authors have found that radium employed by itself does not cure trachoma, but that in cases treated with radium a few applications of copper sulphate lead to rapid cure (Fortunati, Businelli).

The action of radium might be compared with that of Finsen's phototherapy, which has been used by Lundsgaard in trachoma. Under this treatment Lundsgaard has seen granulations disappear quickly.

Affections of the Nervous System.—The therapeutic value of radium has been repeatedly reported in affections of the nervous system, and in particular neuralgias and neurites. But, unfortunately, the reports of its use in this connection have not been frequent or sufficiently definite.

In 1903, the author had occasion to remark the analgesic effects of radium in a case of epithelioma lancinating from the orbit and in several other cases, such as iridocyclitis and very acute iritis. In 1904 these observations were communicated to the Academy of Medicine, and to them were added two other observations—one of an intractable orbital neuralgia cured by applications of feeble samples of radium (activity varying from 1,000 to 7,000 U.) for two to six hours daily; the other of a recent facial paralysis which was cured in the interval between two applications. Success in facial paralysis can be looked for only at the beginning. In orbital neuralgia, when

all else has been tried in vain, one may still hope in some cases to obtain an unexpected cure by radium of feeble intensity.

At the Pau Congress (1904) Fauveau de Courmelles related a case of facial neuralgia which resisted stretching and section, and yet was cured in four days by daily applications of a radium-bearing powder of very feeble intensity (250 U.). In July, 1904, Raymond and Zimmern reported to the Academy of Medicine several cases of neuritis or neuralgia treated by five to twenty-five minutes' exposure to a powerful sample of radium—7 cgrms. of radium bromid enclosed in a glass tube. The cases gave negative and positive results. The negative cases included functional troubles without organic lesions, such as grave facial paralysis with the reaction of degeneration and a case of facial neuralgia which had resisted for eight years all treatment, even electricity. The category of positive facts consisted in the disappearance of girdle pains, of gastric crises, and of lightening pains in four tabetics. Suggestion, according to Raymond and Zimmern, counted for nothing, since in order to eliminate its influence, a glass tube, which did not contain radium, was applied under the same conditions and without results. It may be mentioned that the patients manifested radium dermatitis at the points where the radium had been applied.

H. Dominici has related several instances of the analgesic effect of radium. In Italy, Bongiovanni published in 1907 four cases of neuralgia and two of facial paralysis treated with success by radium (apparatus of salts included in varnish). The reaction of degeneration existed "partially" in the two cases of facial paralysis; in one of them the nerve was involved in the lower part of the Fallopian foramen. An appliance of 2 cgrms. of 100,000 activity was applied at a distance of 5 mm. from the skin, to a point corresponding to the stylomastoid foramen. A second appliance of 10 cgrms. of 500,000 activity was fixed at a distance of 5 cm. from the skin. For eight days

the applications were repeated along the course of the nerves of the right half of the face. Voluntary excitation of the muscles began to reappear on the sixth day, although electric excitability of the nerve was still absent. On the seventh day both electric excitability and voluntary mobility had been regained. In the other case, which responded to the picture of facial paralysis due to cold, the apparatus, which consisted of 2 cgrms. of 100,000 activity, was applied for two hours at a distance of 2 cm. from the skin. A dozen similar séances were held during the following days, the apparatus being displaced on each occasion so as to cover the right half of the face. Voluntary movement began to reappear from the first sitting, and cure was complete by the fifteenth day.

The four cases of neuralgia were: 1. A suborbital neuralgia with violent and frequent attacks of pain attributed to anemia. This case was treated with the apparatus spoken of above, the eyeball being protected by a leaden diaphragm. After an application of twenty-five minutes, the pain disappeared merely leaving behind it a sensation of tingling. On the following day there was an access of pain of the usual intensity, which was dissipated after a second application lasting half an hour. Three other applications, each lasting half an hour, were rendered necessary because hyperesthesia, associated with Valleix's points, persisted. All trouble, however, definitely disappeared after the fifth day. Cases Nos. 2 and 3 were analogous, and both were cured, the first after three séances each lasting for half an hour, and the second after nine séances. 4. The fourth case, due to malaria, was characterized by daily attacks of supraorbital neuralgia ushered in by severe shivering and followed by copious sweats. Five applications, as above, of a total duration amounting to three hours, brought about marked amelioration from the first séance and the disappearance of the attacks from the seventh day. None of the foregoing cases, it may be noted, presented radium dermatitis.

Most of these observations lack sufficient exactitude, but they are the first significant clinical indications. The points that should be mentioned are: the superficies of the particular apparatus employed, the available radiation, and the composition of the radiation as regards alpha- and beta-rays.

The clinical observations, however, are not numerous enough and the method is not sufficiently fixed to allow of definite conclusions. Nevertheless, the value of radium as an analgesic remedy in neuralgia and neuritis is clearly proved by positive facts, in which suggestion plays no part. Radium should be most useful in orbital neuralgia, but here its action has been found to be inconstant. It has been efficacious in several cases of facial paralysis (Darier), two of which were accompanied by a partial reaction of degeneration (Bongiovanni). With improved technic, it may be hoped that even better results will be be forthcoming.

CHAPTER X.

HYDROTHERAPY. MECHANOTHERAPY.

Aside from the general indications that arise from the tonic action of cold applications, hydrotherapy has some special indications in affections of the eye. Cold douches alone, or combined with hot douches, have a good effect upon individuals whose reaction is good. And in patients whom it would be unwise to subject to the cold douche, the cold wraps advocated by Priestnitz are very useful.

Trousseau, who has made an interesting study of watering places, concludes that, although diseases of the eye are often much benefited by the cures carried out in thermohydromineral or marine stations, at present the main indications of these cures have not been clearly formulated.

Patients suffering from iritis, iridochoroiditis, and rheumatic scleritis are often rendered desperate by the slowness of cure and the frequency of relapses. Although treatment at a resort similar to Aix-les-Bains is markedly successful in such cases, it should not be advised at the height of an acute outbeak. We must wait until the reactionary period has passed. At the same time, if, despite careful and prolonged treatment, one of these patients cannot be cured, we should not hesitate to recommend him to visit a resort before the inflammation has disappeared. The employment of the waters should be persevered in, even if a moderately acute attack occurs during the course of treatment.

The waters of Bourbon-l'Archambault are indicated in plastic forms of iritis; Royat in quite torpid forms.

Luchon is advised when it is wished to prevent relapses in exhausted rheumatic subjects. The same affection of gouty origin does well at Contrexeville, whatever may be its general tendency. Very chronic cases are improved by Vittel; very torpid cases, with a tendency to exudation, are benefited at Bourbon l'Archambault; lingering cases do well at Royat; and slight, fleeting, and recurrent cases at Thonon or Evian. To Vichy should be sent patients with acute iritis or scleritis, when once the painful period is over. Too much importance need not be attached to the reaction which is nearly always observed at the beginning of the cure.

Diabetic affections of the eye, such as retinitis, are little influenced by the waters. When the eye participates in diabetes, general prognosis is grave, and the hydromineral treatment has little virtue. A season at Vichy, however, is good preparation before operation for diabetic cataract.

A course at Bourbon l'Archambault and Neris favors the cure of paralysis of the muscles of the eye, as well as those following cerebral attacks.

Neuropathic women suffering from mucomembranous enteritis, who constantly complain of asthenopia, often find relief at Plombières. To Chatel-Guyon may be sent sufferers from intestinal autointoxication who are affected with iridochoroiditis. Tabetics affected with ocular paralysis and atrophy of the optic papilla should be advised to try the waters Lamalou, which possesses value, provided patients are sent early after the appearance of the first symptoms. Evian, Thonon, or, better, Bourbon-Lancy may be recommended to presclerous subjects affected with retinal or vitreous hemorrhages.

Many cases of conjunctivitis and of relapsing keratitis are due to nasal or nasopharyngeal affections, which may do well at Luchon, Mont d'Or, or sometimes at Salins in the Jura. Cases of eczema of the eyelids and of the conjunctiva, if rebellious, are improved at Saint-Gervais,

Royat, Luchon, or Bourboule, according to the indications drawn more especially from the general state of the patient. To women suffering with iridochoroiditis or choroiditis of genital origin (uterine), a stay at Luxeuil may render signal services, especially when the affection has compromised sight seriously and is distinguished by its obstinacy. Salis de Bearn may also be useful in such cases. Bagnoles de l'Orne is indicated in the eye diseases of the menopause. The phlyctenular impetiginous eye diseases and the scrofulous keratitis of children do well at Uriage, Bourboule, and Salins. Rebellious blepharitis improves rapidly at Bourboule and Saint-Cristaux, where the waters, employed in pulverization, are very efficacious.

The physician never hesitates to send to the sea-side a lymphatic or scrofulous child affected with recurrent keratitis. There is no reason why ophthalmic children should not take sea-baths, provided that the local reaction is properly attenuated.

Troublesome conjunctivitis due to hay fever may quickly improve at Mont d'Or, and cases of recurrent spring catarrh cease their periodic visitations after treatment at Bourboule. Syphilitic affections of the eye, which fail to yield rapidly to the usual means, sometimes make a quick recovery at Aix-la-Chapelle or Uriage, thanks to the intensive treatment practised at those places. Patients with syphilitic optic neuritis especially should be sent to Uriage.

Syphilitic interstitial keratitis, which is always serious, tedious, and relapsing, is very happily influenced by a stay at Uriage and Biarritz. The patient may be sent to Uriage even during the height of the inflammation, if regular surveillance be deemed unnecessary, but Biarritz should be advised only in the terminal stage of the disease when the redness of the eye has disappeared. Should Biarritz be badly borne, the patient should be directed to Arcachon.

Mechanotherapy.

From remotest antiquity massage has been employed in certain affections of the eye, and this practice has been continued to the present day in an absolutely empiric way. Conjunctival massage has been recommended in various affections of the conjunctiva, especially in trachoma. It would occupy much space to recall all the procedures that have been used from the days of Hippocrates.

Simple or medicamentous corneal massage has been applied, especially in leukomata, diffuse infiltrations, parenchymatous keratitis toward its decline, and even in episcleritis and spring catarrh. In some cases of tuberculosis involving the cornea and the iris, Abadie conceived the idea of practising direct massage of the cornea by means of iodoform-lanolin.

Personally, we have obtained very encouraging results from massage with mercurial lanolin in diffuse infiltrations of the cornea, in slight forms of parenchymatous keratitis, and especially in spring catarrh with pericorneal localizations. Massage with such substances as sugar and calomel has long been used in the treatment of leukomata of the cornea. At the London Congress in 1872, Donders recommended massage of the cornea (*Klin. Monatsbl. f. Augenheilkunde*, 1872), and Heiberg (Nagel's *Jahresbericht*, 1874) obtained good results from the method in faceted leukomata.

By Junger, Schodin, and Becker, massage has been recommended for the purpose of hastening absorption of crystalline masses remaining after the discission of cataract.

Pedraglia, Klein, Schenkel, and Czapodi have also published articles which were very favorable to massage of the eye. Mauthner and Hirschberg have seen emboli of the central artery of the retina become dissipated under the influence of massage. Pagenstecher (*Centralbl. f. prak. Augenheilkunde*, August, 1878) in a preliminary communication, was much struck by the fact that in one of

his cases the intraocular pressure was lowered by massage, and he had, moreover, the opportunity to observe a very good result from massage in a case of relapsing episcleritis. In a more complete communication (*Archiv f. Ophthalmologie*, 1881) Pagenstecher discussed with more detail and with very numerous facts circumbulbar and radial massage, which he found accelerated the nutrition of the cornea and conjunctiva. Before practising massage, he placed between the eyelids yellow ointment (10 per cent.), especially in cases of leukomata, pustules, and of spring catarrh. In cases in which the ciliary muscle was affected, Pagenstecher observed that massage had a very favorable effect upon accommodative asthenopia.

Gradenigo, Schenker, Wicherkiewicz, Gould, Pyle and Schnabel have remarked a transitory reduction of tension in glaucoma after ocular massage.

Gradenigo (*Congrès international de Rome*, 1894) praises the effect of massage in accommodative asthenopia, and has even observed an instance of paralysis of accommodation which was cured by this simple measure. He also cites a case of bilateral detachment of the retina, which was cured as regards one eye and was much improved as regards the other eye by massage repeated thrice a day, without any other treatment, not even rest in bed. Gradenigo attributes to massage a powerful action upon the blood and lymph circulation, the retina itself even undergoing a very marked trophic excitation.

Dantziger (Graefe's *Archiv*, 1895), after having reviewed all that had been written on the subject, simply relates ten instances of corneal trouble to which conjunctival abrasion was sometimes added, which were treated by massage with yellow ointment.

More recently, purely mechanical massage, the so-called **vibratory massage,** has been employed and studied seriously by Maklakow (*Archives d'Ophtalmologie*, September, 1893). For this purpose he employed Edison's pen, which is capable of giving 9,000 vibrations per minute.

The needle of the instrument, armed with an ivory button, applied over the ciliary region, provokes a partial contraction of the pupil on the corresponding side, and sets the aqueous humor in movement, so that the fluid becomes cloudy if there be hypopyon or becomes filled with crystalline masses if there be a traumatic cataract. In vibratory massage we have a very efficacious means of hastening the resorption of the lental masses. The vibrations are transmitted to the depths of the eyeball, and in glaucomatous eyes the intraocular tension becomes sensibly reduced at the end of several minutes. Chronic iridochoroiditis and punctate keratitis have been bettered by massage, which appears to act by hastening the lymphatic circulation and the intraocular exchanges. The deposits on Descemet's membrane are said to disappear after three applications of massage!

Sneguirew (*Congrès international de Moscou*, 1898) in thirty-six cases of leukomata obtained notable improvement in sight, especially after the first eight sittings. The same phenomenon has been observed in parenchymatous keratitis, which improved rapidly at the beginning, and sometimes even from the first *séance*. In serous iritis (four cases) the retrocorneal exudation disappeared after three or four massages—the iris assumed a more normal aspect and synechiæ became detached. In traumatic cataract and in needlings of the lens in cases of high myopia the crystalline masses are disengaged by massage, and their resorption is markedly accelerated. In eight cases of scleritis and of episcleritis vibratory massage yielded remarkable results. In sixteen cases of glaucoma, the intraocular tension fell from the first séance, although it often rose again during the next twenty-four hours. It, therefore, became necessary to repeat the massage several times a day.

Quite recently Piesperger, of Stuttgart, has published an account of the results he has obtained from vibratory massage (*Centralbl. prak. Augenheilkunde*, February, 1899).

In paralysis of the muscles of the eye after each séance of massage the motility was notably increased. He has obtained brilliant results from massage in cases of episcleritis, provided the massage is continued until such time as it produces not the least hyperemia. In very acute cases, one must wait until the extreme irritability of the eye has passed. In opacities of the cornea, sclerotizing keratitis, etc., results are slow but good. In parenchymatous keratitis massage should not be employed until the inflammatory phenomena have disappeared. The same remark applies to cases of iritis, iridochoroiditis, choroidoretinitis, affections in which massage sometimes yields surprising results when applied at the opportune moment.

More striking still were the results obtained in cases of long-standing choroiditis, in which scotomata diminished and the visual field enlarged at the same time that the fundus of the eye cleared and the sight improved. Retinal hemorrhages become resorbed more readily under the influence of massage. Reduction of intraocular tension and the more rapid absorption of the needled crystalline are also mentioned as among the obvious therapeutic effects of vibratory massage.

The pressure-massage of Domec has been recently suggested in the treatment of errors of refraction.[1] Domec describes his method as follows: "The end of each thumb, playing the part of a tampon is applied through the upper eyelid to the center of each cornea, the other fingers meanwhile being spread out flat upon the temples. By this means one quickly obtains the delicacy of touch necessary to feel if the cornea moves under the finger, as well as the lightness of hand necessary to ensure that the pressure is successive and not continuous. The total duration of each massage should be about five minutes, with one or two intervals of rest according to the individual sensibility. The pressures may be made rapidly or slowly. Some five

[1] Although to the modern English-speaking ophthalmologist this method does not seem practical or advisable, it has been thought worthy of description.—Editor.

hundred pressures must eventually be made at each sitting. In cases of asthenopia the eye must be scarcely touched during the first séances or the patients will cease the treatment after the third or fourth day." By means of pressure-massage, Domec has obtained in hypermetropes an apparent reduction in the hypermetropia and an increase, sometimes a considerable increase, in the visual acuity, especially in eyes affected with amblyopia, as is often the case in high hypermetropia or strabismus. In one case the hypermetropia was reduced down from more than 5 to more than 1.5 D., and the visual acuity rose from 1/20 to 1/6 at the same time that the reading of small characters was made possible with relative weak glasses. Domec explains his results as follows: The pressures exercised upon the flexible cornea are transmitted through the ocular media. The crystalline must participate in the movement of coming and going of the cornea. The fibers of the zonule of Zinn are stretched by each of the pressures exercised upon the cornea, increasingly more as the pressure is stronger and more sudden. This series of twitchings (*tiraillements*) will be likely to produce finally a distention of the zonule. The action of the ciliary muscle being thus augmented, the accommodative power grows rapidly. When a certain number of massage applications have been made, the fibrils of the zonule of Zinn remain more or less permanently distended and hence the hypermetropia diminishes (see Darier, *La Clinique ophtalmologique*, 1899, No. 8).

"This persistent elongation of the zonule is the easier to obtain the younger the subject and the less accommodation has been used (amblyopic eye)." It need hardly be added that Domec's theory is plausible only on condition that Helmholtz's hypothesis of accommodation be admitted.

From what has been said it follows that, in appearance at least, hypermetropia may be more or less reduced by pressure-massage, and that the visual acuity is some-

times increased to the point that an eye unable to be used by reason of amblyopia ex anopsia resulting from high hypermetropia, may become adequate for ordinary work, and that certain squinting eyes may thus recover sight enough to ensure the radical cure of strabismus with binocular vision.

Different types of accommodative asthenopia are also susceptible of great improvement, and such a hypermetrope who was unable to do his work except with his glasses has been able to content himself with lenses of 1.5 D., as was the case with Domec himself. The treatment acts better and more quickly the younger the subject, since the elasticity of the crystalline is greater and the ciliary muscles possess stronger action. It yields remarkable results when it is applied to an eye that is at once hypermetropic and amblyopic, its fellow having good visual acuity. On the other hand, when both eyes are amblyopic, the improvement is less marked. Indeed, in aged subjects it is very little. Among presbyopes, the wearing of convex lenses may be postponed by vibratory massage.

Some myopes improve markedly in both distant and near vision, without the myopia being diminished in any appreciable way. In the progressive myopia of young subjects, when the refraction has increased 5 or 6 D. in the course of a single year, Domec has arrested increase by successive series of massages.

It is especially in convergent hypermetropic strabismus, occurring in subjects whose ages are between ten and twenty years, that brilliant results have been obtained, particularly when the sight of one eye is good and that of the other poor. The following is the method pursued in these cases. To begin with, the refraction is, of course, estimated subjectively and objectively, and the visual acuity is noted, with and without correction. The amblyopic eye is then treated with massage for ten consecutive days. The sight of that eye may show an improvement

from the first day, a sign of good augury. In other cases the vision manifests no improvement until after about ten séances. As soon as the vision is slightly bettered, glasses correcting the ametropia of the amblyopic eye are prescribed, so that this eye is capable of seeing and of working by itself. The sound eye is then treated with atropin for about a fortnight.

It is interesting to observe the improvement of vision in the amblyopic eye under these circumstances. The eye, which scarcely served to allow the patient to go about, gains sight enough to enable it to read and to do ordinary work when provided with suitable glass and after some séances of massage and a little exercise.

If the strabismus is very pronounced, nothing remains but to perform tenotomy or muscular advancement in order to obtain a perfect correction, especially if the operation be followed by a series of stereoscopic exercises. If operation be refused, supposing the patient is young and the parents persevering, one may attain a good result by months or years of stereoscopic exercises and the use of suitable correcting glasses, together with the employment of atropin to the good eye for one week in every month.

In cases of accommodative asthenopia, success may be obtained when the vision is from one-half to two-thirds. Under such circumstances after four to ten sittings vision may rise to normal, often without the least trace of asthenopia.

In hypermetropes we must distinguish between two very different categories, namely, the young and the old. In the former the effects obtained by massage are sometimes surprising. For example, in children from ten to fifteen years of age, with hypermetropia of 2 or 3 D., the error has been completely compensated under the influence of pressure-massage—that is to say, sight both for distant and near objects has become as good without glasses after massage as it was before with correcting lenses.

The greater the age, the less efficacious becomes the action of massage and the less the hypermetropia diminishes. Indeed, after the age of fifty years, massage tends even to be painful, and should accordingly be practised with proper management and care. In certain cases, it is true, it is useful; but in others it may accelerate the development of such crystalline opacities as may previously have existed.

One sometimes sees hypermetropes whose visual acuity without glasses rises suddenly from one twenty-fifth to one-tenth, from one-sixth to one-third, from one-third to two-thirds, etc., while the power of reading improves in the same proportions. In hypermetropes with amblyopia the improvements effected in vision are even more marked, and it is noted that this almost instantaneous improvement of sight is not observed among patients whose sight has been lowered for a long time by changes in the fundus of the eye, opacities of the cornea, etc. Explanation of the reported remarkable cures by ocular massage may be found in the fact that such eyes no longer make the effort necessary to see, from which results partial paresis of the ciliary muscle and an amblyopia from lack of use, which is improved by massage.

Myopes also may experience an increase of the visual acuity under the influence of massage; this visual acuity may improve while the myopia actually increases. There must be, accordingly, several causes which act in the improvement of the vision under massage: 1. Mechanical action upon the zonule and the crystalline; 2. tonic action upon the ciliary muscle and the accommodation; and 3. trophic action (circulatory, secretory, and excretory) upon all the intraocular liquids and tissues, ciliary glands, choriocapillaris, retina, etc.

Personally, the author has studied comparatively the effect of Domec's pressure-massage and that of vibratory massage in many different pathological conditions, and it has seemed that the two procedures give almost

identical results. To explain the action of the different kinds of massage in long-standing leukomata, keratitis parenchymatosa, and various chronic pathological conditions, in addition to the trophic action, we must attach importance to the mechanical action of the massage upon the crystalline system and the accommodation.[1]

In some cases of prodromal glaucoma, massage has brought about a prompt improvement. In these cases there is an immediate action upon the intraocular tension, which becomes reduced in the course of a few minutes. The pressure brought to bear upon the cornea, driving back the iris and the crystalline, frees the iridocorneal angle and facilitates the exit of the intraocular fluids, and at the same time there should be a direct action upon the ciliary muscle and the accommodation. An intelligent patient affected with prodromal glaucoma may prevent or abort slight attacks by practising massage upon himself as soon as he becomes conscious of cloudiness, aureoles, and so forth. Although massage cannot replace iridectomy, when properly applied it renders great service. All who have seriously practised it are unanimous in crediting massage with a powerful action upon the intraocular tension. This effect, it is true, may be only transitory, but it is easy to repeat the séances so that the method becomes a practical one, more especially when we are dealing with educated and intelligent patients, capable of carrying out the treatment for themselves. On the other hand, in peasants, old persons, and clumsy individuals, automassage can scarcely be recommended.

Massage gives especially good results in elevations of the intraocular tension provoked by the unduly rapid swelling of crystalline masses after discission or injury. Under its influence, tension diminishes and the masses

[1] Stimulation of compensatory accomodative power by any means is likely to be followed by all the baneful local and reflex symptoms of ametropic eyestrain. In America, at least, the chief work of the ophthalmologist is to prescribe proper correcting lenses to prevent this very ciliary strain.—EDITOR.

become resorbed, and in this way the numerous punctures that might otherwise be necessary are avoided. In these cases, too, massage allows us to employ dionin and subconjunctival injections of sodium iodate.

Massage is also recommended in blepharospasm, spasm of accommodation, neuralgia, blepharitis, and chronic conjunctivitis and corneal infiltrations.

In cases of retinal embolism, pressure-massage has yielded unexpectedly good results to several operators, notably Hirschberg, Wood, Würdemann, and Hess.

CHAPTER XI.

LOCAL MEDICATION. ANESTHETICS. ANALGESICS.

Local Medication.

From remotest antiquity different remedies have been applied directly to the eye, as dry collyria or powders insufflated into the eye, as soft collyria or ointments, and, lastly, as liquid collyria.

Powders.—Calomel is one of the most popular of the dry collyria. In order to render it lighter and more easy to insufflate, it should be mixed with equal parts of sugar of milk. The insufflation may be made by means of a special insufflator or simply dusted on with a camel's-hair brush. Airol, protargol, xeroform, and many other powders insufflated upon corneal, conjunctival, or cutaneous wounds are valuable in preventing suppuration and of hastening cicatrization. Xeroform is particularly to be recommended on account of its perfect pulverulence, which renders its insufflation very simple, a thing that is unfortunately not the case with iodoform. The phenol and bismuth, which enter into the composition of xeroform, render this therapeutic agent an antiseptic of the first rank and a most efficacious astringent or antipurulent.

Ointments are commonly used in the treatment of blepharitis, keratitis, etc. The best-known is the yellow ointment, the so-called Pagenstecher's ointment, which possesses, as it were, a specific action in lymphatic conjunctivitis, and especially in phlyctenular keratitis, which is always more or less closely connected with scrofula or lymphatism. In order to be nonirritating, this remedy should be prepared with much care. The precipitate of the yellow oxid of mercury should be obtained by the

moist process, be used quite fresh, and be so intimately porphyrized that no coarse particles can be seen with the microscope. When these requisites are observed, yellow ointment is well borne even when used as strong as 10 per cent. It should never be given for home use, unless we are assured that it has been properly compounded.

Ointments are easily applied, and, thanks to the utility of vaselin and lanolin, a number of substances may in this way be used to the eye. Under some circumstances they present advantages over liquid collyria. By means of ointments we may introduce into the conjunctival sac stronger doses of a given remedy, which has consequently a more durable action upon the parts. Therefore, when desirable, an ointment may be substituted for collyrium, no matter what medicaments are used. When insoluble substances are prescribed, ointments are most useful.

Ointments may with advantage be dispensed in metallic tubes, lined with a special glaze, in order to render them indifferent to the chemical agents which they contain. The tubes terminate in a rather long nozzle, which allows the ointment to be readily placed between the eyelids.

Mercurial lanolin (mercury and lanolin, equal parts) is nonirritating and keeps very well, especially when it is put up in gelatin tubes or ampoules. It may be employed with excellent results by friction-massage in certain corneal or pericorneal infiltrations, in interstitial keratitis, episcleritis, and spring catarrh.

Oily collyria have the same disadvantages as have been theoretically cited against oily hypodermic injections; but for some medicaments which do not keep well in water they may be useful. Thus, oily solutions of physostigmin are preferable to ordinary solutions, inasmuch as they keep much longer without alteration, and their application to the conjunctiva is much better supported by the patient. The oil, however, must first be properly sterilized.

Oily collyria have one marked objection in that they deposit on the surface of the cornea an oily layer, which

causes some disturbance of sight (the patient sometimes complains of seeing a halo around lights), and if it is desired to make an ophthalmoscopic examination at this moment, the fundus of the eye is seen as through a cloud. Another inconvenience is that subsequent instillations of an ordinary collyrium glide over the oily surface of the eye and escape rapidly with the tears.

Aqueous Collyria.—With few exceptions, ordinary collyria, made with sterilized distilled water or with artificial serum, are the most convenient in everyday practice. Small quantities of liquid only should be prescribed for home use, since the solutions undergo change so rapidly. Five grams of any given collyrium is nearly always enough. In clinics the sterilization of collyria is an easy matter, particularly in dealing with ordinary solutions which are not decomposed by boiling. Even cocain stands boiling well enough, especially in weak solutions, such as 3 per cent. (Merck).

In dealing with wounds of the eye or with operations, the best way to prevent infection by collyria is to employ before, during, and after operation sterilized solutions contained in ampoules.

In the hospital, as in the town and in the country, with a box of assorted and hermetically sealed tubes of cocain, atropin, physostigmin, dionin, adrenalin, etc., every indication, no matter how unforeseen, that may arise during the course of an operation may be met, and that with an aseptic security that no other means can give so simply and practically. Every practitioner may thus be provided in his office, or even in his instrument case, with the principal collyria without ever having to fear that they will show the least alteration whatever.

Although discussion of the manner in which collyria act is not in place here, it is interesting to note that atropin instilled into the conjunctival sac penetrates into the aqueous humor, so that a drop of the latter liquid, placed in a second eye, provokes in it dilatation of the pupil. It is

recognized also that by the repeated instillations of solutions of fluorescein, the intraocular fluids may be colored, and this method, indeed, has been recommended by E. von Hippel to establish the early diagnosis of alterations in the membrane of Descemet. It therefore follows that a soluble substance introduced into the conjunctival sac, is able to penetrate into the ocular media by corneal and conjunctival absorption.

Classification of Local Remedies.—Ocular topical remedies may be divided into:

1. Those capable of modifying the superficial sensibility, known as anesthetics, such as cocain, eucain, holocain, alypin, etc.

2. Those capable of modifying the deep sensibility, known as analgesics, such as dionin and acoin.

3. Those capable of modifying the muscular tone, known as mydriatics, cycloplegics and miotics.

4. Those capable of modifying the vascular tone, known as vasodilators, such as dionin and peronin, and vasoconstrictors, such as adrenalin.

5. Those capable of modifying secretions, such as astringents, caustics, antiseptics, etc.

Ocular Anesthetics.

General Considerations.—Prior to the discovery of cocain, belladonna, opium, and their derivatives were the only means in our possession of calming local pain, and in addition it was usually necessary to resort to general medication to calm the pain of affections of the sclera, cornea, iris, etc. Operations were performed under general anesthesia by chloroform or ether. Narcosis, however, in ocular surgery should be employed only for serious operations that cannot be undertaken without its influence. The surgeon ought to be able to foresee whether general anesthesia is necessary. Often his powers of persuasion and the confidence which he inspires in his patient allow

him to undertake many operations with no anesthetic other than cocain. Operations in certain cases of acute glaucoma, the brossage or curettage of granulations, Kroenlein's operation, and so forth, necessitate complete narcosis, and the same remark applies equally in some cases to enucleation and to squint in very young subjects.

Injections of morphin and of scopolamin have been recommended recently as a means of producing general anesthesia, but this method is not entirely free from danger, and a certain number of deaths has already been placed to its account. When a short operation is likely to be painful, 0.03 to 0.05 of dionin may be injected into the temple half an hour before operation. This substance has the great advantage over morphin that it produces neither vomiting nor somnolence. Thanks to this measure, combined with the local application of cocain, one may proceed successfully in operations of delicate and painful nature. The patients may return to their homes one or two hours later without inconvenience; and after a good night's sleep, they may, if they feel so disposed, return next day for consultation.

Another most useful means in ocular surgery is anesthesia produced by ethyl chlorid or somnoform. These agents induce complete narcosis in the course of several minutes, and the anesthesia lasts long enough (two to five minutes) to allow of many small operations being undertaken painlessly. The duration of the anesthesia may be prolonged by continuing the administration with a few drops of chloroform, which under these circumstances becomes less dangerous.

The principal anesthetic agents used in ophthalmic practice are cocain, acoin, and dionin. Cocain calms almost at once superficial pain, but the duration of the analgesia is very fleeting, twenty minutes at the most. In man acoin does not act in watery solutions except when there is a solution of continuity of the corneal or conjunctival epithelium, and in such case its analgesic action may

persist for several hours. Its action is most valuable, as we shall see later, in burns of the conjunctiva or traumatic erosions of the cornea. An oily solution of acoin has a lasting analgesic action upon the eye of man. Dionin may be spoken of as a deep analgesic of long duration, capable of placing, as it were, the entire eye to sleep for a sufficiently long time.

Cocain.—A drop of 3 per cent. or 5 per cent. cocain instilled into the eye provokes, to begin with, a sensation of smarting, often not agreeable to some and positively disagreeable to others. This sensation may be diminished by getting the patient to look upward after the drop has been put into the eye at the same time that the lower lid is slightly everted. The idea is to prevent the cocain coming into direct contact with the cornea until a few seconds after the conjunctival surface has been well impregnated. This simple expedient is useful in daily practice, where it is always well to cause as little pain as possible.

The smarting sensation does not last long, and is followed by a sense of heat in the eye which can scarcely be closed. The eyeball feels larger and the palpebral fissure is widened, the eyeball is prominent, and a little protruding. The sclerotic is of a more striking white, in consequence of the anemia of the conjunctiva, the result of vasoconstriction. The cornea may now be touched without inducing pain, and many operations may be undertaken without the patient's being conscious of the least suffering.

The degree of anesthesia varies according to the subject, the number of instillations, and the concentration of the solution employed. Just as there are subjects refractory to cocain, so there are those who are very sensitive to its action. Some individuals become intoxicated by infinitesimal doses, and although such cases are very rare, one should recognize their existence, and be prepared for them.

Generally speaking, anesthesia of the surface of the

cornea is appreciable four to five minutes after the instillation, and it attains its maximum at the end of from ten to fifteen minutes. Sensibility is regained, little by little, after twenty minutes. Amost identical results are obtained whether a 3 per cent. or a 5 per cent. solution be employed. But it is preferable to use weak solutions (3 per cent.) which are less painful, and to repeat the application several times.

The removal of a superficial foreign body may be undertaken, without pain, ten minutes after a single application of cocain. On the other hand, if paracentesis of the anterior chamber is to be performed, and especially if any instrument must be introduced which might touch the iris, three or four instillations must be made, and the operation should not be commenced until twenty-five or thirty minutes after the first application. If one has to deal with a very sensitive subject, instillations should be supplemented by a subconjunctival injection of one or two drops of a 2 per cent. solution of cocain near the place where the incision is to be made.

Subconjunctival injections of cocain, made at the level of the muscular insertions, permit us to operate upon cases of strabismus without chloroform, and nowadays we never administer chloroform for a strabismus operation in a patient above nine or ten years. If cocain is applied correctly, the patient should feel nothing unless one has to deal with one of those rare subjects rebellious to the action of cocain.

When the management of cocain was not yet well understood, many inconveniences were experienced. For example, cocain was at first condemned on account of its deleterious action upon the corneal epithelium. This action is real and undeniable, but in most cases the loss of luster of the cornea provoked by cocain is in part due to desiccation of the membrane by evaporation, the eye remaining open and insensitive to external irritations. In fact, as soon as there were taken precautions to keep

the eye closed, and to abstain from sublimate washings, corneal complications were no longer observed, except in cases of an infective nature, in which the resultant opacity was unavoidable.

There are instances in which the anesthesia caused by cocain persisted for four or five days. Serious accidents may result from this. Thus, a diabetic who kept his eye open for three days under his bandage noticed at each movement of his eye very brilliant luminous scintillations, provoked by the rubbing of the dressing over the cornea, but without experiencing the least pain. The result was an ulcer of the cornea, which proved extremely rebellious to treatment.

Mydriatic Action.—At the end of about twenty minutes, cocain produces dilatation of the pupil, which may last for several hours, and be accompanied by difficulty in sight, caused by a slight paresis of accommodation, which lasts from a few minutes to several hours, according to the dose and the individuality of the patient. This is one of the drawbacks of cocain; but it is also a relative advantage, since the mydriasis allows one to make an ophthalmoscopic examination which might otherwise be difficult.[1] The mydriatic action of cocain may be utilized also in the simple extraction of cataract without iridectomy, but it has the grave inconvenience in predisposed subjects of sometimes provoking attacks of glaucoma, which may have the most serious consequences. Cocain, however, is far from being in itself an agent which raises the tension of the eye, since one often sees after its application, a hypotony which in some subjects goes as far as to provoke an almost alarming collapse of the eyeball in the course of some operations for cataract, especially among very aged persons. Doubtless it was from observations of this kind that Groenouw proposed to treat glaucoma by the use of strong doses of cocain. Instil-

[1] Euphthalmin dilates the pupil *ad maximum* in fifty minutes, without affecting accommodation appreciably.

lations of cocain sometimes cause a sensation of cold and of dryness. Its prolonged use ends by setting up conjunctivitis, lacrimation, and often cloudiness of the cornea.

Subcutaneous injections of cocain may cause grave toxic accidents, capable of causing even death. It is therefore of great importance to recognize that we should never employ cocain except in feeble doses and in very dilute solutions, more especially in operations upon the eye or the face. Certain very sensitive individuals after simple instillation into the conjunctiva, may experience disquieting nervous phenomena, such as agitation, palpitations, loquacity, subdelirium, dyspnea, etc. In collyria, therefore, we employ no stronger solutions than 2 or 3 per cent., and in hypodermic injections a 1 per cent. solution, and we never exceed a dose of 0.02 to 0.03 of cocain in periocular injections.

Poisoning by cocain immediately shows itself by pallor of the teguments and tendency to syncope. Its prognosis, in general, is grave. Almost always in these cases cocain has been employed in therapeutic doses (0.05 to 0.10 at the maximum). But often the customary precautions have been omitted, namely, to keep the patient lying down during the intervention and for the following two or three hours. Accidents observed despite the adoption of these precautions must be attributed to individual susceptibilities. Fear and a neuropathic state which predisposes to syncope are factors with which we must always reckon. At the same time, there can hardly be serious poisoning from cocain when a therapeutic dose only has been given and the precaution recommended above has been followed.

In dealing with an acute intoxication from cocain, we must first put the patient to bed, since syncope is the greatest danger. Amyl nitrite, a vasodilator and energetic antagonist of cocain, should be at once respired. Then black coffee may be given, hypodermic injections of ether administered, the body rubbed, and diuretic and

sudorific drinks and medicines given, in order to hasten the elimination of the poison by the various emunctories.

The toxicity of cocain has incited chemists to endeavor to find other substances having the same anesthetic properties without being also toxic.

Eucain B. possesses the anesthetic virtues of cocain without provoking dilatation of the pupil. It is, moreover, readily sterilizable. On the other hand, it provokes marked hyperemia and causes more smarting than cocain. Its toxicity is almost twice as little as that of cocain. Lastly, the lactate of eucain has been spoken of favorably.

Tropacocain, which at one time appeared likely to supplant its half-sister, cocain, is scarcely heard of now. It is as irritating as cocain, and more painful, even when a physiologic solution of sodium chlorid is used as the vehicle. It is worthy of mention, however, that the anesthesia produced by it is more prompt and more profound than that of cocain, while the mydriasis is less marked and the toxicity less.

Holocain has been well spoken of during the last few years. Its anesthetic power is at least equal to that of cocain and much superior to that of eucain; it does not dilate the pupil; it possesses certain antiseptic qualities, and may be boiled without inconvenience. But holocain, which is much more toxic than cocain, cannot be used for subconjunctival or subcutaneous injections, at least only in very dilute solutions. In glaucoma a subconjunctival injection of 1 per cent. holocain renders iridectomy painless. It is exactly the same with cocain and the other local anesthetics when injected beneath the conjunctiva. Even enucleation may be performed without great pain by making deep injections of 1 per cent. cocain at the level of the muscular insertions and near the optic nerve.

Stovain was first produced by pure synthesis in 1903. This substance renders great services in surgical infiltration anesthesia, as well as in rachiostovainization, as

shown by the recent conversion of Bier, the author of rachiococainization. But for anesthesia of the eye by instillation, cocain remains superior to stovain from several points of view. Stovain used in animals has about one-half the toxicity of cocain, and its employment in human surgery shows that in equal anesthetic doses its toxicity is also much less. Acting especially upon the nervous system, stovain does not seem to be a cardiac poison, although recently the addition of strychnin is advised in solutions to be injected. It tones up the myocardium, augments the intensity of its contractions, and, so far from provoking bulbar anemia, it rather produces a feeble vasodilatation. The apparent freedom from syncope allows patients to be operated on in a sitting posture, while all prudent operators insist that a patient shall be lying down when cocain is employed.

As a local anesthetic, stovain is less powerful than cocain when employed in equal dose. The classic solution of cocain, 2 : 200, may be replaced for infiltration anesthesia by an analogous solution of stovain, 1 : 200. It allows of the same operations as cocain, and of longer interventions necessitating much stronger doses of anesthetics. Stovain is antiseptic and antithermic. But notwithstanding all, cocain still retains its preeminence as a conjunctival instillation, since it is less painful than stovain and its toxic action need not be feared under these conditions.

If a more rapid anesthesia of the cornea is desired, the physician may employ the following collyrium:

Stovain or alypin	0.10 to 0.20.
Cocain hydrochlorid	0.10 to 0.20.
Physiologic salt solution	5.

The results will be even better if a little adrenalin be added to the collyrium.

In anesthesia by subconjunctival or subcutaneous injections, as in operating upon strabismus or upon the

eyelids, stovain is clearly superior because it is less toxic. When it is desired to prolong the anesthesia, we may associate stovain with acoin, which will give an analgesia lasting for several hours.

A mixture of equal parts of acoin, stovain, and cocain gives an infiltration anesthesia of much longer duration than one produced by cocain alone.

Alypin, in 4 per cent. solution, brings about complete insensibility of the cornea in two or three minutes, provoking neither mydriasis nor disturbances of accommodation. These two important qualities, however, are also possessed by holocain, eucain, and stovain. Before abandoning the use of the well-tried cocain, we must demand at least an insensibility as profound and as lasting, and this unfortunately has not yet been shown with any of the substitutes of cocain.

For practising subconjunctival injections, the anesthesia produced by alypin or stovain is not always adequate. Mixed with the solution to be injected, alypin diminishes the pain for the first moments, but its action is less marked than that of cocain and especially much less prolonged than that of acoin. Alypin resembles stovain and eucain in its very rapid anesthetic action, with little effect upon either pupil or accommodation. Its toxicity is only half that of cocain. Its solutions can be sterilized by heat. In short, alypin, stovain, and eucain lactate are practically therapeutical equivalents and may be employed almost indifferently.

Novocain, in strong doses, has an anesthetic power as great as cocain without, however, causing any dilatation of the pupil, a property which becomes of importance when it is desired to render a glaucomatous eye anesthetic. Employed in such doses, novocain produces some little change in the epithelium of the cornea and conjunctiva, and retards the cicatrization of wounds. Interstitial injections of novocain are recommended in enucleation of the eye and in many other operations.

Summary.—From the foregoing it is seen that to-day we possess several interesting substitutes for cocain which are capable of rendering real service and which certainly deserve to be used more frequently than has hitherto been the case, even if they cannot replace the older anesthetic. In any case when brief anesthesia will suffice, alypin or stovain is indicated. In infiltration anesthesia, one may employ the same substances, combined in equal parts, together with cocain and a little adrenalin. Under the name **lusemin,** a mixture of cocain and adrenalin has been praised. Its formula is as follows:

Cocain hydrochlorid	0.75
Adrenalin hydrochlorid	0.005
Sterilized water	100.

This solution, pasteurized and preserved in ampoules, is likely to be of service in all operations in which hemorrhage is feared.

For the operation for cataract, cocain is clearly preferable, because of its greater anesthetic power and also because the slackening of the iris-sphincter produced by it allows of an easier delivery of the crystalline.

Cocain, employed with caution and in moderate doses, still remains the local anesthetic in common use. For him who recognizes its faults and knows how to avoid them, cocain renders inestimable service for inducing the local anesthesia necessary for all surgical interventions upon the eyeball or the eyelids. It is an established fact that it is useless to employ doses stronger than 2 or 3 per cent. in collyria. It is much better to repeat the instillations oftener, a proceeding which has the added advantages of compelling the surgeon to keep the patient under close attention and prevent the desiccation of the corneal epithelium. For intradermic, subcutaneous, or subconjunctival injections, 1 per cent. solutions only are used, or it may be combined with acoin, which has no appreciable toxicity, so that no complications need be feared.

Ocular Analgesics.

When cocain was discovered it was at first hoped that, in addition to rendering the eye insensible, it might also modify or suppress pain provoked by any pathological state of the cornea and conjunctiva. When this expectation was not fulfilled, a further search was made for substances that might act as powerful ocular analgesics.

Orthoform has been tried in the following maladies of the eye: relapsing ulcerations of the cornea, episcleritis, burns of the conjunctiva by chemical caustics, burns of the eyelids, etc. In a case of burn of the conjunctiva and cornea by liquid caustic potash, associated with violent pain, the application of orthoform ointment was at first, despite the use of cocain, followed by such intense smarting that the patient dreaded to make the application. At the same time, it was undoubted that marked analgesic action was brought about at the end of a few moments and that it lasted as long as the dressing was kept over the eye. As soon as the corneal epithelium was reproduced, much less pain was experienced from the application of the ointment. In a case of burn of the conjunctiva and edge of the lid from a particle of red-hot iron, the effect of orthoform, applied as a dressing, was most favorable. Several burns of the eyelids were treated with orthoform with equal success. It would be interesting to multiply these experiences, for the potent analgesic power of cocain is too fleeting in many of the cases, and the discovery of an analgesic of prolonged action would be a valuable ophthalmic conquest.

Anesthesin is a new analgesic of lasting powers that has been praised by E. Ritsert. It occurs in an impalpable powder, insoluble in water, but soluble in alcohol, ether, etc. It is soluble in oil to the extent of 2 per cent. to 3 per cent. In ophthalmic practice, therefore, it should be utilized in an ointment or in oily solution.

Acoin and dionin are, without doubt, profound anal-

gesics. The word "analgesic" may appear to be a pleonasm, since anesthesia generally implies analgesia. But one does not succeed by instillations of cocain in calming the deep and violent pain of iridocyclitis, of glaucoma, of episcleritis, etc. For that matter, to the pain may be added insomnia. Such pain, however, can often be calmed by applications of dionin. On the other hand, dionin produces little if any anesthesia. An eye freed from deep pain by dionin is sensitive to pricks, nips, or to cauterization by silver nitrate.

As regards the action of cocain, the exact contrary is the case. Moreover, cocain stimulates the psychomotor centers at the same time that it extinguishes the peripheral sensibility, while dionin, like almost all the derivatives of morphin, has, on the contrary, a sedative narcotic action of a very marked description. Morphin itself is a well-known analgesic, without possessing the least anesthetic properties, unless it be administered in strong enough doses to provoke lethargy. Indeed, it is not uncommon to observe in those under the influence of morphin a certain degree of cutaneous hyperesthesia and of cerebral excitation, together with insensibility to pain or analgesia.

It will therefore be evident that analgesics are not always anesthetics, and *vice versa*. An anesthetic allows operations to be performed without pain, while an analgesic suppresses a preexisting pain without dulling the sensibility.

Concentrated solutions of acoin, instilled into the eye of the rabbit, produce an anesthesia lasting for several days, but also a very lively irritation of the cornea and conjunctiva. Trolldenier has obtained interesting results from the use of diluted solutions. According to the concentration of the solution, anesthesia is produced at once or after a few moments, and it lasts for a longer or shorter time. An anesthesia of duration depending upon the strength of the solution may thereby be obtained in accord-

ance with what is required. This point is brought out in the following table:

1 to 1,000 produces anesthesia lasting	15 minutes.
1 to 400 produces anesthesia lasting	30 minutes.
1 to 200 produces anesthesia lasting	60 minutes.
1 to 100 produces anesthesia lasting	70 to 80 minutes.
1 to 40 produces anesthesia lasting	more than a day.

Acoin has been frequently used by interstitial injections, according to Schleich's method, to obtain local anesthesia by infiltration. Instead of cocain, acoin was employed after the following formula:

Acoin	0.10
Sodium chlorid	0.80
Distilled water	100.00

The above solution was injected into the skin in accordance with the precepts of Schleich. The puncture and the formation of the first *blister* were alone painful, but after that, if care were taken to inject slowly, pain was minimal. The vesicle, formed in this way, is insensitive in its whole extent. By means of additional injections, the surface of infiltration may be enlarged as much as desired, without provoking any complaint. There are no consecutive pains, but a red aureole, with slight swelling, is produced around the infiltrated region.

The duration of the anesthesia was considerably longer than with the cocain-morphin solution recommended by Schleich. It was maintained in the same region for forty to fifty minutes after the injection, and then the zone of insensibility slowly approached the injected territory. Experience has shown that acoin is much less toxic than cocain, and that it may be employed in injections of a much less concentrated solution. Its action is of long duration. The caustic effect of concentrated solutions of acoin forbids their employment.

Preparation of Solutions of Acoin.—These solutions

are prepared by adding the required volume of acoin to water freshly distilled. Solution is complete in a moment's time. If we do not employ water that has been recently distilled and is absolutely pure, or if the liquid is mixed in a glass receptacle whose reaction is alkaline, an opalescent solution will be the result, since the base acoin is precipitated by the least trace of an alkaline substance (soap, etc.). The bottle intended to contain the solution must, accordingly, be rinsed with nitric acid and then, before it is used, with distilled water. Warm water must not be used to make the solutions, and a solution of acoin must not be diluted with cold water.

Thanks to acoin, we now are in a position to render **subconjunctival injections** almost completely painless. A few drops of 1 per cent acoin, prepared according to the foregoing instructions, are added to the solution to be injected. The dose of acoin will vary with the strength of the latter. Thus, to inject beneath the conjunctiva a syringeful of 4 per cent. sodium chlorid, two divisions of the syringe must be added, and for an injection of 6 per cent. three or four divisions. In most cases the pain then amounts almost to nothing, provided the conjunctiva has been properly cocainized previously and the puncture has been made with delicacy. Even injections of sodium chlorid of from 10 to 20 per cent. which are ordinarily excruciatingly painful, but which are called for in the treatment of detachment of the retina, may be rendered almost painless if enough acoin be added to them. Under such circumstances almost as much acoin must be added as saline is to be injected. The solution becomes milky, owing to precipitation of the acoin, and the injection must be made without delay in order to avoid blocking of the needle of the instrument. Alcohol causes the cloudiness of the solution to disappear, while at the same time it adds to the lymphagogic properties of the sodium chlorid, although it provokes a smarting of brief duration when injected.

Injections of mercury cyanid are rendered equally painless by acoin. To inject painlessly a syringe half full of a 1 : 5,000 solution, three or four divisions of acoin must be added to it; for a solution of 1 : 1,000 we must naturally use more acoin, perhaps about one-third of the solution for injection. For half a minute the patient complains of moderate pain, and then succeeds the analgesic period, which lasts for a longer or shorter time according to the dose of acoin which has been employed and also according to the individual susceptibility of the patient. It sometimes happens that the pain ends by making itself felt during the night or not even until the next day. The patient should be warned of this possibility, since he will then feel less uneasiness about it. It is curious to observe that acoin, even when precipitated from its solutions, keeps its analgesic qualities.

In man, therefore, acoin possesses a very marked anesthetic action, which lasts much longer (three and four hours and more) than that produced by cocain. As a matter of fact, cocain incorporated with liquids injected beneath the skin or the conjunctiva renders the injections painless only for about half an hour, more or less. It is not possible to explain why acoin has no action upon the cornea of man, while it has so deep and durable an effect upon that of the rabbit. Doubtless, the epithelial investment of the human eye does not allow the same solutions of acoin to penetrate, but if there is epithelial desquamation, the acoin may penetrate and produce analgesia. Acting upon this idea, the author has tried the effect of acoin ointment in those extremely painful cases of superficial burn of the conjunctiva or cornea by chemical agents. Pflugk, of Dresden, has recommended a 1 per cent. oily solution of acoin as possessing remarkable analgesic properties (*Klin. Monatsbl. f. Augenheilkunde*, December, 1907). It is likely that this interesting anesthetic, employed in ointment form, will prove to be of service in ocular therapeutics. Thanks to the 1 per cent. oily collyrium of acoin,

of which the application may be repeated as often as is necessary without objection, Pflugk has produced in upward of a hundred patients a durable analgesia.

Acoin has the advantage of not paralyzing accommodation and of not dilating the pupil, as does cocain; it does not produce alterations in the corneal epithelium, and its application is painless. The analgesic action of the collyrium of acoin has also the great advantage of calming almost instantaneously the pronounced pain provoked by powdered dionin. It is merely necessary to allow three or four drops of acoin to flow over the cornea, and after a few seconds pain ceases, provided, of course, that all the affected parts have come into contact with the collyrium.

Pflugk has never observed the least inconvenience from the use of acoin, the harmlessness of which has been recognized by all authors. The pains have sometimes disappeared for twelve to twenty-four hours in wounds of the eye, iritis, etc., and inasmuch as the instillations are practically painless, they can be repeated as often as may be necessary. *It is important to keep solutions of acoin in the dark*, since they are altered by light.

Spindler, and, after him, Krantz, have showed that by combining acoin and cocain a much longer anesthesia can be obtained in such operations as strabismus, enucleation, and removal of the lacrimal sac. The addition of a little adrenalin is also recommended by Krantz on the ground that it augments the anesthesia, while diminishing the hemorrhage. Although acoin combined with cocain constitutes a mixture of little toxic property, yet nausea and nocturnal agitation have sometimes been observed.

Orthoform has a very durable analgesic action in burns of the eye, but its application is painful. Acoin is also painful but much less so, and the employment of acoin oil is facilitated by the preliminary use of cocain. The deep pains resulting from iritis, iridochoroiditis, glaucoma, and so forth, may also be relieved, often completely, by the quite

recent discovery of the powerful analgesic properties possessed by dionin (Darier). Doubtless the chemists will eventually find new products of a less painful and more active action, which will allow us to suppress the superficial pain resulting from all kinds of conjunctivitis and keratitis. Perhaps we shall finally be in possession of a special group of ocular analgesics, endowed with powerful and durable properties of inducing profound insensibility.

Sodium salicylate, given in the dose of 3 to 6 grms. daily, was, until the last few years, regarded almost as a specific in rheumatic affections of the eye. But it has serious drawbacks, such as gastric disturbances, ringing in the ears, and hallucinations. These tend to render its employment difficult in some patients. These inconveniences are largely obviated by intravenous injections.

Aspirin, which exerts a much more marked and more rapid action upon the painful element, has to-day replaced in many cases sodium salicylate. Administered in doses of 3 to 4 grms. a day, its effect is remarkable whenever it is given in an affection of truly rheumatic origin.

Quinin is employed more particularly in neuralgic or malarial affections. Many cases of keratitis, however, are benefited from its administration.

Antipyrin has a prompt but unfortunately very fugacious action (3 to 4 grms. a day).

Pyrenol, given in a dose of 2 to 4 grms. at night, acts almost in the same way as antipyrin.

Pyramidon possesses a more marked and more lasting action (3 to 4 cachets of 30 to 0.50 a day).

Phenacetin is sometimes used to combat a violent ocular pain, the nature of which is badly defined. The following is a useful formula:

Phenacetin	0.30
Antipyrin	0.50
Caffein	0.20

One to three cachets containing the above powder to be taken every day.

The disadvantages of general analgesics is that they fatigue the digestive canal and disturb the nervous system of the patient, who needs all his vitality to combat a malady, the course of which is often prolonged. Morphin injections, so valuable on many occasions, have the danger of the possible production of morphinomania.[1] It is thus especially desirable to discover local analgesics of profound and prolonged action.

Marked relief of ocular pain may often be brought about by local applications, hot compresses and alcohol dressings. They should always be tried, and are usually much appreciated by patients.

The Deep Analgesic Action of Dionin.—The following account shows how the chances of experiment pointed the road to the discovery of profound local analgesics. A woman presented herself affected by a very acute and painful form of rheumatic iritis, which allowed her no sleep at night. Despite the atropin that had been used for several days, the pupil was not dilated, photophobia was present, and the eye was congested. Atropin, applied several times during an hour, remained without effect. In order to facilitate the action of atropin, a little powdered dionin was placed in the conjunctival culdesac. The patient was at first alarmed by a violent pain, followed by a kind of numbness of the eye, and a pronounced difficulty in moving the globe, which was swollen and very edematous. Two leeches were applied to the temple in order to reduce congestion. An hour later the pupil was dilated *ad maximum*, and the patient felt much relieved. Two days afterward the patient returned with the statement that she had experienced no more pain and had passed two excellent nights without having found it necessary to take any sodium salicylate. Since this experience, numberless other cases have confirmed these results.

The pain of glaucoma is also in many instances calmed

[1] Injections of morphin may often be advantageously replaced by injections into the temple of 0.03 to 0.04 of dionin.

rapidly by dionin, momentarily or permanently. Simi has related three cases of glaucoma, accompanied by violent pain, which was rapidly calmed by a 6 per cent. solution of dionin. One of these patients had suffered so much pain that he meditated suicide. In a case of hemorrhagic glaucoma with violent pain, for the relief of which enucleation had been proposed, A. Terson had the good fortune to see the pain cease once and permanently after dionin had been dropped into the eye several times. Königstein had a similar experience, and Gaupillat had a very good result from the subconjunctival injection of dionin in a very painful case of glaucoma.

In a case of panophthalmitis following infective ulceration of the cornea, which had reached the last extremity, the violent pain experienced by the patient in both eye and head disappeared after the first application of dionin. The eye was eviscerated with the curet, and recovery promptly ensued with the formation of a good stump.

In vascular keratitis, accompanied by violent pain and intense photophobia, the latter symptoms often disappear quickly after the application of dionin. In several children affected with pustular keratitis with photophobia, after the application of dionin most of the patients opened their eyes better. The same remark applied to cases of acute parenchymatous keratitis associated with photophobia.

Rheumatic episcleritis often sets up extremely violent crises of pain. Such was the case with a patient confined to her couch for more than two months by rheumatoid arthritis. She suffered from episcleritis with lively pain, which often seized her in the middle of the night and lasted for two hours or longer. Despite the administration of sodium salicylate, the pains and also the episcleritis had persisted for a week. Powdered dionin was then applied to the more painful eye. An alarming chemosis resulted from the application, but the next day all pain

had disappeared. The pain was held in check for several days, although the scleral infiltration was little modified.

It may also be added that if seen in the actual development of an episcleritis, the physician may not infrequently put a stop to the further progress of the ailment by dionin.

Dionin, however, is not the only alkaloid that acts as an ocular analgesic. In fact, peronin was the first remedy used by Wolffberg, who followed in the footsteps of Buffalini.

Peronin, a derivative of morphin, also sets up chemosis, but its slight solubility causes it to act for a long time in the eye much as a foreign body which, instead of calming pain, actually produces it. On the other hand, this insolubility allows peronin powder to be employed instead of boric acid for practising massage or *ponçage* in cases of trachomatous conjunctivitis. In this manner one obtains a direct mechanical action upon the infiltrated tissues and an energetic lymphatic detersion which afterward allows the salts of silver or copper to act in a deeper and more marked manner.

Marquèz, of Madrid, concludes from his study of **codein** that the hydrochlorid salt in a 5 per cent. solution, applied locally, produces effects analogous to those of dionin, although they are less marked. It may, therefore, render service in ocular therapeutics.

Heroin, which is a derivative of morphin, has not yielded very convincing results, likely because of its slight solubility. The hydrochlorid is more soluble, but it is more liable to be accompanied by nausea.

As to **morphin** itself, it also provokes marked chemosis and a certain amount of analgesia. But in one case symptoms of intoxication were observed—cold sweats, lipothemia, and vomiting lasting for two or three hours. With dionin, however, such complications have never been seen.

Solutions of dionin may be injected beneath the conjunctiva with the same analgesic effect as regards the eye. It is certain that a hypodermic injection of dionin has also

a very powerful sedative effect. But there are many patients who, while they refuse to allow injections to be made, have no objection to a little dionin being placed in the conjunctival sac, especially after cocainization.

Wolffberg, without insisting upon the profoundly analgesic properties of dionin, noticed, however, that after injuries the patients felt greatly relieved by the application of dionin.

Schidlowsky (*Thèse de St. Pétersbourg*, 1907) found that instillations of a 1 per cent. solution of **adonidin** produces at the end of twenty-five or thirty minutes an anesthesia lasting for two to four hours. This is accompanied by a sensation of smarting, of foreign bodies, rainbows around lights, a bitter taste in the mouth, headache, sneezing, and coughing. There is also provoked miosis without appreciable effect upon accommodation. In glaucoma, iritis, and keratitis, adonidin causes the pain to disappear, and, as a rule, it does not recur. The remedy, moreover, exercises a favorable action upon the disease itself.

CHAPTER XII.

VASODILATORS. VASOCONSTRICTORS.

Vasodilators.

Dionin possesses not only a profound and durable analgesic power, but it also has a very favorable action upon the morbid process itself. It facilitates dilatation of the pupil when the mydriatic action appears slowly under the action of atropin; it hastens the resolution of pupillary exudations and the resorption of corneal infiltrations; and, lastly, it reduces tension in cases of glaucoma.

While therapeutic experimentation has not explained precisely how dionin acts, it has at least shown its importance as a remedy that hastens the nutritive changes and facilitates the resorption of pathological infiltrations, no matter what their exact nature. It exerts upon the eye a vasodilator action such as is possessed by no other known agent. This dilatation bears not only upon the blood vessels, but even to a greater extent upon the lymphatics, the caliber of which may under its influence increase tenfold.

The application of dionin to an eye produces at first a marked sense of burning and then a sensation of tension in the orbit and forehead, with sometimes a little headache. All their symptoms increase with the strength of the solutions used. Sometimes there is produced a sensation as of a foreign body in the eye, of difficulty in the movements of the globe, a kind of numbness with a soft heat, and an analgesia, more or less pronounced according to the individual and according to the degree of the chemosis. If the eye be kept closed or protected by a dressing, there will be little or no sneezing.

In subconjunctival ecchymoses, if a little dionin be applied to the conjunctival sac the day after their appearance, more or less considerable chemosis will speedily result. It is an important fact that if the hemorrhage be quite recent, the conjunctival infiltration takes on a rosy color instead of being clear and transparent as is usual with the chemosis produced by dionin. The reason is that the serosity infiltrated in the lymphatic spaces has taken up the sanguineous exudation. This exudation, during the course of its resorption, carries with it the coloring matters of the blood, perhaps dissolves the altered red corpuscles, reanimates the leukocytes, and all trace of hemorrhage soon disappears.

It may happen that dionin exercises its lymphagogic powers little or not at all, and in such an event chemosis is scarcely or not at all present. Under these circumstances the excitation to the resorption of superficial infiltrations is less. In order to arrive at the desired result, a syringeful of artificial serum must then be injected beneath the conjunctiva.

By Haitz it has also been proposed to hasten the resorption of peribulbar ecchymoses by the subconjunctival injection of sodium chlorid. Hemorrhages into the anterior chamber show a tendency to more rapid absorption under the influence of dionin (Wolffberg).

In all cases, from a therapeutical point of view, the action of dionin has been constantly favorable in conjunctivitis. The considerable afflux of blood and serosity provokes what Wolffberg has so well described as a "lymphatic inundation" (**Lymphuberschwemmung**), the detersive action of which is incontestable. The application of any local remedy whatever has an effect much more marked after this lymphatic lavage. It would appear also that the pain produced by cauterization lasts a shorter time. This is certain, *viz.*, that the sedative effect of dionin manifests itself by a better night and sounder sleep. It is particularly in corneal infiltrations that we can appreciate the lymph-

agogic and eutrophic action of dionin. In slight cases it has even a curative action, which should render the greatest serices.

The remarkable action produced by dionin upon the cornea shows itself at first by a more brilliant luster of that membrane, which appears to be more transparent, as it is in reality, since the sight may improve by one or two points in the course of a few hours. As a matter of fact, however, this improvement is noticed only when the visual acuity has been lowered by a slight and quite recent opacity of the cornea.

In simple contusions, accompanied by a slight corneal cloudiness, more or less diffused or more or less localized, liable to be mistaken for a commencing parenchymatous keratitis, dionin may produce a notable clearing of the cornea and improvement of the sight. This may come about so quickly that the resolutive action of dionin cannot be doubted in this case. It is the same as regards recent infiltrations of the cornea—often infective infiltrations—caused by slight scratches, foreign bodies, etc.

These different observations may be considered physiological experiences which demonstrate the peculiar action of dionin.

In the first stages of parenchymatous keratitis dionin has a very appreciable effect, but, unfortunately, this action is of brief duration. In fact, at the end of a few days the action of dionin ceases. But it has nevertheless produced in this short space of time a therapeutic effect that cannot be obtained with any other local remedy, unless it be with subconjunctival injections of sodium chlorid. The detergent action of dionin, which has flushed all the lymphatic territory of the conjunctiva, prepares the way, as it were, for the action of subconjunctival injections. The two methods of treatment, by well-devised alternations, strengthen one another.

It is not reasonable to expect to obtain the clarification of old-standing leukomata by means of dionin, but in

some instances an appreciable improvement in sight has been noticed. In such cases probably the nebulæ were very slight and encroached but little upon the pupil.

In abscesses and ulcers of the cornea the application of a little powdered dionin to the affected surface gives good results by stimulating the nutrition of the cornea and the easier regeneration of the epithelium, without it being possible to speak of an antiseptic action in the proper sense of the word. In phlyctenular keratitis, strumous vascular keratitis, and even in trachomatous pannus, dionin is able to render signal service both by its analgesic and by its lymphagog powers.

In certain subconjunctival or episcleral infiltrations, when taken at the beginning, the lymphagog action of dionin is found to be most beneficial. Even better effects may be looked for when the redness and swelling have been present for not longer than two or three days, as dionin then provokes a more pronounced chemosis.

The remarkable effect of dionin in iritis is well known. In this disease it acts as an analgesic, accelerates absorption of exudations, and dilates the pupil. The action of dionin in glaucoma is further studied in the chapter on this affection.

Dionin should hasten the clearing of the pupillary field after the operation for cataract or discission of the crystalline in myopes, although in order to avoid the patient's becoming accustomed to dionin, the remedy should be applied intermittently.

In choroiditis, retinitis, and opacities of the vitreous humor a notable improvement may often be observed after a few instillations of dionin (Graefe, Wicherkiewicz, Andogski), but, as a rule, the improvement is transitory, and the best results will follow an alternation of dionin and subconjunctival injections of sodium chlorid. In a case of retrobulbar neuritis, with very marked central scotoma, due to exposure to cold, the vision improved so rapidly that one could only conclude that the result was due to dionin.

The remedy may act most beneficially upon morbid processes on the road to regression. Thus, Gottschalk relates a case of retrobulbar neuritis in which dionin immediately produced a lasting improvement in sight and in the perception of colors. The patient was a woman of thirty-two years who presented dyschromatopsia and contraction of the visual field, along with a cloudy aspect of the optic papilla. The condition was not due to cold. Sight began to improve several hours after the chemosis produced by dionin had made its appearance.

In purulent ophthalmia, with swollen and indurated eyelids, in conjunctivitis and keratitis with diphtheritic or pseudomembranes, dionin has been useful by setting up a lacrimation and a lymphatic infiltration, which diminishes in several hours the induration of the eyelids and detaches the false membranes. The lymphagog action of dionin in these cases entails an interstitial flushing of the tissues, with an abundant elimination of toxins and microbes.

In consequence of its various and curious properties, therefore, the therapeutic indications of dionin are most diverse. It is, in fact, a powerful stimulant, a lymphagog, a resolutive, and possesses, besides, direct and indirect antiseptic properties due to the afflux of liquids and to increase in phagocytic action. Lastly, in many cases dionin is a powerful analgesic. To-day dionin has become an agent indispensable in ophthalmology, more valuable under many circumstances than cocain itself.

Dionin has some disadvantages. For example, its application is very painful, and it provokes watering of the eye, sneezing, and more or less intense chemosis. But this reaction is harmless and is exactly what the surgeon desires for the good of the patient. If the reaction is very violent, an occlusive dressing may be applied, and when the latter is removed next day, it is easy to convince the patient of the pronounced improvement that has taken place in the morbid process.

Dionin is the best physiological antiseptic. After the operation for cataract Wolffberg found in dionin a good antiseptic, as well as a means of hastening cicatrization of the wound. But it is preferable to reserve the employment of dionin for cases in which the cure is not proceeding normally. If there is the least ciliary hyperemia, the least secretion, and especially any infiltration of the wound, hypopyon, or hyphema, dionin should be applied in powder. In this way the galvanocautery, subconjunctival injections, or serotherapy may sometimes be avoided. In those who have been operated upon for cataract, there should be the avoidance of violent sneezing for fear of reopening the wound.

After difficult extraction of a foreign body from the cornea, a collyrium of dionin and mercury cyanid will prevent secondary infection and hasten the reproduction of the epithelium, and thereby often prevent traumatic keratalgia.

Method of Using Dionin.—Every consulting-room and every clinic should be provided with a stock solution of 5 per cent dionin:

Dionin	5
Distilled water	100

The application of powdered dionin provokes sharp pain. Exceptionally, this means may be adopted when the 5 per cent. solution remains without effect, and when one does not fear to set up violent reactional phenomena, or when the latter are indicated and their revulsive action is likely to do good.

It is advisable never to prescribe dionin for home use before having determined the particular susceptibility of the patient. In cases in which the reaction to the drug is violent, unless properly warned, the patient may entirely cease treatment. On the other hand, if he has demonstrated to him the presence of chemosis and explained to him its utility, he will be reassured. If the reaction is very violent the patient should not be allowed to leave with-

out an occlusive or, rather, with an alcohol dressing. These applications augment and widen the vasodilator action of the dionin upon the lids and the periorbital tissues.

The first time that dionin is employed it is prudent to apply a preliminary drop of cocain, in order to lessen the discomfort resulting from the application. A drop of the 5 per cent. dionin is then put into the lower culde-sac, while the patient turns his eye strongly upward. In this way the cornea scarcely comes into contact with the liquid, and the smarting is much less lively, the cornea being infinitely more sensitive than the conjunctiva. In aged persons, as well as in lymphatic subjects, a tiny drop should be applied at first and the dose should not be increased until several minutes have elapsed, if the effect has not meanwhile been produced.

In patients with a good circulation the lymphagogic action of dionin is much less pronounced, and there are even cases in which true chemosis cannot be produced; and at most there is a slight elevation of the conjunctiva with dilatation of the bloodvessels, accompanied by a brilliant luster of the cornea, which is never lacking.

The first application of dionin always has a much more marked effect than a second made on the following day. But if several days be allowed to elapse between the two instillations, the reaction may be the same. It must not be forgotten, therefore, that the eye speedily becomes accustomed to dionin.

When it is ascertained how the patient reacts, the indicated formula may be prescribed for use at home.

In slight scratches or injuries of the cornea, one or two drops of the following formula should be ordered to be dropped into the injured eye five or six times a day:

Dionin	1
Cocain hydrochlorid	1
Mercury cyanid (1/1,500)	100

When the wound is already infected, the strength of the mercury cyanid solution should be increased to

1/1,000 and the instillations should be made every hour or even every half hour.

When iritis is present or threatened, atropin should be added to the collyrium in amount proportional to the severity of the iritis:

Dionin	1
Cocain hydrochlorid	1
Atropin sulphate	0.2 to 0.5
Distilled water (or cyanid solution)	100

The instillations to be made more or less frequently according to the indications.

When miosis is desired, it is easy to mix eserin or pilocarpin with the collyrium according to the precise indications:

Dionin	1
Cocain hydrochlorid	1
Pilocarpin hydrochlorid	0.3 to 2
Distilled water (or cyanid solution)	100

If the case is one of glaucoma, cocain must be most sedulously avoided:

Pilocarpin hydrochlorid	1
Eserin sulphate	0.5
Dionin	2
Distilled water	100

One drop to be applied to the affected eye five or six times a day.

This collyrium has the advantage of often suppressing the painful phenomena of glaucoma at the same time that it reduces intraocular tension, provokes contraction of the pupil, and hastens clearing of the cornea. It is most useful as a preliminary to operation in all forms in which the irritation is too violent to allow of immediate surgical treatment. But it must not be forgotten that the action of dionin rapidly becomes weakened. It is

therefore often advisable to restrict its application to the days on which the patient sees the physician, the idea being that after a period of rest the dionin will once again provoke a salutary reaction, which is scarcely possible when the patient has been in the habit of using dionin for himself every day.

Vasoconstrictors.

Adrenalin.—While dionin has a most powerful vasodilator and lymphagogic action upon the eye, adrenalin is a vasoconstrictor which may be equally useful, but in the contrary sense. The intravenous injection of the extract of the suprarenal capsule has a powerful vasoconstrictor action, which is mainfested mainly upon the smallest vessels. An increase in the blood-pressure results from this effect. The application of suprarenal capsule to the mucous membranes sets up a very pronounced local ischemia.

Preparations of suprarenal extract have become well-determined and exactly dosable chemical agents. In ophthalmology we employ, as a rule, a 1 : 1,000 solution of adrenalin hydrochlorid, a single drop of which is sufficient to produce a very marked therapeutic effect. It is, indeed, so pronounced that if it is indicated to use the remedy several times a day, weaker solutions, for example 1 : 5,000, must be employed, since large doses of adrenalin may occasion serious complications.

Reichert claims that in adrenalin we have a true antidote to opium and morphin. Adrenalin is equally indicated to meet the collapse that may come on during chloroform narcosis, as well as in adynamic conditions characterized by a feeble and very slow pulse.

The effect of cocain is exaggerated by adrenalin, which renders it both more toxic and also more vasoconstrictive. It exalts also the mydriatic and the toxic effect of atropin. Eserin combined with adrenalin acquires

a constrictor power as regards the sphincter iris much more marked than when used alone.

A drop of 1:1,000 adrenalin, instilled upon the normal conjunctiva, sets up in two or three minutes intense anemia of the surface of the eyeball, so that hardly a single conjunctival vessel is visible. The sclera becomes of a shining white color, and the livid hue assumed by the eye may be likened to porcelain. The anemia lasts from one to two hours, according to the individual and the dose employed. When applied to diseased eyes, this effect lasts a shorter time the more the eye is congested. But there is no hyperemia, no matter how intense, which cannot be subdued for some minutes if the instillations of adrenalin are repeated two or three times. No agent at present known to us possesses a power of producing anemia so marked as adrenalin.

Thanks to this powerful vasoconstrictor action, in many cases interventions which otherwise would be very difficult and very troublesome can be carried out. The fact is well known that cocain has little or, indeed, according to some authors, no action upon eyes that are markedly hyperemic. In such cases a sufficient anesthesia may be sometimes obtained by the alternative or simultaneous instillation of cocain and adrenalin twice or thrice. By adopting this plan iridectomy may be performed in cases of inflammatory glaucoma that would otherwise be impossible without chloroform. Under these circumstances eserin must also be applied for the purpose of counteracting the mydriatic effect of cocain.

The same methods render almost painless the application of the cautery to an inflamed sclera, conjunctiva, or tarsal cartilage. The same remark applies to scarifications and many other operations upon the anterior segment of the eye.

When these interventions are likely to be accompanied by bleeding, the hemorrhage is much less abundant in eyes under the influence of adrenalin—a slight oozing is all that

is likely to occur. The vasoconstrictor action of adrenalin has been turned to advantage in arresting or diminishing the hemorrhage that may be produced by operations for chalazion, etc. This hemostasis may be useful in many cases. It may, however, be succeeded by reactional hemorrhages. It would perhaps be advisable in these cases not to discontinue the instillations of adrenalin, in order to avoid too rapid a reaction.

Adrenalin associated with stovain and cocain employed in interstitial injections facilitates greatly the performance of such operations as strabismus, extirpation of the lacrimal sac, enucleation, etc., although in these cases very dilute solutions of adrenalin, 1:10,000, in quantities not exceeding 1 c.c., should be employed. In a dental case in which a 1:1,000 solution of adrenalin was injected, necrosis of the gums, sphacelus of the upper jaw, and death resulted! In two cases of extirpation of the lacrimal sac Stargardt after injection of eight drops of suprarenin, observed necrosis of the parts. Such accidents will not occur if the following formula is adopted:

Cocain and stovain, of each	0.05	
Adrenalin chlorid, 1:1,000.....	20	drops.
Distilled water.....	9.0	

So far adrenalin has not been known to be a specific. There is no affection which can be cured by the exclusive employment of this medicament. On the other hand, its indications are numerous, and it is capable of rendering service in many ocular affections. It is a physiologic reagent that should always be at hand.

In conjunctivitis and pustular keratitis adrenalin, used before the yellow ointment, shortens notably the course of the malady. In secretory affections of the eye—purulent, catarrhal, granular, or other form of conjunctivitis—adrenalin, and cocain, without having any direct action upon the pathologic process itself, brings about a marked reduction in the purulent or catarrhal discharge. The

action of caustic, manifested upon elements at once anemic and anesthetic, manifests itself with double intensity, although with less pain.

This action of **cocarenalin**[1] is mose useful in lavage-friction of granulations with sublimate. Under these circumstances we are not embarrassed by oozing which often hides the operative field and neutralizes the caustic; the hemorrhage which appears later produces an interstitial lavage, and thus removes organic remains.

Cocarenalin injected into the lacrimal sac renders the anesthesia more profound and the passage of a probe easier, while eliminating hemorrhages. If after, or even without, catheterization of the canal, an injection of cocarenalin is given and the solution escapes by the nose, patients notice a marked improvement in the watering of the eye for several hours or days.

In the treatment of ulcers of the cornea adrenalin should be employed only with precaution. In general, it is contraindicated in almost all ulcers. During the period of repair, it hinders vascularization and may provoke a relapse. On the contrary, when the ulcer has healed, and nothing is left but a vascular pannus which is slow in disappearing, adrenalin will play an important rôle in causing the disappearance of the vascular condition. The salutary action of adrenalin as regards every kind of pannus —granular, tuberculous, and gouty—has been insisted upon by Zimmermann.

In spring catarrh, Perret has had occasion to prove, after the frequently repeated application of adrenalin, not only a momentary improvement in the affection, but also a complete disappearance of the pericorneal lesions, to-

[1] A drop of the following formula renders the conjunctiva anemic, and causes all redness of the eyeball to disappear:

Cocain hydrochlorid	0.30.	
Adrenalin, 1:1,000	20	drops
Sterilized water	9.0.	

This **cocarenalin** is useful to artistes who must appear in public with an inflamed eye, since by its application the eye becomes shining white and appears larger, without the pupil being at the same time unduly dilated.

gether with cessation of all the symptoms incidental to this affection. He concludes that in the extract of suprarenal capsule we possess a remedy easy to use, nontoxic, and free from pain, which employed in instillations has an almost certain action in an affection scarcely influenced by other methods of treatment. In relapsing cases it is always easy to recommence the treatment.

Since Perret's statement, we have treated many cases of spring catarrh, and adrenalin has always shown itself to be the most valuable and active palliative at our disposal. In slight cases its action is remarkable—redness, secretion, and watering disappear, while the pericorneal infiltrations diminish and even disappear. It is important, however, that, except during the winter, the patient should continue to use the collyrium, *viz.*, one drop of adrenalin, 1 : 5,000, every two hours. In graver forms associated with a papillomatous state of the tarsal cartilages, without being curative, adrenalin invariably has a remarkably emollient action. It must then be employed every year with regularity but with prudence, since Feller had a case in which a man, affected with conjunctivitis, applied adrenalin daily for nineteen months (commercial solution diluted with half water), and who soon showed signs of intoxication, such as palpitations, dyspnea on effort, tachycardia, arterial hypertension, polyuria, subicteric color of the conjunctiva, and rapid gain of flesh.

The author discontinued the adrenalin and put the patient on a suitable diet, and the symptoms disappeared without other treatment.

The toxic action of adrenalin upon the heart demands that its therapeutic employment should be undertaken with prudence.

In some cases of glaucoma in which vision continues to fall despite iridectomy, the intraocular tension being always raised despite the repeated instillation of eserin and pilocarpin, the action of adrenalin may be added to

that of the two miotics with the result that tension sometimes becomes lowered in a pronounced and prolonged way. One or two hours after the application of the collyrium, patients may experience an improvement in sight and a sensation of feeling better. Adrenalin is in no sense a specific against glaucoma, but its use, combined with pilocarpin and eserin, as in the following formula, may be of service in some cases:

Pilocarpin hydrochlorid	0.10
Eserin sulphate	0.05
Adrenalin, 1 : 1,000	2.00
Distilled water	8.00

To be used, according to the indications, several times a day.

With regard to the foregoing collyrium, it is prudent to make the first instillations oneself, so as to ascertain the duration and the intensity of the vasoconstriction. Indeed, for the first few days treatment should be closely watched, since it sometimes happens that unduly strong doses of adrenalin provoke a reaction which manifests itself under the guise of a marked elevation of tension (reactional hyperemia). Applied at intervals suited to the exact pathologic condition and to the method of reaction of each patient, this collyrium is capable of rendering signal service; but badly administered, it may give rise to serious inconveniences.

The general rule must not be forgotten, namely, that glaucoma should be operated on as quickly as possible if the patient is to keep good visual acuity.

Grandclément, of Lyons, has found such benefit from adrenalin in glaucoma that he is convinced that henceforth most cases of glaucoma, and even of secondary glaucoma, can be cured without operation, thanks to adrenalin. But in order to obtain this result attention must be paid to the following points: 1. The glaucoma must be so recent as not to have produced anatomic lesions; 2. adrenalin must be dropped into the eye every half-

hour until such time as the hypertension has ceased; 3. eserin must be used concurrently with adrenalin; and 4. the employment of the adrenalin must be diminished, then suspended, as soon as the tension is lowered.

From the standpoint of general therapeutics, it appears probable that the extract of suprarenal capsule will soon occupy an important place not only in ophthalmic practice, but much more in certain general maladies due to atony of the blood-vessels and lymphatics.

The intravenous injection of adrenalin causes contraction of all the muscles innervated by the sympathetic—mydriasis, protrusion of the eyeball, retraction of the third eyelid, and enlargement of the palpebral fissure. This action, which lasts no longer than one or two minutes, may pass unnoticed. Marked mydriasis is also induced by adrenalin when frequently applied to the eye in adequate doses.

Adrenalin acts directly upon the vessels of the iris and ciliary body, which it renders markedly anemic. From it results a notable slackening in the formation of the aqueous humor, as is shown by the following experiment: A subconjunctival injection of adrenalin, 0.001, is made in one eye, and in the other an injection of artificial serum. A quarter of an hour afterward, the aqueous humor is evacuated from each anterior chamber. Ten or fifteen minutes later, the anterior chamber of the eye treated with serum is reformed, the tension has become normal or even higher, and the aqueous humor is more albuminous than in the normal state. In the other eye, the adrenalin, on the contrary, has reduced the secretion of the aqueous humor to such a point that after thirty minutes the eye is still of low tension, and the humor does not contain as much albumin as in the normal state (Wessely). These purely experimental facts have a very interesting bearing upon treatment. It is possible, in fact, that in the very beginning of an iritis, adrenalin, in frequently repeated instillations, may prevent or check the evolution of the

pathologic changes as regards the ciliary processes. This is to some extent comparable with the effect of cold compresses.

Therapeutic experiment has shown in an almost constant manner that adrenalin lowers the intraocular tension in an appreciable way. But, until recently, no manometric observations had been undertaken to confirm clinical observation by experimental control. Wessely has now shown in the most precise way reduction in ocular tone, which is 3 mm. to 4 mm. lower than on the sound side, and that by means of most exact manometric mensuration.

Adrenalin, when used in strong doses or by subconjunctival injection, provokes very pronounced dilatation of the pupil, its action being directly upon the muscular cells or the ganglionic cells of the dilatator of the pupil.

Ethylaminoacetopyrocatechin is now prepared by synthesis. As the hydrochlorid salt, it occurs as a well-crystallized product, readily soluble in water. Its solutions, bitter to the tongue, induce a transitory insensibility of the tongue. This salt, called **"homorenon,"** is fifty times less toxic than the active substance of the suprarenal glands, and is devoid of harmful action upon the heart. It is well borne by individuals who are sensitive to suprarenal preparations.

Anterenol is the aminoethanolpyrocatechin, of which the hydrochlorid salt, soluble in water, has exactly the same action as the suprarenal glands, but it possesses the advantage of being two or three times less toxic than the latter.

CHAPTER XIII.

MYDRIATICS AND CYCLOPLEGICS. MIOTICS.

Mydriatics and Cycloplegics.

Atropin has been known since 1833. When dropped into the conjunctival sac it penetrates through the coats of the eye as far as the aqueous humor, where it is imbibed by the iris, of which it paralyzes, first, the sphincter and then the ciliary muscle, thereby suppressing the function of accommodation. It has been thought that this action takes place through the intermediary of the general circulation, but that obviously cannot be so, since the pupil of the other eye does not dilate.

The action of atropin is not limited to paralysis of the sphincter iridis, for if such were the case, paralysis of the oculomotor, which innervates the sphincter, should produce the same mydriasis. But that resulting from atropin is much more marked, and when the alkaloid is applied to an eye affected with paralysis of the third nerve, it produces an even greater dilatation of the pupil. At the same time as it paralyzes the sphincter, therefore, atropin stimulates the dilatator of the pupil.

Whenever it is necessary to keep the pupil widely dilated for a long time, as in iritis or deep keratitis, or when adhesions between iris and the anterior capsule of the lens must be prevented at all hazard, or when accommodation must be placed quite at rest, instillations of atropin, repeated two or three times a day, must always be prescribed. It is the remedy at once the most trustworthy and the easiest to manage. Atropin is ordered in a 1/2 per cent. solution, one drop of which must be placed in the eye two or three times a day.

Discretion must be exercised in the use of mydriatics,

all of which are very toxic. The first **symptoms of intoxication** are dryness of the throat, palpitation, vertigo, disturbances of sight, hallucinations, etc. In clinical work, it is advisable always to reckon with idiosyncrasies. For example, for home use weak solutions only should be prescribed, and the patient should be seen at the end of one or two days, because if mydriasis, which it is urgent to obtain as speedily as possible, has not yet been induced, the surgeon may then make more frequent instillations or may prescribe stronger solutions.

In cases in which mydriasis is extremely difficult to obtain, Fuchs recommends that a tiny crystal of atropin should be placed in the conjunctival sac. These intensive treatments, however, may cause phenomena of intoxication by the penetration of a large quantity of the alkaloid through the nasal canal into the nasopharyngeal mucous membrane. To avoid this complication, compression of the puncta has been recommended, but this is not always easy to carry out.

In case of intoxication by atropin, scopolamin, and other mydriatics, morphin should be at once injected. At the same time the stomach should be cleared by an emetic, milk should be given to drink, and 0.0003 of eserin may also be injected.

Dionin may augment mydriasis and facilitate the resorption of pupillary exudations. The action of mydriatics is also favored by hot applications or alcohol dressings.

Scopolamin, like hyoscin, which acts more energetically than atropin, renders great service in cases in which the latter fails to provoke an adequate dilatation of the pupil. The following is the formula to be recommended in such cases:

Scopolamin iodohydrate	0.2
Cocain hydrochlorid	2.0
Distilled water	100.0

One drop of this collyrium to be instilled three times a day. Its employment in children is contraindicated for fear of toxic accidents.

The addition of cocain enhances the effect of mydriatics —first, because it hastens resorption, and, then, because it acts directly upon the dilatator fibers of the iris and also upon the ciliary muscle itself.

What has been said with regard to the toxicity of atropin applies even more to scopolamin. Patients must therefore be watched carefully. In cases of iritis accompanied by high tension, scopolamin is less likely to be followed by glaucomatous accidents.

The prolonged employment of atropin sometimes sets up a follicular conjunctivitis, which is usually due to the solution having undergone changes.

Homatropin has upon the pupil an effect analogous to that of atropin with the difference that the action is of shorter duration. A 1 per cent. solution provokes in fifty minutes complete dilatation of the pupil, with paralysis of the accommodation, which does not pass away for twenty-four hours.

Homatropin is most useful in estimating the refraction of the eye, especially when a short mydriasis or cycloplegia only is indicated.

The powerful toxic action of **duboisin** precludes its extensive employment.

The hydrobromate of methyl-atropin is a valuable substitute for atropin. Employed as a 1 per cent. to 2 per cent. solution, methyl-atropin has the same action as the sulphate of atropin as regards the pupil and the accommodation. Applied as a single drop of 1/2 per cent. solution, the mydriasis may last somewhat longer than twenty-four hours, but the paralysis of accommodation, on the other hand, disappears in the course of a few hours. In feeble doses (one drop of a 1/5 per cent. combined with 2 per cent. cocain) it produces a very considerable dilatation of the pupil, with slight paresis of the accommodation, and what is important, a drop of eserin quickly brings the pupil to its normal state.

Atropin sulphate and scopolamin hydriodid are

practically the best mydriatics to use in the treatment of iritis and in every case in which synechiæ must be broken up or the pupil be kept widely dilated for a long time. They are also indicated when accommodation must be paralyzed for a certain length of time. On the other hand, methyl-atropin is useful when commencing iritis has to be recognized. If iritis be not present, as shown by wide and even dilatation of the pupil, the discomfort produced by the mydriasis will be much less than if sulphate of atropin has been employed. If iritis is really present, the instillations will be continued.

There is still a desideratum to be realized in the possession of a mydriatic the action of which shall be rapid and short, and which shall affect accommodation not at all. Ophthalmoscopic examinations are, in fact, much more complete and simple, especially for beginners, when the pupil is dilated. Practically, up to now **cocain** has been the agent currently employed to facilitate ophthalmoscopic examination, although the mydriasis produced by it was very inconstant, while the disturbance of accommodation was frequently very marked.

Ephedrin, which was introduced into ophthalmology some years ago in 10 per cent. solutions, gives rise to a painful irritation of the conjunctiva, but its mydriatic action is very pronounced and lasts for almost fourteen hours. The ciliary muscle is slightly paralyzed. Five per cent. solutions have no irritating action, and mydriasis is powerful but fleeting, since it does not last longer than three and one-half hours, and the power of accommodation shows little change (de Bourgon).

Mydrin (Merck) is a mixture of one part of homatropin with 100 parts of ephedrin, and it accordingly combines the respective properties of those two agents.

Eumydrin is fifty times less toxic than atropin. Its action upon the pupil is ten times less powerful than that of atropin. It may be of service when it is wished to dilate the pupil for twenty-four hours only.

Euphthalmin in 5 per cent. solution combined with cocain is likely the best drug to produce a mydriasis with rapid and short action, without notable effect upon accommodation.

Euphthalmin	5
Cocain hydrochlorid	2.4
Sterilized water	100

One or two drops of the above solution effects in thirty-five to fifty minutes a maximal dilatation of the pupil, which allows of easy ophthalmoscopic examination without notable change in sight.[1] Aside from slight dazzling, due to diffusion of the luminous rays penetrating through the dilated pupillary orifice, patients are, in fact, able to read without much difficulty the ordinary characters of a book or journal, and all discomfort has passed completely away two or three hours after it was first noticed. The same evening the eye treated by euphthalmin has always returned to its normal state. This agent can be strongly recommended in the doubtful cases in which we desire to determine whether true inflammation of the iris is present. By using atropin in a case of simple ciliary hyperemia, due to slight episcleritis, we impose upon the patient eight or ten days of paralysis of accommodation by applying atropin to his eye. This may be avoided by the use of euphthalmin without interfering with the proper diagnosis of true iritic inflammation.[2]

Miotics.

Eserin and pilocarpin are the principal miotics. They provoke a continued contraction of the sphincter of the iris and of the ciliary muscle, thus producing marked contraction of the pupil along with a spasm and even a contracture of accommodation.

[1] Mydriatics are absolutely contraindicated whenever intraocular tension is raised. Under these circumstances not even cocain should be used. The ophthalmoscopic examination must be made without artificial mydriasis.

[2] Cases of acute glaucoma, following the use of euphthalmin, have been reported by American observers.—THE EDITOR.

Eserin, more energetic than pilocarpin, also produces headache and a sensation of cephalic tension, and for this reason unless there be particular indications, pilocarpin should be selected. The latter keeps better, and applied as a 1 per cent. solution, has a sufficiently energetic action upon the pupil.

The action of miotics lasts a much shorter time than that of mydriatics. Hence, it is usually possible to dilate by atropin a pupil contracted by eserin, while it is impossible to contract by eserin a pupil which has been dilated by atropin.

By preference, we employ the salicylate of eserin, which if less active than the sulphate, is also less disagreeable. The salts of eserin, especially when in aqueous solution, are readily decomposed by light. But in oily solution eserin is both less irritating and less apt to alter with time.

The following may be prescribed:

Eserin salicylate	0.05
Sterilized water	5.0

or

Pilocarpin chlorid	0.10
Sterilized water	5.0

The water in the foregoing formulas may equally well be replaced by vaselin ointment.

The principal therapeutic rôle of miotics is to reduce intraocular tension in cases of glaucoma. They are also useful in iritis to replace atropin from time to time, so as to compel the muscular fibers of the iris to undergo, as it were, a species of salutary gymnastics.

CHAPTER XIV.

DRUGS MODIFYING CONJUNCTIVAL SECRETIONS.

The Silver Compounds.

Catarrhal or purulent secretions of the conjunctiva are most frequently provoked by the presence of micro-organisms, of dust, or of irritating chemical agents. The infective element is not always the same, but it appears to possess a specific importance. Agents capable of inhibiting the development of these infective elements, and at the same time having a stimulant and tonic action upon the cells, are to be found in the chief antiseptic and astringent local remedies such as the salts of silver, mercury, copper, zinc, and lead.

Antiseptics.—Since the discoveries of Pasteur and of Lister, antiseptics have acquired considerable importance in ocular therapeutics, more especially in operations.

Carbolic acid, which formerly was employed almost universally, has lost much of its importance in eye-work, since it is irritating and in feeble dose is not sufficiently antiseptic. Besides, it attacks the cutting edge of ophthalmic instruments.

Mercuric chlorid is still much used, although it is very irritating, and, like phenol, acts upon instruments.

For several years I have replaced sublimate by **mercury cyanid,** which is just as good an antiseptic, but much less irritating, and used as a 1 : 2,000 and 1 : 5,000 solution, devoid of deleterious action upon cutting instruments. These are the solutions commonly employed by me. In my hands, the cyanid has also replaced sublimate for hypodermic, intravenous, and subconjunctival injections.

The oxycyanid of mercury in practice presents no advantage over the cyanid, which is more stable, less

toxic, and easier to obtain. The oxycyanid, moreover, is difficult to obtain in a state of purity.

Astringents and antiseptic caustics merit the particular attention of the ophthalmologist.

Silver nitrate until lately has been recognized as the best local remedy for almost all the secretory affections of the conjunctiva. Alum, zinc, lead, and copper were substitutes only, although they sometimes had special indications. When the proper use of the silver salts is understood, the physician is able with one or other of them, by judiciously changing the strength of the solution, to obtain excellent therapeutic results in most cases of conjunctivitis.

Superficial inflammations of the conjunctiva are very quickly cured by daily touchings with silver nitrate, 0.25 per cent. to 0.50 per cent. In some rare cases as, for example, chronic diplobacillary conjunctivitis, zinc sulphate must be preferred, although even in this case it is not satisfactorily proved that silver nitrate, applied according to certain indications, is not equal to zinc, which, on the other hand, may be used by the patient himself.

In grave purulent ophthalmia no treatment has been so valuable as cauterization with a 2 per cent. solution of silver nitrate, repeated once or twice a day. There is now almost complete unanimity of opinion with regard to this method, and it has until lately been regarded rightly as the classic treatment of purulent ophthalmia.

Prophylactically, the value of the application of silver nitrate, in accordance with the precepts of Credé, has been equally efficient, as ample statistics will prove. Von Graefe, however, who formulated so well the rules for the application of silver nitrate, recognized himself that it was no easy matter to find the exact dose to suit each case when one was dealing with so powerful an agent which might do much harm as well as good if it were not properly applied. It is also necessary to know when to repeat the cauterizations, for the latter must be made neither too strong nor

too frequently, and every part of the conjunctiva should be brought into contact with the caustic.

Protargol should be tried in all forms of conjunctivitis in which silver nitrate was formerly employed (Darier), owing to its marked powers of penetration, its antiseptic action (as powerful as that of silver nitrate), and especially owing to its relative harmlessness and the little irritation produced when it comes into contact with the conjunctiva and the cornea.

Just as we should be prudent in the application of silver nitrate, so we may be bold in the application of protargol, the action of which is less caustic, less painful, and of shorter duration. Protargol contains 8.3 per cent. of silver, as compared with 65 per cent. in silver nitrate. Solutions used for cauterization, therefore, should be much stronger for the first-named of these salts, and in the interval between the cauterizations, frequent instillations should be practised by the patient or his attendant, for the purpose of prolonging the antiseptic and astringent action of the protargol.

Protargol, which is soluble in all proportions in water, should, like all silver preparations, be kept away from light, in fault of which solutions become darker in color, thicker in consistence, and less active in use. They should be prepared in small quantities at a time, so that they may be renewed frequently.[1]

In the majority of cases, the following formula may be recommended for instillations:

Protargol	5
Distilled water	100

For cauterization by the brush, the following solution may be applied more or less freely:

Protargol	25
Distilled water	100

[1] The protargol should be allowed to dissolve spontaneously and in the cold, contained in a yellow-colored bottle, and the powder should be sprinkled over the surface of the water, without shaking the latter.

Cauterizations by means of a brush should bear not only upon the exposed conjunctiva, but also upon the edges of the eyelids. In this way one obtains, by energetic and rapid rubbing with a brush as large as a goose-quill steeped in protargol, a kind of soaping of the lashes and of the border of the eyelids. This **protargolage** is most useful when conjunctivitis is accompanied, as is so often the case, with blepharitis. Small protargol compresses, applied during the night, are often very useful.

Protargolage often cures quickly and permanently many cases of blepharitis and of blepharoconjunctivitis. There is no need to be afraid of rubbing energetically and for several minutes the eyelids with the brush much in the same way, indeed, that the chin is soaped before it is shaved. Protargol, which is of albuminous composition, softens, as does the soap, and when imbibed, penetrates as far as the roots of the cilia, where it destroys infective germs.

A good compliment to savonnage with protargol is what may be termed **zingage**; while the spume of protargol still covers the eyelids, the *brossage* is continued for two or three minutes by means of a brush steeped in a solution of zinc sulphate, 5 per cent. The parts are then washed with sublimate or cyanid, 1 : 500, so as to remove the brown color of the protargol.

The advantages of protargol are: 1. Solutions are easily made without apparatus. 2. Solutions protected away from light keep well. 3. Even when used in solutions of 50 per cent., protargol is less irritating than the 2 per cent. solution of silver nitrate. 4. Solutions of 2 per cent. to 5 per cent. of protargol may, without inconvenience, be dropped into the eye every half-hour.

These instillations may even in certain cases replace cauterizations made by the surgeon, since we know that, thanks to its powers of penetration, protargol finds its way to the bottom of the culdesac and perhaps even into the depths of the mucous membrane.

Argyrol.—It has been claimed that as silver nitrate is

precipitated both by proteids and by chlorids, its antiseptic action is more limited than that of the organic salts. Again, it must not be forgotten that there are idiosyncrasies encountered when the patients are unable to bear, as it were, silver nitrate. Even protargol may be too irritating in such cases, while argyrol is scarcely or not at all so.

It is therefore a source of great satisfaction to the surgeon to have a remedy that is possessed of therapeutic virtues, such as those of argyrol. Serious purulent conjunctivitis is frequently controlled in less than a week by the frequent application of argyrol. But attention has been directed to the danger attending these too rapid cures. They tempt us to cease treatment too soon, and expose the patient to a relapse which is always more difficult to cure than the original attack.

Most of those who still prefer silver nitrate have had poor success with the organic salts of silver, because they have not used the latter in doses massive enough nor have they repeated the application often enough. To deny the value of the organic preparations of silver is no longer reasonable. Argyrol causes less pain than cocain or even distilled water. Indeed, the patient often experiences an agreeable, refreshing, and calmative sensation—a real relief. This fact seems strange when we consider the powerful astringent and antiseptic action of argyrol.

Instilled between the eyelids, a drop of a 25 per cent. solution of argyrol rapidly covers cornea and conjunctiva with a layer of a yellow-ochre color, and the patient complains that he sees yellow for an instant, but he never experiences any pain, provided the liquid is fresh. However, at the end of several minutes, some individuals have complained of slight discomfort, some heat, and a little dryness of the eye. This is probably due to the astringent action of the silver upon the epithelium of the cornea and the conjunctiva. Particles of mucin, also, may cause the discomfort, which is common in the use of all astringents.

In cases of **ophthalmoblennorrhea,** argyrol causes a painless and rapid reduction in purulent secretion when applied by simple instillations of a 25 per cent. solution repeated every hour or every two hours, day and night.

The organic salts of silver are so innocuous that no complication has ever been attributed to their employment. However, the morbid process is sometimes stopped so quickly that, believing the patient cured, the physician will cease treatment. In such cases there may occur a relapse that will yield only to the application of the more violent caustics, such as ichthargan or silver nitrate.

When dealing with an affection responsible for such a large proportion of blindness, the important point is to act as quickly as possible and by the surest and most inoffensive means. The practitioner who will hesitate to apply a collyrium of silver nitrate, uses without fear or delay strong solutions of protargol and argyrol, which although powerfully active are practically harmless.

The Respective Merits of the Different Salts of Silver and Their Modes of Application.—Of the numerous organic salts of silver which have been introduced into therapeutics during the last few years, two—protargol and argyrol—stand prominently. These two products, instead of being concurrents, complement each other. Argyrol, even when so concentrated as a 50 per cent. solution, is absolutely painless. It may, therefore, be given for home use, and be dropped into the eye as frequently as necessary, by day and night if need be, without producing any inconvenience, unless it be a staining of the nasal secretions of a yellow color. Its heavy silver content (30 per cent. as against 65 per cent. in silver nitrate) gives to it considerable therapeutic powers, especially as it is not precipitated and does not coagulate albumin. Owing to these properties, it penetrates deeply into the conjunctival folds and crypts and even to the deepest layers of the mucous membrane.[1]

[1] This marked detergent power of the organic silver solutions is not sufficiently emphasized, even in the manufacturers' literature.—The Editor.

In simple catarrhal conjunctivitis, we commonly prescribe four to six drops a day of the following solution:

Argyrol	5
Distilled water	100

In cases of purulent ophthalmia, the number of applications is doubled or quadrupled, and they are made every hour or even every half-hour. Thanks to this means, cases of extremely serious conjunctivitis are attenuated with extreme rapidity. In the course of three or four days, suppuration is sometimes almost absent. But if the applications are discontinued prematurely, suppuration is likely to return, and it is then very difficult to regain the ground that has been imprudently lost. This is the reason why the treatment of a purulent ophthalmia should never be wholly left in the hands of a patient or of his friends. The practitioner himself should make, once a day, an application of a strong (25 per cent.) solution of argyrol, a kind of eye-bath, and should follow this with **protargolage** or **savonnage** with protargol of the eyelids and cilia, which are favorite receptacles of infective agents, and from which relapses usually originate.

When solutions of the silver salts are prescribed, small quantities only should be dispensed (5 grms. of argyrol at the most), since as their application is quite painless, patients may readily abuse the solution and afterward suffer readily from argyrosis.

In the treatment of purulent conjunctivitis the *modus faciendi* is most simple. The instillations being absolutely painless, they may be repeated day and night, as often as may be necessary. There is no necessity of troubling oneself with the contraindication recognized by many clinicians as regards the application of silver nitrate in the very acute stage of ophthalmoblennorrhea. At the very moment when pronounced chemosis is present, when eversion of the eyelids is opposed by a kind of induration; in short, when these authors recommend an expectant line of treat-

ment and iced compresses, the instillation of 25 per cent. argyrol every half-hour, together with frequent lotions and hot compresses, will bring about the rapid resolution of all the phenomena. Therefore, even to the exclusive partisans of silver nitrate, the organic salts may render great service in the treatment of purulent ophthalmia by serving as an advance-guard and touchstone against such idiosyncrasies as may prove rebellious to silver nitrate.

Silver nitrate is one of the most powerful antiseptics and one of our most valuable local remedies, and when employed by an experienced hand is almost free from danger. At the same time it must not be forgotten that most often, especially in the country and in small villages, cases of purulent ophthalmia are cared for by the practitioner himself, who refers them to the ophthalmic surgeon only when serious complications arise. Such complications, however, are nearly always caused by the use of unduly strong solutions of silver nitrate.

The incessant progress of organic chemistry has placed in our possession most valuable agents in the organic silver salts. Besides their undoubted therapeutic qualities, they are inoffensive and easily managed. It can hardly be realized that we may almost replace so caustic and so atrociously painful an agent as silver nitrate by a remedy devoid of all irritating properties and of all causticity.

Silver nitrate is the antiseptic that kills more quickly than any other the gonococcus. But it also destroys the epithelium and sets up a reaction and violent pain which show that its application cannot be repeated as often as may be necessitated by a very virulent infective process. Argyrol, which is ten times less bactericidal than the nitrate, according to experiments conducted in Neisser's laboratory, may be dropped into the eye, without danger and without pain, in solutions thirty times stronger than silver nitrate, and these instillations may be repeated every half-hour without any inconvenience.

Strange to say, protargol, which contains only 8 per cent. of silver, is more antiseptic than argyrol, which is much richer in silver (30 per cent). As in the case of collargol and of iodoform, we have here a physicochemical question, many of the bearings of which still remain unknown. But the clinic must always take precedence over experimentation, and the first quality required of a silver salt in its application to the eye is, above all others, that of absolute innocuity. It is preferable to repeat weak doses, which cause no pain, than suddenly to set up a powerful action which is painful, irritating, and often dangerous.

For home use argyrol should be preferred; in fact, protargol, on the contrary, should be applied only by the practitioner and with circumspection. It is, to begin with, applied externally to the cilia and eyelids (**savonnage**). Cauterizations by means of a brush, were necessary with silver nitrate, because when applied by instillation, it penetrated only with difficulty to the culdesac, since it was immediately decomposed by the tears and also arrested by coagulation of the secretions. On everting the eyelids, one could recognize clearly all the zone burned by the nitrate, and see that folds of the conjunctiva had not been touched by the caustic. Protargol may be applied in the same way as argyrol. It too penetrates to the deepest folds of the conjunctiva, although it is somewhat painful.

By instilling a drop of cocarenalin a few minutes previously, this little operation may be carried out in every case with practically no pain, and much less discomfort is caused if no attempt is made to evert the infiltrated and indurated eyelid. This procedure has already been adopted by several clinicians.

Simple instillations of argyrol or protargol, followed by slight massage, act better, more deeply, and with much less pain than cauterizations by the brush.

The importance of the organic preparations of silver is shown as much by their therapeutic indications as by their constantly increasing number. Three are especially

valuable—protargol, argyrol, and collargol—but we cannot pass over in silence some of these new products.

Attempts have been made in Germany to replace argyrol by **sophol** (the formonucleate of silver), but as this product causes pain it presents no advantage over argyrol.

Argonin has been praised as an antiblennorrhagic of a powerful nature. It is a combination of casein and of silver, forming a crystalline salt soluble in water, of which fifteen parts are equal to one part of silver nitrate. This product has scarcely any irritating properties, and gonococci are very quickly killed by it. But by those who have had experience with it, it is stated to possess neither astringent nor anticatarrhal virtues, and, in order to complete the treatment of blennorrhagia, they find it necessary to employ ichthyol or other astringents. Solutions of argonin undergo rapid changes.

Zanardi has recommended the employment of **sulphophenate of silver,** which possesses all the antiseptic properties of the silver salts with the added advantage of being very little irritating, very soluble, and of keeping well. Zanardi has used it with success in general surgery as well as in eye-work, although he publishes no details of the results which he has obtained.

Itrol, or silver citrate, was introduced into ophthalmology by Credé, who had used it with advantage as a dressing for wounds. This salt appeared interesting because it was stated to be free from irritating qualities, and was a light, as it were, impalpable powder, which could be readily applied by insufflation. The remedy, however, has no advantage as compared with protargol and still less with argyrol. Nénadovic, at the Moscow Congress, praised the use of itrol, employed as a powder or as a solution of from 1 to 3 per cent. He had obtained by this means very good results in the treatment of granulous conjunctivitis. The powder should constitute an excellent means of obtaining perfect asepsis of wounds, were it not for the fact that its insufflation into the conjunctival sac is not

devoid of danger to the cornea. The nascent silver which develops from contact with wounds acts, according to Credé, as a most powerful antiseptic, but the cornea does not appear always to tolerate the application of this agent.

Mergl, of Strasburg, who praises itrol very highly, has used the remedy as insufflations in catarrhal, purulent, and granulous conjunctivitis, employing at the same time sublimate lotions and iced compresses. Secretion disappears in two or three days, and cure is definite in from six to eighteen days. As regards trachoma, the discharge was dried up as quickly by itrol as by silver nitrate. In some corneal ulcers cure was obtained by a single insufflation, followed by an occlusive dressing; but in other cases, the treatment was followed by total infiltration of the cornea. From this we must conclude that certain patients are unable to support itrol. von Arlt, in a recent communication, has praised once more the virtues of itrol, specially prepared for use in eye-work.

An analogous product, **actol or silver lactate,** was also recommended by Credé at the second German Congress of Surgery, held at Berlin in 1896. This salt is soluble in water and in albuminous liquids in the proportion of 1:25. Its antiseptic powers are very great. Thus, a watery solution of the salt kills all pathogenic microbes in five minutes, while a 1 : 80,000 solution prevents completely development of bacteria. The trials made with actol in ocular therapeutics are not yet sufficiently advanced for definite conclusions, although Mergl has recently found that its application is much more painful than that of itrol.

Collargol merits particular mention, since it may be called upon to render services as great as those of serotherapy. For more than ten years Credé has endeavored to demonstrate the salutary action of silver (itrol) upon the cicatrization of wounds. For eight years the same writer has tried to show the bactericidal power of collargol—soluble or colloidal silver—upon such internal diseases as are caused by the streptococcus, staphylococcus, etc. To begin with,

Credé recognized that such veterinary surgeons as Diekerhoff, Roeder, Evers, and Winkler had rendered an immense service to therapeutics by employing collargol as intravenous injections, thereby demonstrating the powerful and rapid action of the silver upon grave infections observed in animals. These experiences were such as the physiologists of the laboratory were unable to furnish. Since then collargol has been applied at the bedside, and, so far, no serious accidents or grave complications have been provoked by collargol, which possesses neither toxic nor irritating action.

It was at first by inunctions or frictions with a 15 per cent. ointment of collargol[1] that therapeutic trials were made, but there are cases in which frictions have little effect upon the skin or are supported badly. Under these circumstances and also when infective accidents are already advanced, intravenous injections should be used by preference, although the latter must not be adopted too late nor must they be expected to act upon the moribund nor to bring necrosed tissues to life. It goes without saying that these intravenous injections must be performed with care, and the syringe, which must be perfectly aseptic, should contain 8 c.c. to 10 c.c. The solution for injection should be one of 2 per cent., so that on each occasion it may be possible to inject 0.05 to 0.12 cgrms. of collargol. Subcutaneous injections of collargol are much less active. Upon one point Credé has rightly insisted, namely, that the dread of an intravenous injection, despite its freedom from danger, has often led to collargol being employed too late.

If the physician does not care to employ the injections at once, it is well to institute treatment by means of friction with Credé's ointment, but these applications should be made twice a day and for fifteen to twenty minutes on each occasion, in order that the ointment may be properly resorbed. When the infective phenomena are following

[1] Vaselin does not resorb collargol, so that the ointment should be compounded with a fatty base.

a rapid course, we must not hesitate to adopt at once, one after another, treatment by intravenous injections. Credé has frequently not hesitated to practise the injections before or during an operation for infection.

Among the cases treated by Credé by intravenous injections of collargol were: septicemia, puerperal fever, pyemia, osteomyelitis, infective polyarthritis, ulcerative endocarditis, erysipelas, peritonitis, erythema nodosa, anthrax, and phthisis in the second stage. Every case which was not treated when *in extremis* was cured. Even phthisical subjects, who naturally were not cured, manifested a marked improvement, with lowering of the temperature and pulse.

Several authors have studied collargol as applied to ocular therapeutics. Trousseau has reported three cases of grave intraocular infections improved by collargol frictions. Leloutre has treated three cases of infective ulceration of the cornea by inunction with collargol ointment, repeated four to five times a day, around the orbit and on different parts of the body. By this means he obtained rapid cure. In the first case a subconjunctival injection of mercury cyanid remained without effect. Baudouin has related two cases of grave ocular infection, with threatened panophthalmitis, which he was fortunate enough to stop by general frictions with collargol without any other treatment except antiseptic lavages. de Lapersonne has tried the treatment of certain purulent irites of internal cause by means of intravenous injections of collargol. One fact struck him as remarkable—namely, that in a few hours after a single injection, hypopyon had completely disappeared and the patient was relieved. The other results, however, were less brilliant.

In cases of blennorrhagia, rebellious to all treatment, as well as in episcleritis, intravenous injections of collargol (0.04 to 0.08) have brought about unexpected cures (Darier).

Godts regards collargol as a good antiseptic, as he has been convinced by many experiments made with different

microbic cultures. This action is nevertheless quite feeble, and Netter and Salomon believe that some other cause must be found to explain the inhibitory action of colloidal silver. This they assign to a catalytic power, analogous to that of ferments, which is presented by metals in a state of extreme division or in the colloidal state. There may also possibly be an increase in the local defensive power of the visual organ by the production of a more abundant polynuclear leukocytosis, and consequently by a more marked antitoxic action. Collargol is aggressive against pathogenic microorganisms, of which the development especially is hindered, but it interferes very little with living cells. It is neither caustic nor irritating. On these grounds particularly it merits a place in the treatment of ocular affections, in which the application of antiseptic collyria is, in general, very painful.

The comparatively recent discovery of colloidal silver and the restricted number of cases so far treated do not lend themselves to comparisons and do not permit of decisive conclusions, although the attention of ophthalmic surgeons should certainly be directed to the new product.

In ophthalmoblennorrhea the salts of silver are regarded as specifics, and collargol has shown itself equal to the best of them. Godts has related a very grave case which, after it had resisted silver nitrate, was promptly cured by instillations of 5 per cent. collargol. This success, with others equally convincing, justifies the employment of the medicament. In cases of dacryocystitis collargol has proved itself to be an efficacious remedy. In all the secretory affections of the eye, collargol, in collyria of 2 or 5 per cent., meets the indications already described when speaking of protargol and argyrol.

Meyer, a German naval physician, who has practised ophthalmology in China for several years, has published his experiences of the treatment of affections of the eye by itrol and collargol. His latest communication describes the result of three additional years' experience. He has

had to renounce itrol almost completely, since the heat, the light, and the moisture of China rapidly caused alterations in the product. Collargol, however, has revealed qualities of the first order under unfavorable atmospheric conditions, such as those which prevail in the East. He employs a 5 per cent. solution in the treatment both of catarrhal conjunctivitis and of ophthalmoblennorrhea. In serious cases he practises the bath with collargol followed by massage (as already described when speaking of argyrol). As soon as the discharge is dried up, treatment is completed by means of ordinary astringents. In cases of trachoma Meyer, after having emptied the granulomata, employs massage with collargol. As antiseptic before and during an operation, the same author invariably uses a 5 per cent. solution of collargol. The eye is dressed with gauze steeped in the same liquid. In traumatisms he obtains equally good results, but when panophthalmitis is already established, he has been unable to stop it either by inunctions, lavements, or by the intravenous injection of collargol. At the same time he lauds the good effects of collargol given internally in an infusion of tea.

Demets, of Antwerp, has warmly recommended the treatment of purulent ophthalmia by collyria of 2 to 4 per cent. collargol. He charges silver nitrate with possessing too violent and dangerous a causticity, especially when employed by inexperienced hands, which, on the contrary, can do no mischief if they will only content themselves with prescribing an agent so inoffensive as collargol. Legrand, in a thesis written in Bonnaire's maternity service, states that the action of collargol is as sure as, and much less dangerous than, that of silver nitrate. It does not imperil the integrity of the cornea, and cures more quickly.

The following ointment renders the greatest possible service in the dressing of wounds and of burns, granulation and cicatrization both being more rapid:

Collargol, Credé..... 10
Lanolin, vaselin, āā..... 50

In cutaneous autoplasties the inhibitory, rather than the antiseptic, action of collargol is very manifest. Suppuration is never observed around the sutures, and the dressings never adhere to the wound if sufficient ointment has been used.

Electrargol (colloidal silver obtained by electricity) possesses, according to the most recent works, real advantages over collargol obtained by chemical methods.

SECOND PART.

SPECIAL THERAPEUTICS.

CHAPTER XV.

DISEASES OF THE ORBIT.

Orbital periostitis, taken at the beginning, may sometimes be cured without surgical intervention, especially when it is of syphilitic nature. Inunctions of mercurial lanolin, followed by hot applications, repeated several times a day, may when combined with general treatment, bring about complete resolution. As soon as it is evident that pus has formed, so that fluctuation can be felt (not always easy of detection in deep-seated abscess), the collection must be freely opened by the most direct route.

Osteoperiostitis may occur at the level of the optic foramen with a rapid lowering of vision due to a central scotoma. One must then act with rapidity and energy: First, by local mercurial inunction and hot applications; second, by intensive general treatment by intravenous injections; third, by the injection into the depths of the orbit of a solution of mercury cyanid, 1:1,000. If these measures do not speedily relieve, attempts should be made to liberate the pus by incision.

Abscess of the orbit should be treated energetically. Valuable time should not be wasted with cold applications, poultices, or abstraction of blood, which bring about momentary relief only. Issue should be given to the pus at the earliest possible moment, otherwise infection of the cerebral meninges may occur. Abscess of the orbit is often complicated with panophthalmitis. In these cases it is always well to try the effect of paraspecific serotherapy.

Tenonitis is usually of rheumatic or gonococcal origin. It calls for the administration of sodium salicylate, given either by the mouth or intravenously, and also for a dress-

ing of salicylic alcohol applied to the parts night and morning. Mercurial or collargol inunctions around the orbit are useful, and also conjunctival injections of sodium salicylate, 2 per cent. Rheumatic tenonitis, when violent and bilateral, may become a very serious affection, and be followed by death with symptoms of meningitis. Under such circumstances instant recourse should be had to intravenous injections of collargol.

Affections of the frontal, sphenoidal, ethmoidal, and maxillary sinuses, while awaiting surgical intervention, should be treated by the means mentioned above.

Enophthalmos observed after a penetrating wound of the orbit is generally caused by cicatricial retraction, with nervous reflex phenomena of a complicated character. Treatment is of little value in these cases. Injections of paraffin behind the eyeball, as well as tenotomy of the four recti muscles, have been suggested.

Traumatic dislocation of the eyeball calls for reduction of the globe and retention in place by a slightly compressive bandage. If the reduction is delayed, loss of sight is to be feared.

Pulsating exophthalmos requires, in general, the intervention of the surgeon, who ties the carotid, since it is very rare for a permanent effect to be produced by compression, even when combined with potassium iodid and the injection of gelatin. Infective exophthalmos in these cases has been cured by paraspecific serotherapy.

Exophthalmic goiter is usually under the care of the internist or neurologist, although the ocular signs are often the first symptoms to attract attention. The results obtained from medical treatment have rarely been sufficient. At first sodium salicylate, in doses of from 3 to 5 grms. a day, for several months, with intervals of nonmedication, may be tried. Identical results have followed the administration of quinin sulphate in doses of 0.80 to 1 grm. This treatment may be completed by bromids and valerian, which induce more tranquil sleep.

A certain number of cases have yielded to therapy with the serum of animals from which the thyroid gland has been removed. The direct application of radium over the thyroid region has already given some very rapid and encouraging results.

Surgical treatment of exophthalmic goiter, as by ligature of the thyroid arteries, thyroidectomy, exothyropexy, and resection of great sympathetic, has its partisans, but the ophthalmic surgeon will hesitate before he commits himself to such undertakings. However, when the exophthalmos is so pronounced as to prevent closure of the lids, he may suture the lids together, so as to protect the cornea against certain destruction.

During the last few years Abadie has obtained brilliant results by extirpation of the superior cervical ganglion of the sympathetic, but this is an operation which belongs to the domain of general surgery.

The treatment of **strabismus** is largely optical and rarely surgical. The first aim should be to reestablish binocular vision. Even when this desideratum cannot be obtained, operation may be indicated on purely esthetic grounds.

Paralysis of the ocular muscles must be treated according to the indications furnished by the etiology, as syphilis, rheumatism, hysteria, injury, cold, etc. In syphilitic cases, mercury should be applied with persistence by inunctions around the orbit and mercurial injections. Good results may be obtained in certain nonspecific cases by dressings of alcohol and salicylate. Electricity is useful, especially when it is applied at the moment when muscular contractility is beginning to awaken. The continuous current followed by the faradic current will then hasten cure.

In order to avoid the discomfort caused by diplopia, the affected eye may be covered with an opaque glass. When muscular paralysis has lasted for several months without manifesting any tendency to cure, good results may often be obtained by the surgical advancement of the

paralyzed muscle, combined, if necessary, with tenotomy of its antagonist.

Ptosis.—When ptosis is caused by paralysis of the levator muscle, special spectacles may be worn, the effect of which is to raise the drooping eyelid by a simple mechanical device.

Trigeminal neuralgia (supra- or sub-orbital) should be treated at first by the administration of quinin (0.40 to 1.0), aconitin (0.0025, two or four times a day), and by an antineuralgic, such as antipyrin, phenacetin, pyramidon, etc. Durable results are also given sometimes by electricity and radium. When the neuralgia has become chronic before resorting to surgery, trial should be made of injections of alcohol along the nerve trunk, so as to induce degeneration. When injection is successful, cure is complete for a year or less, always provided the underlying condition has been a peripheral neuritis. On the other hand, if the neuralgia is of central origin and accompanied by ocular symptoms, there is little chance of cure. All cases of facial neuralgia not submitted previously to surgery should be treated by the local injection of alcohol. Relief lasts on the average for a year, and even longer relief can be given by a new injection (Schloesser).

Good results have been obtained from electrolysis with medicamentous ionization (S. Leduc). A pledget of absorbent cotton, moistened with a 5 per cent. solution of sodium salicylate, and connected with the cathode of a constant current, is applied to the painful point of the affected nerve. The positive pole may be placed on any part of the body. A current of 25 milliamperes is allowed to pass for half an hour or an hour. The sittings should be continued on several consecutive days, and they often result in complete cure (Desplats).

Lastly, if all the measures mentioned above are inadequate to cure the case, we must turn to surgery, and in the first place to peripheral *arrachement* of the branches of the trigeminus. Pain ceases at once, especially if simul-

taneous sympathectomy is performed at the same séance. The latter is an operation which yields excellent though tardy results.

If the pain is diffuse, occupying the whole of the trigeminus, the Gasserian ganglion must be extirpated or the great root of the trigeminus divided. Such operations are best left to the general surgeon.

Blepharospasm is the tonic or clonic contraction of the orbicularis palpebrarum muscle. The contraction may be reflex, symptomatic (foreign bodies, conjunctivitis, keratitis), or of central origin (sleeplessness, overwork), and may occur as a "tic." In children, blepharospasm and photophobia are common in the course of a keratitis, and the first treatment is to cure the causative keratitis. Dionin is the best local remedy. In these cases, immersion of the face in cold water has been widely recommended. In cases of slight blepharospasm permanent cure may sometimes be obtained from the bromids, massage, and electricity in one of its many forms. Radium is also useful. When blepharospasm becomes chronic it is very difficult to cure. Suggestion may succeed among hysterical patients, but surgical intervention is more often called for. This may call for elongation of the facial nerve in its whole length.

Injections into the mastoid process and deeply along the styloid process are also recommended. For this purpose one to two cubic c.c. of the following solution are employed:

Cocain chlorid	0.05
Ninety per cent. alcohol	10.0

If the injection has been made into the trunk of the facial nerve, there results complete paralysis, with lagophthalmos and deviation of the buccal commissure. This paralysis, which is essential to the cure, usually lasts from eight to fifteen days, and is sometimes accompanied by passing disturbances of the spinal nerves, as shown by the fact that the patient experiences difficulty in raising his

arm. Cure is not invariably obtained after a first or a second injection. But, in general, it is durable, and, in case of recurrence, the injection may be repeated. The intervention is somewhat delicate, and the oculist will do well in these cases to avail himself of the services of a surgical colleague. When blepharospasm is limited to one eye, it can be endured without great inconvenience, but often the other eye is involved, and the patient cannot then go about unaccompanied for fear that a spasm may occur when crossing the street. In these cases surgical interference, on one side at least, is obligatory.

Before resorting to surgical intervention the operator would make sure that the blepharospasm is not due to a dental or conjunctival reflex. It must not be foregotten that the spasm sometimes originates in a narrowing of the lacrimal passages, and in these circumstances definite cure may result from probing (Bettremieux).

CHAPTER XVI.

DISEASES OF THE LACRIMAL APPARATUS.

The lacrimal glands are rarely the seat of disease, although, in common with other glandular tissues, they may be subject to tumor-growth.

Dacryoadenitis is often met with as a complication of various infective diseases. Dacryoadenitis appearing simultaneously on both sides may constitute the whole symptomatology of an epidemic infection. The best treatment in these cases is by mercurial poultice, dionin, and diaphoresis by pilocarpin.

Mikulicz's disease is the name given to an imperfectly understood swelling of the lacrimal and salivary glands. Treatment lies in radiotherapy, local mercurial frictions, potassium iodid, thiosinamin in doses of 0.06 a day. Syphilis is sometimes the cause of the affection.

The most common affections of the lacrimal apparatus are those which are caused by an obstruction of the excretory channels for the tears.

The simplest form is **congenital imperforation** of the lacrimal canal at its entry into the nose. In these cases, the newly-born baby presents a watery eye, with a little mucopurulent secretion. The obstruction is generally caused by a plug of epithelial cells, mixed with mucus. It is usually only necessary to make through the lacrimal punctum an injection of water colored with fluorescein in order to demonstrate its passage into the nose. During the injection, the head of the little patient should be held forward, so that the fluid injected may readily escape through the nose. It is rare that the injection need be

repeated often, unless the affection has become chronic or has provoked a dacryocystitis or is complicated with blennorrhea of the lacrimal sac.

Excessive lacrimation is a common condition which may be due to various causes. The cases which are connected with an error of refraction are usually ill-marked, and, provided they have not become chronic, may be cured by wearing proper lenses.

The commonest form of lacrimation is that which appears after a "cold" or a coryza, or after an attack of conjunctivitis with a swollen mucous membrane; the canal may be readily obliterated by a plug of mucus. Treatment consists of an injection of cocarenalin, which irrigates the canal by the mechanical action of the fluid, while its constrictive power shrinks the mucous membrane and enlarges the caliber of the canal. In these recent cases incision and probing should be avoided, since such operations are more likely to do harm than good.

It is only after three or four injections of cocarenalin have been made at intervals of two or three days, and lacrimation still persists, that we should dilate the canaliculus (incising it only when absolutely necessary) and explore the nasolacrimal canal with a flexible olivary **lacrimal probe.** If a definite resistance is found, the obstruction must be progressively dilated by means of Bowman's sounds, Nos. 2, 3, and then 4. The larger sizes are for the most part useless. Too enthusiastic use of lacrimal probes, either large or small, has been the common error of ophthalmologists.

At first, the probe should be passed every other day, and then every three or four days, to be gradually discontinued as the lacrimal secretion escapes by the nose. As a rule, probing or catheterism should be practised five or ten minutes after a little cocarenalin has been injected into the canal. This renders the passage of the probe both easier and much less painful. It goes without saying that the probe should previously be sterilized (in the flame),

and it is a good plan to smear it with sublimate vaselin before it is passed.

As the result of blepharoconjunctivitis, the lacrimal punctum is often everted and closed, so that it must be sought with the aid of a magnifying glass. Under these circumstances the course of the tears may be reestablished by incising the canaliculus as far as the caruncle.

Cases of chronic lacrimation are much more difficult to cure. If dacryocystitis is not present, we must content ourselves with a few probings at intervals which will depend upon the result we obtain. In these cases we may proceed as far as the use of Bowman's No. 6 probe. Electrolysis of the lacrimal canal has yielded good results. Finally, if despite the use of the probe, the epiphora is not subdued, we have recourse to removal of the lacrimal glands. At first the surgeon excises the palpebral glands, and then should the tearing persist, he removes also the orbital gland. He may also endeavor to enlarge the nasal orifice of the lacrimal canal, but this leads into the domain of rhinology. Permanent drainage may be accomplished by means of a silk thread passed from the eye into the nose (Koster).

Good results are sometimes obtained by means of a style (Vulpius and others). At first it is allowed to remain in place for two or three days, and afterward for weeks or even months, care being taken to remove it from time to time, so that it shall not become covered with cicatricial tissue. The probe is employed again only if the lacrimation recurs.

A watering eye is sometimes caused by concretions in the canaliculus (actinomyces, streptotrichæ), and in these cases it is easy to express a little clear matter from the dilatated and prominent lacrimal punctum. If the latter is incised, it is found that the canaliculus is dilated, ampulla-like, and filled with three or four concretions, of soft consistence, which may be crushed between the fingers. One or two injections of slightly oxygenated water or of 5 per cent. argyrol quickly and completely cure the case.

Dacryocystitis often follows chronic lacrimation. Blennorrhea of the sac may also arise from propagation of infection from the conjunctiva to the sac. This propagation is equally common in trachoma and tuberculosis, and the last-named may originate from lupus of the nose. In cases of lupus cure may be promptly secured by injections, made every day into the lacrimal sac, of solution of guaiacol, 1 or 2 per cent. (Darier). When we have to deal with a trachomatous dacryocystitis it is best to extirpate the sac promptly, although such cases have been known to be cured, as well as the trachoma itself, by treatment with simple irrigation of 5 per cent. argyrol, of zinc sulphate, 10 : 1,000, or of copper sulphate, 1 : 5,000.

Jequiritol often leads to dacryocystitis, which cannot always be cured by jequiritol serum, and must then be treated by extirpation of the sac (Darier).

Extirpation of the lacrimal sac is an operation that, when properly performed, is most advantageous especially for those individuals who cannot spare the time necessary for treatment or for those who live far from an ophthalmic surgeon.

Dacryocystitis may be of mucous character. On pressing over the region of the lacrimal sac, one sees escape from the puncta a viscous liquid, transparent like glycerin. Under such circumstances dilatation must be practised with Bowman's probes, going as far as No. 6, and after each séance an injection should be made of cocarenalin. Should the mucous secretion persist despite probing, the parts should be irrigated with potassium permanganate, 1 : 1,000, chlorin water, or oxygenated water, using for the purpose a grooved probe. The chlorin and oxygenated water should be progressively increased in strength as the parts become tolerant to their use.

Purulent dacryocystitis, or blennorrhea of the sac, should be treated on similar lines. But during the commencement of the treatment, irrigations of the sac should be made daily and with great circumspection, in order

to avoid false passages and the injection of caustic fluids into the cellular tissue. An injection of protargol, having gained the cellular tissue, may result in atrophy of the optic nerve. A dark staining of the parts, which persists for several weeks, is, however, the commonest sequel of this accident.

The first injection should be made with a colored fluid, such as cocarenalin with a drop of fluorescein, argyrol, or permanganate, so that we can quickly see the colored fluid escape from the corresponding nostril, and thereby avoid undue force as regards the syringe, or the reservoir, which is raised some centimeters above the eye.

The lavage should exert a mechanical action. At first, therefore, we inject an anodyne fluid, saline, alkaline water, or boric acid solution. Then, the canal being cleansed in this way, some drops of argyrol, 5 per cent., are injected. These injections having been made for four or five consecutive days, 3 to 5 per cent. protargol is injected every other day. Care must be taken that purulent secretion has no time to collect between two injections, and the intervals between the latter should be lengthened cautiously, and, lastly, we should understand how to vary the liquids or their density.

Argyrol, protargol, potassium permanganate, zinc sulphate, chlorin, or oxygenated water in solutions of ascending strength yield the best results. Guaiacol, however, is the specific for cases of tuberculous dacryocystitis.

Patients should be seen once every one or two weeks, and then once a month, and on the least sign of recurrence, daily irrigations should be resumed. Thanks to these precautions, extirpation of the sac may often be avoided, although when symptoms refuse to yield to this treatment, that operation is the sole and ultimate resort.

During the last twenty years **electrolysis** of the lacrimal passages has been employed. It appears to be well-established that séances of five or six minutes with a current of from 4 to 6 milliamperes, the probe being con-

nected with the negative pole, give a more rapid result, a larger dilatation of the canal, and a more rapid cessation of the suppuration. Excellent results may also be obtained from division of the stricture with Stilling's knife, or Terson's curettage of the canal, combined with detersive injections.

Very acute dacryocystitis, or **abscess of the sac,** accompanied by swelling and edema of the eyelids, the cheek, and the forehead, should be treated at first, if possible, by free incision of the canaliculus with Weber's or Stilling's knife, the blade being passed to the bottom of the sac. If pus issues by this incision, there is the chance that incision through the skin, and the fistulæ which sometimes result from it, may be avoided. An opening once effected, injections should be made with caution into the sac, and if the fluid passes by the nose, cure will quickly result. Resolution may be hastened by mercurial poultices applied three or four times a day.

If the phlegmon be already too advanced, and pus point toward the skin, pericystitis is present, and a radical operation can be avoided no longer. The skin-incision should embrace the length of the sac (a centimeter and a half at least) and the point of the scalpel should touch the osseous wall of the fundus of the sac. A generous curettage should then be practised, followed by cauterization of the bottom of the wound, either with zinc chlorid or the thermocautery. Lastly, the parts are dressed with iodoform gauze, which is renewed daily or every other day until such time as cicatrization is well advanced.

Instead of curettage, deep cauterizations with the thermocautery, so as to destroy the walls of the sac, has been praised. But preliminary curettage allows of a much deeper cauterization, especially if we are able to employ secure, good hemostasis.

An old but very good plan is to apply to the parts after the cutaneous incision an arrow of Vienna paste, which is kept in contact with the fundus of the lacrimal sac for six

hours. The eschar thereby produced is cast off in about five days, and the wound which is then left is dressed with tampons of iodoform-gauze. At the end of four or five weeks, the wound may still remain unhealed, and a chronic oozing threaten to leave a lacrimal fistula. The track must under those circumstances be treated with the galvano-cautery or with tincture of iodin or zinc chlorid, etc., but in these cases the essential point is to endeavor to restore the course of the tears—that is to say, if the mucous membrane of the sac has not been completely destroyed. That may be done by catheterization and especially by the grooved style. If the obstruction is situated in the nasal part of the canal, the nasal wall of the passage may be destroyed, the inferior turbinate being resected at the same time according to the procedure of Okuneff (*La Clinique ophtalmologique*, 1908).

When dacryocystitis or phlegmon is symptomatic of osseous lesions, it should be treated with injections of glycerin-iodoform, together with injections of guaiacol:

Guaiacol cacodylate	0.10 to 0.20
Sterilized water	10.00

and by specific treatment when the lesions are of syphilitic nature. Potassium iodid succeeds promptly in cases of actinomycosis.

Mucocele (lacrimal tumor) should generally be extirpated, since injections and probings seldom succeed in such cases.

The prelacrimal tumor, the encystment of fluids anterior to the sac, always calls for radical intervention. It should be treated by incision carried to the bottom of the lacrimal sac, followed by curettage, and dressing with gauze from the bottom of the wound.

Lacrimal Complications.—An inadequate escape of tears, without obvious epiphora, may by evaporation of the tears from the edges of the eyelids, set up symptoms of irritation and conjunctivitis or blepharitis, spoken

of as "lacrimal." In such cases there may be noticed only a puzzling irritation of the eye, which often vanishes after the probe has been passed several times. Several cases have been described by Bettremieux in which this lacrimal condition has caused, first, blepharospasm and then neuralgia of the face, conditions both of which were cured by lacrimonasal catheterization.

CHAPTER XVII.

DISEASES OF THE EYELIDS.

Solar erythema should be treated by compresses of lead lotion and by the application of powdered starch.

Eczema of the eyelids may be localized to the parts immediately around the eye, especially to the lower eyelid. It often results from chronic lacrimation, and in such case the lacrimation must be first treated. If the eczema is chronic, it may be very difficult to cure, particularly in old persons, and the same remark is true when the eczema is accompanied by marked prurigo. Under these circumstances, vapor douches, cataplasms, and simple moist dressings, although succeeding, in one case, may fail in another. In such eczemas as will not bear moisture, there should be resort to ointments containing zinc oxid, ichthyol, lead acetate, tar, etc.

To speedily relieve the **prurigo** and roughness of the skin we may practise light massage of the eyelids with an ointment of cocarenalin, protargolage having been first employed:

Cocain hydrochlorid	0.10	
Adrenalin, 1 : 1000	40	drops.
Vaselin and lanolin, each	5.00	

The inunctions are repeated by the patient as often as they are demanded by the prurigo. For the relief of the itching of the eyelids which accompanies eczema, good remedies are compresses moistened with acidulated lotions, and the administration several times a day of a few drops of sulphuric acid in a glass of water. In these cases correction of the régime is of great importance. Collargol ointment, 5 per cent., a nonirritating remedy and

a preventive of organic fermentations, sometimes yields unexpected results in rebellious cases (Darier).

In lymphatic children, impetiginous eczema may be observed upon the eyelids, as upon the face, and is generally complicated with phlyctenular conjunctivitis and keratitis. It yields to the same treatment, local and general. Cleanliness of the hands, the face, the head, and of the clothing possesses in these cases special importance.

Acne rosacea is seen less frequently upon the eyelids than upon the cheeks or the nose, but when the nodules occur upon the border of the lids there is reason to fear that they may also appear upon the cornea, which is a dangerous complication of the disease. A very ancient remedy, turpeth mineral, gives excellent results in acne of the face. It is applied with perseverance night and morning, the parts being massaged for fully ten minutes with the following ointment:

Turpeth mineral.....	2.0
Lanolin and oil of almonds, of each.....	15.0

Under the influence of this medicament, old infiltrations become attenuated and new efflorescences are aborted without any general treatment whatever. The treatment should be resumed upon the appearance of the least eruption. To such patients the waters of warm and sulphurous springs are beneficial. As regards general measures, one remedy alone has stood the proof of time, and that is sulphur, of which we may prescribe 2 grms. a day.

Erysipelas of the eyelids occurs in erysipelas of the face and nose. It may originate at the level of the punctum, especially after dacryocystitis. The ordinary treatment of erysipelas, together with paraspecific serotherapy, must be adopted in these cases. In grave cases intravenous injections of collargol are indicated.

Zona ophthalmica, when accompanied by swelling of the whole of one side of the face, is often mistaken for

erysipelas. If seen at the commencement of the disease, the best treatment is by serotherapy. Antidiphtheritic serum, injected for eight to ten days in succession, will rapidly reduce the pain, fever, and swelling. The suppuration of the pustules speedily disappears, and the cicatrices resulting from them are not so deep. But more frequently the case is not brought to us until the infection has already run its course, and we have to deal with neurotrophic manifestations. The painful symptoms may be attenuated by quinin, valerian, pyramidon, etc., and locally by injections of dionin (from 0.02 to 0.05), and frictions with iodoform ointment or, better, with:

Guaiacol cryst	0.2
Menthol	0.1
Lanolin	10.0

Electricity also renders service in the reestablishment of the nervous functions. It must not be forgotten that herpes zona, of but slight importance when it occurs in young subjects, is apt to acquire quite an exceptional gravity among the aged, who often suffer for years from the pain induced by the affection. It is now recognized that herpes is the outcome of an infection of the anterior roots of the rachidian nerves and the corresponding sympathetic ganglion. As regards zona ophthalmica, the Gasserian ganglion and its sympathetic nerves are the seat of the infection. It is on the element of infectivity that serotherapy acts when the case is taken at the beginning.

Xanthelasma of the eyelids affects, as a rule, only persons past middle age. The unsightly yellow spots may be treated by surgical excision or by electrolysis. Radium, applied for ten to twenty minutes over each diseased point, should bring about the progressive resorption of the disease, without leaving visible traces of its action. It is common to obtain a history of jaundice or other hepatic accidents in cases of xanthelasma.

Wounds of the eyelids may become complicated with cephalic **tetanus** of special gravity, leading to death in a few hours. In all suspicious wounds, therefore, a preventive injection of antitetanic serum should be administered. This precaution does no harm, and, on the contrary, hastens cicatrization, diminishes suppuration, etc.

Styes of the eyelids and marginal boils should be treated by poultices and incision, and then by careful antisepsis, in order to avoid the recurrences, which are apt to be so frequent.

Chalazion is not a simple cyst, but a granuloma commencing in a Meibomian gland. It is infective and contagious as regards transmission from one eye to the other. In these cases success sometimes follows the use of iodin ointment. Radium may be of use, although when the tumors have attained a certain size the knife is the best treatment. Care should be taken not to open the envelope of the growth, for the infective agent may thereby be inoculated into the neighboring tissues, and in this way cause a diffuse infiltration very difficult to cure. For a similar reason it is convenient to employ a couple of scalpels, so that the knife employed to open a purulent cavity shall not be again used to evacuate a noninfected chalazion.

Edema of the eyelids is usually symptomatic of a local affection, as, for example, the bite of an insect, hard chancre of the eyelid, chalazion of the outer angle, ocular or orbital infections, periostitis, etc. Edema may sometimes be of unknown cause, idiopathic, and it has been observed in albuminuria and among some patients suffering from anemia and heart disease. Treatment depends entirely upon the cause.

Emphysema of the eyelids should be treated by compression and astringents (extract of lead, etc.). The patient should be warned against blowing his nose, which might cause renewed penetration of air under the skin.

Malignant pustule of the eyelids cannot be diagnosed

with certainty unless the characteristic microorganism is found in the pus. The affection is observed among butchers, knackers, leather-dressers, etc. It must be treated by the application of the actual cautery to the whole of the necrotic region, followed by injections of carbolic lotion, 5 per cent., into the surrounding parts.

Hard chancre of the eyelids is readily diagnosed. At the beginning, before the glands are infected, the chancre may be excised or destroyed by radium. In later cases the chancre is treated locally by calomel or sublimate, while internally intensive mercurial treatment by inunctions or intravenous injections is adopted. The soft sore of the eyelids is to be recognized by the presence of Ducrey's bacillus. The ulceration is painful. It may be rapidly cured by the cautery and iodoform dressings.

Epithelioma of the eyelids (cancroides, ulcus rodens) is met with frequently among aged persons, although it is extremely rare in young adults. Its evolution is very slow and its treatment very laborious on account of the frequent relapses. The best therapeutic results are to be obtained from radium in the smaller tumors and from X-rays in grave cases, associated with ulcerations upon the surface and in the depths of the neoplasm. Local applications of potassium chlorate or of methylene blue are good adjuvants. Jequirity, applied to the ulcerated surface, is said to bring about a rapid cure (Rampoldi).

Tuberculous ulcerations of the eyelids, such as in **lupus,** have been treated with success by Finsen by means of phototherapy. When the ulceration is not very widely spread, there is an advantage in excising all the morbid tissue and endeavoring to bring together the lips of the wound with a view to securing union by first intention. The galvanocautery, iodoform dressings, or guaiacol dressings, are the local measures most employed, but they should be accompanied by persistent general treatment, consisting of fresh air, sunlight, excessive feeding, cod-liver oil, iodotannic preparations, guaiacol, etc.

When lupus of the eyelid is very small and clearly localized, it may be treated with great chance of success by repeated applications of radium, prolonged massage with guaiacol ointment (5:100) being employed during the intervals. When the plaques of lupus are larger, Finsen's method should be adopted, either alone or preceded by as complete an exeresis as possible, with a bringing together of the healthy edges of the skin. Of late years the X-rays combined with high-frequency currents have been recommended. Scarifications, followed by high-frequency currents, also give good results (Zimmern).

Blepharitis.—Among predisposed subjects very different causes, such as cold, heat, dust, bright light, close air, and errors of refraction, may provoke hyperemia of the edge of the eyelids (marginal blepharitis). In such cases it is to hygiene that we must chiefly look to avoid relapses. Other precautions include the provision of protecting and correcting glasses, the avoidance of smoke-laden atmospheres, and of excessive work by artificial light. Momentary relief to symptoms may be obtained by compresses of cold water or of lead lotion and by vapor douches.

Marginal blepharitis (blepharitis squamosa) produces desquamation of the edge of the eyelids, together with smarting and itching. Individual predisposition plays the principal part in these lesions, and proper observance of hygiene is the best treatment. Lotions, poultices, and ointments, of which the formula should be varied, form the basis of medical treatment:

Red precipitate	0.05
Vaselin	5.00
Lanolin	5.00

Yellow precipitate	0.2
Extract of lead	10 drops
Vaselin	5.0
Lanolin	5.0

Zinc oxid	1.0
Vaselin	5.0
Lanolin	5.0

Ichthyol	1.0
Lanolin	10.0

Appreciable improvement follows the frequent disinfection of the edge of the eyelids by prolonged protargolage, followed by touching the affected parts with zinc sulphate or with copper, taking care not to allow the last-named to come into contact with the conjunctiva. The treatment, however, is followed by some hours of more or less active irritation, which, however, may be calmed by cocarenalin ointment.

The lacrimal passages should always be examined attentively, since the affections may be caused in the first instance by too slow an escape of the lacrimal secretions.

Hypertrophic blepharitis represents merely an individual modality, which is best treated surgically by, first, longitudinal incision and *grattage* of the entire palpebral border; secondly, fine galvanopunctures; and, third, electrolysis.

Ulcerous blepharitis may succeed to the foregoing or may result from a chronic conjunctivis. The hair-bulbs are soon invaded by the infective elements, which remain *in situ* for long.

Ciliary blepharitis is the most tenacious and disagreeable of all forms of blepharitis. The only efficacious treatment is by the repeated epilation combined with the use of the most active antiseptics. The difficulty is to make these agents penetrate to the root of the cilia, where the germs of infection lurk. Each cilium pulled out carries with its root a large number of germs, but those which remain multiply and infect anew the fresh hair-bulbs, which should in turn be epilated as soon as they are long enough for the purpose.

After epilation, we must endeavor to make the anti-

septic agent penetrate as deeply as possible. Protargolage, prolonged massage of the palpebral edge with mercurial lanolin (which is not irritating), with turpeth-mineral ointment, or with collargol ointment, yields good results, and also compresses of these ointments applied during the night.

Compresses moistened with *eau d'Alibour* afford a good alternative treatment to the other remedies. The formula is as follows.:

Lapis divinus	1.00
Zinc sulphate	2.00
Camphorated alcohol	10.00
Saffron	0.30
Distilled water	300.00

Although general treatment has always a certain importance, yet its value in these cases has been much overrated. Hygiene should aim at avoiding reinfections, and therapeutics at getting rid of them as quickly as possible. (Careful correction of ametropia is a *sine qua non* in the treatment.)

Conjunctival blepharitis will be discussed when speaking of inflammations of the conjunctiva.

Parasitical blepharitis (head- and crab-lice), once recognized by means of the magnifying-glass, can be cured in two or three days by thorough massage with mercurial lanolin.

The following ointment is often efficacious when dealing with certain cases of obstinate blepharitis:

Red oxide of mercury	0.05
Resorcin	0.50
Ichthyol	1.50
Oxid of zinc	1.00
Lanolin and oil, of each	10.00

CHAPTER XVIII.

DISEASES OF THE CONJUNCTIVA.

Chronic conjunctival irritation and congestion generally arise from individual predisposition, sometimes from a familial hereditary tendency, which under the influence of excessive light, the confined air of rooms, workshops, or schools, dust, or smoke causes irritation of the edge of the eyelids (blepharitis marginalis) and of the conjunctiva (chronic conjunctival irritation). This predisposition may also be acquired by imperfect action of the lacrimal apparatus (inadequacy of secretion or contraction of the excretory channels) or by errors of refraction, muscle imbalance, accommodative asthenopia, etc.

Overwork, inadequate sleep, long sojourn in school during the short winter days, etc., are also frequent causes of ocular irritation, without other lesion than slight hyperemia or a follicular state of the bulbar conjunctiva and the lower culdesac. The patients complain of smarting, itching, burning, heaviness of the lids, and of a sensation as of sand beneath the eyelids. Aged persons often complain that they are unable to open their eyes during the night, Their eyelids seem to be glued to the eyeball (dry catarrh, nocturnal spasm of the eyelids). In these cases we may sometimes find calcareous infarcts of the Meibomian glands in the tarsus of the upper eyelid. As preventive measures we must secure good ventillation, proper lighting, regulation of close work, sufficient sleep, exercise in the open air, etc. The general state must be strengthened by quinin, iron, iodin, and tannin and sometimes bromids and valerian.

The local treatment includes, first of all, the proper correction of ametropia and the placing in good order of

the lacrimal passages. The best local remedy in these cases is 5 per cent. argyrol, which at once reduces irritation and lubricates the surface of the conjunctiva. But at the end of an hour the eye should be well washed with a 1.4 per cent. solution of common salt (a solution isotonic with the lacrimal fluid) in order to get rid of the excess of argyrol which has not escaped by the lacrimal passages and which may become irritating to the cornea.

When argyrol is badly borne or no longer acts well, it may be replaced by the following mild collyrium:

Zinc sulphate	0.005
Distilled water	10.0

Marked relief may be obtained by vaporizations or vapor douches applied twice a day. Lead extract may be applied as follows:

Extract of lead	15.0
Glycerin	15.0

Thirty drops of the above liquid in a quarter of a glass of water may be used in compresses and lotions.

The repeated instillation of the following collyrium will be found very useful in cases in which itching is troublesome:

Cocain hydrochlorid	0.05
Dionin	0.10
Solution of mercury cyanid (1 : 5,000)	10.00

Another useful formula recommended by von Graefe is:

Tincture of opium	5.0
Distilled water	5.0

The oily collyrium of acoin or a solution of guaiacol, 1 per cent., may also be tried. There may also be used as lotions the following: the infusions of various plants, saline, boric lotion, borax wash, chlorin water, or the hyposulphite of sodium, 4 per cent. Massage of the eyeball may also have a good effect.

True conjunctivitis is in general caused by the presence in the conjunctival sac of well-recognized infective elements.

In the normal state there are nearly always upon the surface of the conjunctiva a number of microorganisms, but these happily produce no mischief so long as the tears escape properly. But if for any reason, as, for example, by the influence of cold, the secretion becomes arrested or modified, there may ensue a sudden multiplication of the habitually inoffensive germs of the conjunctiva. This accounts for the so-called "taking cold in the eye."

Besides these simple infections, there remain the cases of conjunctivitis due to contamination, which may be recognized and classed in accordance with their infective agents. By pure empiricism, there has been found a so-called specific remedy for each type of conjunctivitis, and yet great obscurity still obtains in the classification of all these conjunctival infections.

Neisser acted as pioneer when he discovered the gonococcus, and to-day we are assured that purulent ophthalmia is usually a gonococcal conjunctivitis.

In 1883, Weeks described clinically and experimentally a particular form of acute contagious conjunctivitis, characterized and caused by the presence of a specific bacillus, already observed by Koch in the seasonal conjunctivitis of Egypt. This form of infection may be called Weeks' conjunctivitis. Quite recently, a third morbid entity has been discovered by Morax and Axenfeld, namely, the subacute conjunctivitis caused by diplobacilli, once denominated "angular conjunctivitis."

A fourth and well-determined class also is that of diphtheritic conjunctivitis, caused by the Löffler bacillus, pure or associated with other microorganisms. Among scrofulous subjects the pneumococcus and Weeks' bacillus may give rise to false membranes; but these are not serious and should not be treated strenuously.

Granular conjunctivitis is certainly also of infective

origin; although we do not yet know the pathogenic agent, it does not constitute any the less a well-characterized morbid entity.

Pneumococcal conjunctivitis rarely appears in epidemic form. It is, in general, benign. It is often limited to one eye. Its symptoms resemble those of Weeks' conjunctivitis. It may sometimes, according to the epidemic, assume all the appearances of the most violent purulent conjunctivitis, but the diagnosis is made clear on the third or fourth day by sudden improvement in all the symptoms. It is in such cases that one obtains the greatest success with the most anodyne medications. Any treatment of purulent ophthalmia must not be unduly praised unless accompanied by conclusive bacteriologic investigations.

Streptococci are found, especially in cases of dacryocystitis and in lacrimal blepharoconjunctivitis. They are sometimes added to other infections, and often communicate to pseudomembranous conjunctivitis a quite exceptional gravity.

Staphylococcal infection is much less common than would be supposed, considering the frequency with which these microorganisms are found in the conjunctival sac.

After or during the evolution of a palpebral affection, such as a *stye*, an acute conjunctivitis, having a particular aspect and course, may appear. It remains limited to one eye. Secretion, which is usually moderate in amount and yellowish in color, forms in the culdesacs, and glues the eyelids to each other, and covers the conjunctiva with a fine pellicle, which can be readily detached. The conjunctiva shows the greatest changes in the culdesacs, which are swollen, red, and devoid of their natural glistening appearance. The ocular conjunctiva is often injected. In some cases the lower lid is a little red and swollen. The preauricular gland is tender and enlarged. The cornea remains intact. At the end of five or six days, improvement shows itself by a diminution in the amount of the

secretion. The diagnosis between the affection described above and the inflammations caused by the organisms of Weeks, Morax, and Löffler can be established by bacteriologic examination.

Phlyctenular conjunctivitis, the exact nature of which is not yet well-established, is often set up by the staphylococcus and sometimes by the bacillus of Weeks, of Koch, and others. There is an individual reaction rather than a malady or a specific infection. A simple injury or a trivial irritation may be the cause of an attack of phlyctenular, eczematous, or lymphatic inflammation of the conjunctiva.

It may be asked whether, apart from these microbic affections of the conjunctiva, there is such a thing as a pure catarrhal inflammation of the conjunctiva due to a special pathological condition of the conjunctival mucous membrane. It is difficult to decide whether cold and mechanical irritations are capable of provoking inflammations of the conjunctiva. But it is certain that some individuals, particularly those of lymphatic temperament, present a susceptibility, an irritability, and a vulnerability of quite a special order as regards the conjunctival mucous membrane, which thereby becomes a favorable soil for any infection.

The Treatment of Conjunctivitis in General.—From the therapeutic standpoint, the discovery of the different bacterial infections has not yet yielded indications sufficiently precise to determine a treatment appropriate to the bacteriologic classification. The clinical symptomatology must still be our main guide to treatment. The only exception is furnished by diphtheritic conjunctivitis, which yields to specific treatment by the antitoxic serum of Roux and of Behring. Diplobacillary conjunctivitis has also its specific remedy in zinc sulphate.

In simple, catarrhal, and acute contagious conjunctivitis, affections which may present the same clinical appearances, whether caused by Weeks' bacillus, the

pneumococcus, or any other commonplace microorganism, the treatment may be the same, varying only according to the intensity of the reactional phenomena and the individual conditions of each subject.

As a general principle, it is not wise to trust to patients to apply local remedies to their eyes. If they are very sensitive, they are apt to recoil from using the collyrium prescribed, while, in the contrary event, they are likely to abuse it. Whenever a patient can attend with regularity, the practitioner should himself apply the remedies, leaving in the patient's hands only such anodyne lotions as are free from all causticity.

In the slightest forms of conjunctivitis one or two protargolages, will usually lead to cure in the course of two or three days. In these cases it is not even necessary to allow the strong solution of protargol to enter the eyes. **Brossage,** the soaping (**savonnage**) of the outer border of the eyelids and of the lashes with a brush charged with the solution, produces an ample imbibition, so that the small amount of protargol which penetrates between the eyelids brings about rapid aseptization of the surface of the conjunctiva.

At home the patient may use the following collyrium in his eyes three to six times a day:

Argyrol	0.25
Distilled water	5.00

Very satisfactory in these cases is the use of boric lotion or even of simple boiled water. It is sometimes surprising to observe the remarkable effect of this simple external application of protargol, combined with instillations of argyrol. If the treatment has been regularly carried out, complete cure results in a few days. But if the cauterizations be discontinued prematurely, or if too long an interval be left between successive applications before complete cure, there is a risk of relapses, which may entail, as their consequence, a chronic conjunctivitis. Since

the long-continued employment of protargol or of argyrol sets up a local tolerance, it is well to combat this tendency by changing the treatment from time to time. It is also important to explain to patients the necessity of proper home surroundings and to get them to practise as perfect an asepsis as possible.

In applying remedies to the eyes it is advisable to avoid the use of sponges, eye-cups, syringes, and so forth. Lotion should be applied by means of a pledget of aseptic wool, steeped in the solution, borated or otherwise, and preferably used rather hot.

Patients should be admonished to cleanse the face and the hands frequently. The washings should always be undertaken at least twice a day, that is when going to bed and after getting up in the morning. After the ablutions, the eyelids should be carefully dried, and even smeared with a little vaselin, especially if there be any tendency to ulceration or inflammation. Droppers should be carefully cleansed after every instillation and be wrapped in a morsel of sterilized wool until wanted again.

The patient should remain indoors if the secretion is very abundant and there is photophobia. At the same time it must not be forgotten that fresh air and light are more wholesome than close and overheated atmospheres. Smoked glasses and dressings should be employed as little as possible; they are really indicated only when there is photophobia or corneal complications.

When a trivial conjunctivitis has resisted treatment by the salts of silver for several days, a 1 to 2 per cent. collyrium of zinc sulphate should be tried, more especially if diplobacilli are found in the secretion.

Ophthalmoblennorrhea.

Clinically, it is certain that in the early stages many acute and violent inflammations of the conjunctiva, due to the Weeks' bacillus or to the pneumococcus, may be

mistaken for purulent conjunctivitis. But at the end of a few days the distinctive course of the disease determines the true diagnosis.

At the commencement of an acute and intense conjunctivitis, if the bacteriologic examination has not yet been made, we content ourselves, for the first day, by instilling 10 per cent. argyrol, the oftener the more violent the attack. In the intervals, we prescribe frequent washings with boric lotion or, preferably, with potassium permanganate, 1:3,000. This last solution possesses a manifest action upon suppuration. Large copious irrigations with a special instrument have given excellent results, when they have been made by a practised hand (Kalt, Leber, etc.); but the introduction of rigid irrigators into the conjunctival sac is very painful and sometimes produces erosions of the corneal epithelium. In addition to this, once or twice a day protargolage is carried out, and by this means the edges of the eyelids are cleansed and rendered aseptic, while a little protargol penetrates between the eyelids. Inflammation of the conjunctiva due to Weeks' bacillus or to the pneumococcus, are by these measures almost completely cured in five or six days.

It must be admitted that true purulent ophthalmia is caused by the gonococcus. Those who affirm that they have never been disappointed with this or that alleged specific will assuredly be surprised some time by one of the fulminating forms which lead in the course of a few days to more or less extended ulceration of the cornea, leaving behind thick leukomata, if not perforation and atrophy of the eyeball.

It is important for every physician to thoroughly familiarize himself with the proper treatment in those gravest of all cases in which a miserable, weakly baby, born before term, is brought with a very violent attack of **ophthalmia neonatorum.** The child is so small and the lids so swollen that it is impossible to evert or even to open them. Under such circumstances cauterizations

with 2 per cent. silver nitrate usually produce so violent a reaction that there follows enormous chemosis and pseudomembranous formations, which only aggravate the situation. In these cases the fight is of the most difficult description. We must summon to our aid all the resources of our therapeutic arsenal, never forgetting that nothing must be done that could by any possibility do harm. Treatment directed to the general state and the nutrition of the baby needs all the solicitude of the physician and the accoucheur.

From the commencement the ophthalmic surgeon should devote himself to securing the most fastidious asepsis and antisepsis. The eyes should be frequently cleansed with lotion, the exact nature of which matters little, provided it is not iced, for such subjects bear cold badly. Cauterizations should be practised with great prudence, inasmuch as the nutrition of the cornea is already defective, and the least traumatism or too violent a cauterization may provoke or facilitate the production of a corneal ulceration, which may lead to the most disastrous consequences. Under these conditions the duty of the practitioner is as difficult as it is delicate. If he acts with undue energy, he risks doing mischief, while, if he does not act energetically enough, the malady itself will make such progress that he will have difficulty in mastering it.

If it was natural in von Graefe's time to endeavor to combat an intense phlegmatic process by violent cauterizations, so as to destroy the morbid tissues, to-day, thanks to the work of Neisser, we know that the disease is caused by the penetration of the gonococci into the epithelial cells and even into the subjacent tissues. More than fifty years ago von Graefe laid down very precise and detailed rules for the application of silver nitrate. He believed this agent to be formally contraindicated whenever the secretions assumed the aspect of false membranes. On the other hand, in purulent and blennorrhagic ophthalmia, he recommended cauterizations with the miti-

gated stick, and as a condition essential to their proper action he maintained that each fold of the mucous membrane should be submitted to the contact of the caustic. An eschar, of which the depth was to be estimated by the clinical sense and tact of the practitioner, was essential to success, but this eschar was to be got rid of as quickly as possible by the repeated application of iced compresses. Cauterizations were to be resumed as soon as the eschar had fallen, or partial touchings were to be made on the parts laid bare. Since the times of Desmarres, cauterizations by means of a brush or by instillation have prevailed. Silver nitrate was the agent always employed for this purpose.

By a series of experiments, Neisser showed that certain tissues immersed in solutions of the organic salts of silver were deeply penetrated by the latter, whereas solutions of the nitrate caused a coagulation of the albuminous elements of the tissues, which thus opposed a barrier to the further penetration of the salt. Now the gonococcus penetrates not only into the epithelial cells, but also into the deeper tissues. By frequently repeated instillations of argyrol, no harm can be done; the mucous membrane accustoms itself to the remedy, and becomes less sensitive to any cauterizations which may be afterward necessary. Those who look after the patient gradually become accustomed to the delicate manipulations which may later devolve upon them.

Many authors advise against cauterizations during the first stages of purulent ophthalmia, especially when the inflammatory phenomena are very violent. It is much better to commence the treatment by instillations, frequently repeated, of argyrol, 10 or 20 per cent., which has no caustic action, but, on the contrary, is calmative. In addition to this, **protargolage** is carried out twice a day without everting the eyelids.

If the eyelids are much swollen and very hard, the best means to render them supple is to instil a drop of dionin,

the effect of which is to provoke a considerable afflux of tears and of serum. At first, the eye appears more swollen, but after several hours the eyelids become softer, and on the following day it may be possible to evert them without particular difficulty. Among weakly children dionin, like all opiates, has a narcotic action of so powerful a nature that no more than a single drop should be placed in the eyes.

As soon as the eyelids have resumed their pliability, the eye should be bathed several times a day with 20 per cent. argyrol. If, despite this treatment, the eyelids remain indurated, we should not hesitate to practise, twice a day, cauterizations with 2 or 3 per cent. silver nitrate, and to facilitate eversion of the lids by cutting the outer canthus with scissors. Should the patient be seen as late as the sixth or eighth day, with eyelids as hard as cartilage and the corneæ already clouded, it is perhaps imprudent to tarry over mild measures. Recourse to cauterizations with 2 per cent. silver nitrate, repeated twice a day, should not be delayed. The silver should be preceded by dionin, the action of which may be heightened by the abundant employment, every half-hour, of 15 per cent. argyrol, which acts both as an antiseptic and as a calmant in these cases.

Iced compresses have no action upon the gonococcus and merely augment the induration of the eyelids. Hot compresses, on the contrary, relax the tissues, facilitating the resorption of exudations and the escape of the pus.

It is essential to partly open the eyelids every half-hour in order to allow pus to escape, and to aid escape by means of a tampon of wool steeped in a solution of boric acid or of potassium permanganate. The use of any instruments, such as elevators, syringes, irrigators, etc., must be most carefully avoided, since they might cause injury to the cornea.

After the eye is cleansed, one or two drops of argyrol should be instilled between the lids. By repeating these

washings and instillations regularly every half-hour, the evolution of the morbid process may probably be stopped, and in every case we may feel certain that no harm has been done. Again, time has been gained, the patient has collected his energies, and has become accustomed to the applications, so that energetic cauterizations may be made more easily.

It is very important to encourage the infant to open his eyes of his own accord, and when this result, apparently so simple, has been attained, cure is in sight, since in all ocular suppurations the influence of light and air is beneficial. Some interesting experiments have been made in Russia on the action of sunlight in suppurating affections of the eye. It is bad practice to bandage the eye in cases of conjunctivitis. If corneal complications are present, simple hot compresses, changed every half-hour, suffice. Once the eyelids have recovered their pliability, the cauterizations should be applied to the everted conjunctiva, and if the suppuration is not speedily reduced by protargol, 2 per cent. silver nitrate or 3 per cent. ichthargan should be substituted for the milder organic preparation.

Tolerance is a factor that must always be reckoned with in therapeutics. It is well to be patient and persevering in the application of certain medicaments the employment of which must extend over a long period, but it is also well to understand how these applications to the eyes should be graduated and changed. In general, after the marked improvement during the first few days there is a slackening in the therapeutic result. The infective elements and the cells have become habituated to the medicaments. Under these circumstances the doses must be increased, the local remedy changed, or the soil be modified. Even with silver nitrate, after a more or less prolonged series of cauterizations, tolerance is produced. To avoid this tolerance toward silver nitrate Bettremieux has proposed the use of very dilute nitric acid lotions. The same effect is produced by a concen-

trated solution of sodium chlorid, and also by an energetic lavage with wool steeped in a solution of mercury cyanid, 1:1,000. But it is equally easy to change the local application or to vary its method of application. When tolerance is produced toward protargol or argyrol, we may always have recourse to silver nitrate in a strength not exceeding 2 per cent. This involves no danger. Ichthargan, a combination of ichthyol and silver, occupies, as it were, a middle place between protargol and silver nitrate. Generally speaking, protargol and argyrol, properly applied, lead so quickly to cure that we need rarely employ other medicaments.

It is not uncommon to observe in children, to all appearance quite healthy, attacks of conjunctivitis, commencing with alarming symptoms, which are really benign affections developing upon a strumous soil. Bacteriologic examination is all important in these cases, so as so exclude the gonococcus. If the gonococcus is absent, violent cauterizations must be carefully avoided, since they will merely complicate and aggravate the mischief. Frequent instillations should be made, every hour or half-hour, of 10 per cent. argyrol, and stronger cauterizations should be reserved for the moment when inflammatory symptoms begin to regress.

It is not easy, especially in a newly-born baby, to make the diagnosis of struma or lymphatism. Thanks to dionin, which has not only the valuable therapeutic properties described earlier in these pages, but also a diagnostic quality, the diagnosis of lymphatism may be made in a subject whose antecedents are still unknown to us. Among lymphatic subjects dionin produces an excessive lymphagogic effect when dropped into the eye. Thus, the eyelids and the conjunctiva become swollen, and an abundant secretion of tears and of serosity results. On the other hand, among nonlymphatic subjects, dionin produces merely a marked redness, lacrimation, and trifling edema of the conjunctiva.

It often happens that a well-nourished baby is brought with a fairly severe attack of conjunctivitis. The eyes are carefully treated with protargol. Some minutes after the application, the eyelids become tumefied, and the conjunctiva covered with a thick, whitish layer, recalling the aspect of a false membrane. We have here an infant in whom the mildest cauterization provokes the formation of false membranes, which impress the conjunctivitis with a quite exceptional gravity, all the greater if we happen to have employed for cauterization a strong solution of silver nitrate. In such a case, if dionin be applied, marked swelling of the eyelids and conjunctiva is produced, and this is followed by the escape of abundant yellowish discharge, intermingled with which are fibrinous filaments; and, finally, after several hours, the pseudomembranous exudation which has been formed becomes detached from the conjunctiva. The therapeutic result is as interesting as the diagnostic information. The indication furnished by this little experiment is precise, namely, to proscribe all cauterizations and to employ only frequent instillations of 5 per cent. argyrol.

These facts show us that dionin is capable of rendering great service in the treatment of the most various kinds of inflammation of the conjunctiva. The considerable afflux of tears and of lymph provoked by its local application produces a washing, an energetic detersion, not only of the surface of the conjunctiva, but also in the depths of its tissues. The result is seen in the elimination of infective elements and toxins, as well as in a renewal of the tissues under the influence of the powerful afflux of the nutritive elements induced by the remedy. Whenever we see a conjunctivitis, whatever its nature, which resists unduly long the action of the topical remedies applied, we should never hesitate to instill several drops of a 5 per cent. solution of dionin. In almost every case a most salutary revulsion is thereby set up, after which local remedies exert an action at once more rapid and more marked.

The most serious complication of purulent ophthalmia is not prolonged suppuration, but ulceration of the cornea, which may entail as its consequence loss of the eye. In former times the corneal complications of purulent ophthalmia were responsible for the majority of the cases of blindness.

The treatment of **corneal complications** is a very delicate procedure. Every hour two or three drops of the following solution should be dropped into the eye:

Dionin	0.10
Pilocarpin chlorid	0.25 to 0.10
Distilled water	10.0

At the same time the use of 10 per cent. argyrol every hour must be continued.

Cauterizations with the brush, practised twice a day, must also be kept up, except when they are badly borne, when they may be replaced by applications of iodoform ointment. The galvanocautery may render great service in bringing about the prompt cicatrization of cornea ulcerations.

The other ocular complications of gonorrheal ophthalmia are usually of late onset. They include **iritis,** and more or less generalized **arthritis,** even in newly-born babies. They should be treated by sodium salicylate and by collargol and other measures employed in iritic cases.

Adult gonococcal infection is the more alarming the nearer it takes place to the acute period of the blennorrhagia. Once that has passed into the chronic state, it is liable to provoke merely the less serious forms of inflammation of the conjunctiva. It thus becomes easy to understand that, in accordance with this law, cases of ophthalmia neonatorum will be less severe the longer the accouchement happens after the vaginal infection. This may even explain why cases of gonococcal ophthalmoblennorrhea run such very different courses. The virulence of gonococci may be more or less attenuated by time,

and their presence alone may not be the only element capable of influencing prognosis.

Thanks to the penetrating and harmless effect of the organic salts of silver, gonococcal purulent ophthalmia, both in adult and in the baby, may in the majority of cases not only be cured, but strangulated, so to speak, in several days. Every grave complication may be avoided, although the more or less purulent secretion, which may persist for from four to six weeks, must still be fought. In order to accomplish this, treatment must be applied night and morning without interruption until the disappearance of serious symptoms. An intelligent, attentive, and devoted nurse is one of the most important elements in successful treatment, and much of the credit of a happy result is due to the nurses who day and night have applied treatment regularly and punctually.

Argyrol Immersion.—In cases of gonococcal ophthalmia in adults, argyrol is best applied by means of an eye-bath. The patient's head is thrown back, the eyelids are widely opened by the fingers, and four or five drops of 25 per cent. argyrol are put into the eye in such a way as to fill the conjunctival sac completely and to immerse the entire eye in the solution. The argyrol is quite painless, as shown by the fact that patients look forward to the immersion. The eye does not even become red. When the treatment has lasted several minutes, light massage of the eye is made through the lids, so as to facilitate the escape of secretions and the resorption of superficial infiltrations.

It may be noted that if a 25 per cent. solution of protargol is substituted for argyrol of the same strength in the eye-bath, the patients complain of more of less violent pain.

Protection of the Sound Eye.—Many procedures have been praised in order to preserve the sound eye against contamination. For example, a permanent occlusive dressing has been employed for the purpose, or the orbit has

been completely covered by a large domed glass, kept in place by means of a caoutchouc bandage. It is essential to warn the patient and his attendants of the possibility and gravity of such a contamination, and to advise constant cleanliness, which is generally sufficient when dealing with intelligent persons. In case of an alarming slight redness accompanied by conjunctival secretion, a few instillations of argyrol are indicated.

Buller's shield (Fig. 3) is very useful, especially in hospital practice, in unilateral purulent inflammation of the eyeball, particularly gonorrheal ophthalmia, diphtheritic ophthalmia, and acute trachoma. It consists of a watch-glass, held in place by adhesive plaster attached to the side of the nose, the cheek, and forehead. The eye may be readily inspected through the center of the watch-glass, and yet be thoroughly protected from infection by the purulent secretions of the affected eye, and the unfortunate patient is spared the necessity of groping in darkness. It is described in many different ways, and all kinds of modifications have been called "Buller's shield," or "bandage." (Just prior to Dr. Buller's untimely death, the editor had his personal assurance, that he had never seen fit to change the bandage from the form described in his original communication in 1874.)

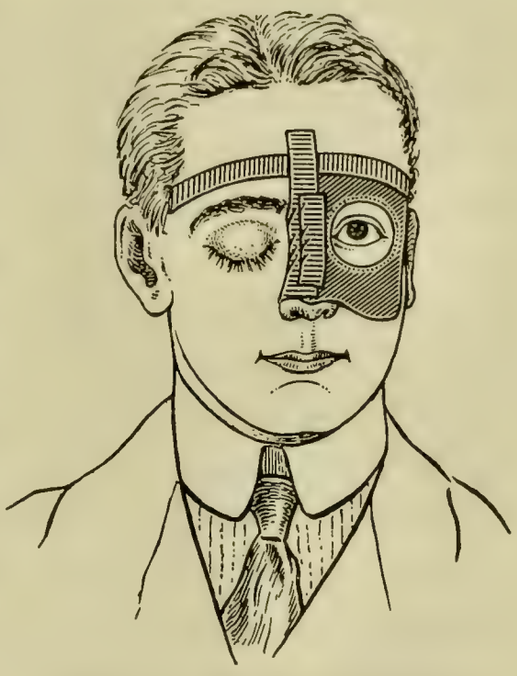

Fig. 3.—Buller's Shield.

Buller's description[1] is as follows: "It consists of a square piece of mackintosh into the center of which a watch-glass is fastened and of three strips of adhesive plaster. The mackintosh is trimmed to fit the nose and forehead of the patient, and should extend across one side of the fore-

[1] Lancet, London, 1874.

head about half an inch above the eyebrow, and downward nearly to the tip of the nose, the nasal portion reaching a little beyond the median line. A strip of adhesive plaster about an inch in width, and long enough to reach from just in front of one ear to a corresponding point on the opposite side, is applied along the upper border of the shield. The second strip may vary in width according to the height of the nose, and must be snipped in three or four places, in order that it may be adapted to the uneven surface upon which it rests, the lower part only slightly overlapping the edge of the shield. For additional security a third and somewhat shorter strip is placed along the dorsum of the nose. The eye is thus completely protected by a waterproof shield, the upper and inner sides of which are firmly adherent to the skin of the forehead and nose, while the lower and outer borders are free, so that the eye is exposed to the air almost as freely as when an ordinary shade is worn. Moreover, the surfaces of the watch-glass being parallel, vision is not interfered with, and the patient is able to attend to the affected eye. As the strips of adhesive plaster become softened in the course of a few days by the warmth and secretion of the skin, they require to be renewed. This may be done as often as necessary without any difficulty or danger of infecting the healthy eye. The glass does not become dimmed by an accumulation of moisture from the conjunctiva and skin of the face, as is the case with Snellen's closely fitting glass shield; nor is the protection afforded by the apparatus at all the less perfect in consequence of its outer and lower borders being free."

Metastatic Gonorrheal Conjunctivitis.—The gonococcus may be carried by the blood and deposited in the conjunctiva, just as it may be in the iris and the joints. These different manifestations may be present at the same time, and they often recur with articular attacks. The conjunctival secretion seldom contains the gonococcus. The eyelids are but little swollen, and there is little or no dis-

charge from the eye. Cure is effected in two or three weeks by general treatment, aided by a few instillations of argyrol.

Gilbert, of Munich, has lately advocated instillations and lotions of **beef-serum** in the treatment of ophthalmia neonatorum. The serum must be stored in ice, since it does not keep well. It renders the gonococci as harmless as simple saprophytes, and when used with a few cauterizations with silver nitrate, speedily checks the purulent secretion.

Another remedy that has recently been recommended by Adam, of Berlin, is **lenicet,** that is, **acetate of aluminium.** The medicament is mixed with euvaselin as a 10 per cent. ointment, which is applied to the eyes every two hours, day and night.

Prophylaxis of ophthalmia neonatorum by Crede's method has been amply justified. By means of a drop of 2 per cent. silver nitrate, applied to the baby's eyes at the moment of birth, infections have been reduced to 2 per cent. Protargol also has proved its superiority from a prophylactic point of view. Over silver nitrate it has an advantage, *viz.*, that it does not provoke in predisposed subjects a catarrhal conjunctivitis, which may last for ten or fifteen days.

Accoucheurs cannot be too strongly advised to apply argyrol to the eyes of all newly-born babies, and to follow this with a careful protargolage of both the eyes, but without seeking to make the solution penetrate into the conjunctival sac, for the gonococci are most frequently lodged on the edge of the eyelids at the moment of birth, and it is only later that they gain access to the conjunctival sac. Savonnage of the eyelids with protargol is admirably adapted for preventing purulent ophthalmia. The results obtained by Rubesca at the Prague clinic were very satisfactory. Protargol was employed to the eyes of 1,100 babies, who were kept under careful observation day by day. There were, in all, four cases of ophthalmoblennorrhea, two of which were admitted from outside. As regards

the other two, one was attacked after a very tedious confinement in a mother affected with blennorrhea of the cervix uteri. Notwithstanding this fact, the conjunctivitis was not observed until the seventh day. The fourth baby was affected on the seventh day. These two cases were, therefore, secondary infections, since it is recognized that primary infections do not occur later than the fifth day.

Quite recently Herff has published statistics of the cases observed at the Basle Maternity Hospital. During two years, when silver nitrate was replaced by protargol (10 per cent., among 3,000 births there was not a single infection. It follows, then, that during the four or five years that protargol has been employed as a prophylaxis there has not been in upward of 5,000 births a single primary ophthalmia. In a fresh series of births, protargol was replaced by argyrol or sophol (more painful) with identical results.

Alcoholic Conjunctivitis.—A form of blepharoconjunctivitis is seen very frequently in alcoholic subjects. Lacrimation is so pronounced that one is often inclined to believe that probing of the nasolacrimal duct will be necessary. No result, however, will be obtained by such treatment. Local treatment with protargol, zinc sulphate, or lead acetate, produces but a passing improvement, and the least alcoholic excess brings about an abundant oozing from the conjunctiva which escapes by the inner or outer angle of the eyelids, of which the edge becomes red and corroded by the persistent and long-continued secretion. There is one way only of curing these patients, and that is by forbidding all use of alcohol This form of conjunctivitis is little known. It proves that if an infective agent has a specific importance, one must also count with the individual soil and the modifications which it undergoes by the environment.

Diphtheritic conjunctivitis formerly led to long discussions, in which the differential diagnosis from such conditions as croupal, croupous, diphtheritic, and diph-

theroid conjunctivitis was debated. The transcendental discovery of the Roux-Behring serum has put an end to these long and futile digressions.

At the present day, in a case of violent inflammation of the conjunctiva, when the mucous membrane is covered with a grayish-white pseudomembrane, whether this is but slightly adherent (croupal) or infiltrates more deeply the conjunctiva (grave variety), without awaiting the results of a bacteriologic examination, we should at once inject **antidiphtheritic serum** in a dose of 5 to 10 c.c., according to the age of the patient, and repeat the injection every day. By the third day the membrane loosens and becomes detached, and at the same time the other symptoms show great improvement. Elimination of the exudations may be aided by making one or two applications of dionin and also by hot compresses (never iced ones). Argyrol, 10 per cent., should be dropped often into the eye, and protargolage should be practised every day. Pyocyanase is also another remedy that, when dropped into the eye, hastens the melting of the false membranes—it is a powerful bacteriolytic agent that deserves to be widely tried. Should adhesions between conjunctiva and eyeball threaten, a little iodoform ointment should be placed between the eyelids several times a day.

By these measures, if the malady has been treated early, prompt cure is obtained, but if the patient seeks treatment for the first time when the disease is already far advanced, the task becomes much more arduous. Ulceration of the cornea may bring about complications of an even more serious nature than those of purulent ophthalmia, such as hernia and entanglement of the iris, expulsion of the lens, and loss of the contents of the eyeball. Ulceration of the cornea should be treated by the usual local applications; as, for example, the galvanocautery, 50 per cent. potassium permanganate, pyocyanase, etc.

Among twenty-five cases treated by serum, nineteen

were cured, six suffered from perforation of the cornea, and two of the latter succumbed to pneumonia. Among seventeen cases not treated by serum, five died (Dutoit-Haab).

Spring catarrh has been exhaustively studied by Saemisch and by Horner. It is an affection of very slow evolution, characterized by marked recrudescences, especially in spring and summer. It produces characteristic changes both at the pericorneal limbus and on the tarsal conjunctiva, but, on the other hand, spares almost completely that part of the conjunctiva which is not adherent to a solid base, as the tarsal plate or the corneal border. Although the affection is certainly of parasitic nature, yet its special microorganism is not yet known.

Spring catarrh generally assumes the episcleral type, in which a gelatinous, lardaceous pad, of yellowish color, develops on the outer and inner side of the cornea. It may even surround the cornea, and produce an opaque zone in the limbus, like that of an arcus senilis, but prominent. This form, which has been called by Hirschberg phlyctenula pallida, is often confused with a corneal phlyctenule, but it is much more persistent and it never develops pustules or ulcerates.

The tarsal conjunctiva, especially that of the upper lid, is often affected by the changes of spring catarrh. The surface of the conjunctiva is then covered with large papillæ, flattened and pressed against one another, so as to form a polygonal pavement, sometimes of an admirable regularity. The surface is shiny, as if covered with oil or milk.

Until the last few years, the treatment of this curious affection amounted almost to nothing. All the irritant, antiseptic collyria seem to have a rather unfavorable action.

The tarsal form of spring catarrh is often mistaken for trachoma. Treatment has little action upon the papillomatous and sclerous growths of the tarsus. The radical excision must be practised. Although, unfortu-

nately, relapses are very frequent, this is the only means of reaching a relative cure. The hypertrophied tarsus must be excised in all its thickness; the remains of the tarsus are then covered with conjunctiva from the bottom of the culdesac, sutures, which are to be knotted on the skin surface, being employed to keep the parts in place. When a choice is possible, autumn should be chosen for performing the operation.

In the pericorneal variety—the gelatinous hypertrophy of the limbus—massage with mercurial lanolin and adrenalin should be prescribed:

Adrenalin, 1 : 1,000..... 30 drops.
Mercury cyanid, 1 : 5,000..... 4.0

A drop of this liquid should be placed in the eyes every two hours, and at night after one or two instillations, the cornea should be massaged for some time with mercurial lanolin. Occasionally 1 or 2 per cent. guaiacol ointment should be substituted for the mercurial preparation.

In a slight case, it is true, rapid cure was obtained by combining the adrenalin treatment with applications of radium, although this case presented difficulties, owing to the age and indocility of the patient. Instances of cure of spring catarrh by X-rays have been reported by Sulzer and others.

Tuberculosis of the conjunctiva generally takes the form of bleeding granulous ulcerations upon the palpebral conjunctiva, with dirty-red, jagged, and lardaceous edges. Confusion may arise with chancre of the conjunctiva, which, like tuberculosis, is accompanied by induration of the preauricular glands. But in the one condition spirochetes are found and in the other the bacillus of Koch.

Tuberculosis of the conjunctiva generally calls for surgical measures, aided by a few subconjunctival injections of guaiacol and dressings with iodoform ointment. In these cases the value of general treatment must not be overlooked.

Tuberculosis of the conjunctiva may be confused with **Parinaud's infective conjunctivitis,** a morbid entity well recognized to-day, although its essential cause has not yet been identified. At the same time it seems to be established that this affection of the conjunctiva is due to a contamination of animal origin. The condition is usually limited to one eye, in which it resembles palpebral tuberculosis, with which it also agrees in being characterized by granular, nonulcerated granulations, and little ulcerated vegetations. The glands are markedly infiltrated and often suppurate, which is very uncommon in tuberculosis. In one typical case Koch's bacilli were found in the pus from a gland (Darier).

Parinaud's conjunctivitis tends toward spontaneous cure. A more rapid result, however, can always be secured by the knife and the curet used freely upon the conjunctival granulations and in the depths of the suppurating glands. As in tuberculosis of the conjunctiva, no harm follows these interventions. When operation is refused, dependence must be placed on iodoform or guaiacol ointment, together with collyria or argyrol. In the case of conjunctival tuberculosis, we may also employ injections of tuberculin.

Granulous Conjunctivitis. Trachoma.

Diagnosis.—There is no affection the forms and development of which are more multiple than granulous inflammation of the conjunctiva. Here, more than anywhere else, we must individualize and treat the patient at the same time that we must search, by all the means indicated by the particular circumstances of the case, to destroy locally the infective element as completely as possible. The latter point dominates the situation, and is the pivot around which all therapeutic efforts must turn, inasmuch as granulous conjunctivitis is a local microbic infection, as are lupus, superficial epithelioma, and tuberculosis of the skin.

Conjunctival granulations must be distinguished from follicular elevations, so common among young subjects. **Follicular conjunctivitis** appears to constitute a soil favorable to the evolution of a superadded granulous infection. It has been said that follicular conjunctivitis is merely the first phase or an attenuated form of the granulous infection. Although the pathogenic agent of trachoma has not yet been found, it is prudent to consider, from the therapeutic point of view, that in doubtful cases, follicular conjunctivitis should be treated as if it were of trachomatous nature, but from the prognostic and statistic point of view, it should be classed as a different malady.

From the practical standpoint, the chief modalities may be grouped in two categories: acute granulous conjunctivitis, inflammatory; and the chronic form, atonic or characterized by subacute attacks or trachoma. The first may be only the prodromal stage of the second, and the latter occur by paroxysms which bring back the acute form.

The diagnosis becomes difficult only when contrasted with follicular conjunctivitis, and that merely during the period when granulous conjunctivitis is still cured by caustics. If what has been believed to be a follicular conjunctivitis resists for several months a seriously applied treatment, we may be almost certain that we have to do with a trachomatous affection, and it should be treated as such.

Simple follicular conjunctivitis shows follicles only in the lower culdesac. This form speedily yields to good hygiene and the use of collyria of lead acetate. On the contrary, when we see well-marked granulations upon the tarsal cartilage and upper culdesac, we are almost certainly dealing with a specific, contagious, granulous conjunctivitis.

In the forms accompanied by abundant discharge, we must attempt to check all secretion and abate the inflammatory phenomena before we proceed to surgical

treatment. In this way we operate upon a well prepared field, and thus obtain the maximum result with the minimum of operative traumatism.

The salts of silver are those upon which most dependence should be placed to check the suppuration. Argyrol may be said to occupy the first place, owing to its powers of penetration and the little pain which it provokes. When dropped into the eye at frequent intervals, it promptly checks suppuration. Protargol may be employed instead when signs of tolerance to argyrol are established, and if protargol, in its turn, becomes less efficacious, we may pass forward to use cauterizations of silver nitrate, which is more caustic and mordant, and better able to penetrate the fibrous envelope of the granulations.

Copper sulphate has rendered such immense services in the treatment of trachoma that it has been looked upon as a specific against granulations Cauterizations by this agent, however, are extremely painful. Two or three drops of cocarenalin should be dropped into the eye before the application, and the copper should be used with great care. The copper may be employed as a crayon, a crystal, or as a 10 per cent. solution in glycerin, to which 2 per cent. of guaiacol is added. The last-named method is less painful than the others.

There is an increasing tendency to the surgical treatment of trachoma; and copper sulphate has been more or less supplanted by sublimate and mercury cyanid. Many authors believe that the best treatment of trachoma is *frottage* of the granulations by means of a tampon of wool steeped in a solution of sublimate, 1 : 1,000 or 1 : 500, which was originally merely the complement of surgical intervention. Following out the same order of ideas, massage of the granulous surface by inert powders, such as sugar or boric acid, has been justly praised. Good results follow massage with dionin or, better, peronin powder, which is insoluble. By these means we act mechanically by the rubbing, and physiologically by the enormous

afflux of lymph, which irrigates and renders aseptic the infected tissues. After the operation, we instil every hour 10 per cent. argyrol, and on the following day we cauterize with silver nitrate or copper sulphate. The clinical indications make it evident that all cases are not suitable for the same treatment.

Acute secreting granulous conjunctivitis may be treated successfully by the salts of silver. By means of these cauterizations, the discharge becomes so slight that patients believe themselves to be cured, and when they attend again, after an interval of several months, we find that they are affected with the chronic form of the disease, with pannus. The patients should be accustomed to the idea of radical treatment of the disease, while the operative field is put in the best condition possible. Schiele has recently recommended the treatment of trachoma by hydriodic acid, and has by that means obtained some remarkable cures.

The Surgical Treatment of Trachoma.—The importance of the mechanical or surgical treatment of trachoma was recognized even at the dawn of medicine. Hippocrates and his successors rubbed away and even excised with the cautery or with various caustics the conjunctival granulations.

In docile and courageous patients, who will attend regularly, the disease may be completely cured by the medical measures already described, but whenever such treatment cannot be applied properly, it is better to resort to surgical intervention.

Recurrences are to be apprehended and contagion is possible so long as the smallest granulation remains in the conjunctiva. Granulations hidden away in the upper culdesac may not only escape the action of remedies, but may also escape the attention of the operator, and may thereby account for unaccountable relapses.

When it was once well-established that the really specific agent of the disease was the granulation, it became

natural to think of a rapid and radical cure by removing the whole of the diseased tissue. In 1854 Pilz, of Prague, was the first to translate this idea into action by incising each granulation with a cataract-needle and then expelling the contents with a curet. When faced by a diffuse gelatinous infiltration, Pilz practised scarifications of all the infiltrated tissue, and evacuated the contents by pressure. Treatment was completed by the use of copper sulphate. The results obtained by Pilz were surprising. That he found few to imitate him was due to the fact that at the time when his communication made its appearance, the ophthalmologic world was dominated by the views of von Graefe. Copper sulphate held its preeminent position. In 1857 Borelli recommended that the granulations should be removed by a kind of wire brush, while a metallic rasp was employed by Anagnostakis and Fadda. Quite recently, Schraeder and others have reverted to brossage.

The galvanocautery and the **thermocautery** have found many partisans. **Electrolysis** has been praised by Lindsay Johnson and more recently by H. Coppez. But the most popular operations have been the **resection** of a larger or smaller piece of the diseased conjunctiva and of the tarsal cartilage (Galezowski, Heisrath, Stephenson, Kuhnt, Eversbusch, Schwab), **expression** (Knapp, Stephenson, Kuhnt) or **grattage** of the follicles. Conjunctival excision should be followed by medical treatment until there remain no granulations, a precaution in the absence of which recurrences are likely to be frequent.

The rational treatment of trachoma should aim at the prompt and complete **destruction of the granulous infiltrations,** at the same time sparing as much as possible the healthy tissues. This desideratum was reached by Pilz. Operation in slight cases may be performed quite well under the local anesthesia given by cocain, and we may feel assured that not the smallest granulation will lurk even in the most out-of-the-way corner of the conjunctival sac. The eyelid is everted twice upon itself by means of a

special toothed forceps (Fig. 4), so as to expose the bottom of the culdesac, in order that each granulation may be scraped and curetted the more readily. After that, free washing with 1 : 1,000 sublimate is necessary, followed by cold compresses.

After three or four days the raw surface becomes covered with epithelium, and tiny white cicatrices are seen to occupy the site of former granulations. Although before operation prominent granulations may prevent

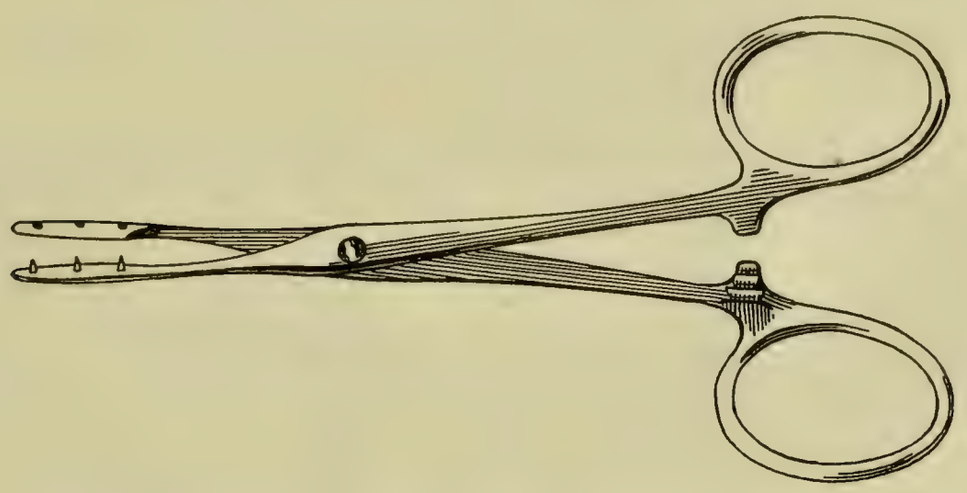

Fig 4.—Toothed Eyelid Forceps.

scarcely a trace of healthy conjunctiva being recognized, after their destruction by the means described it can be seen that an almost normal mucous membrane can be constituted from the remains of the conjunctiva. It is advisable to continue for some weeks after operation local treatment—at first with sublimate, then with copper sulphate, and, finally, with tannin.

In severe cases we proceed to a surgical operation as complete as allowed by our modern surgical knowledge. Before operating, we must make ourselves familiar with the topographic distribution of the granulations by a most careful examination of all the nooks and crannies of the surface of the conjunctiva. By this means we know as much as we can beforehand upon what parts the surgeon should concentrate his efforts, for once the operation is commenced hemorrhage, often quite abundant, may con-

ceal some of the granulations. At any price, we must avoid leaving behind so redoubtable an enemy as the infective agent of trachoma.

Under chloroform anesthesia, the external angle of the eyelids is divided by a stroke of the scissors whenever it is not a simple matter to evert them readily. This slight operation will be found to be necessary in about one-half of the cases. At the same time it is rare that we are compelled to apply sutures to keep the parts open (this need only be done in cases of atresia of the palpebral fissure accompanying entropion).

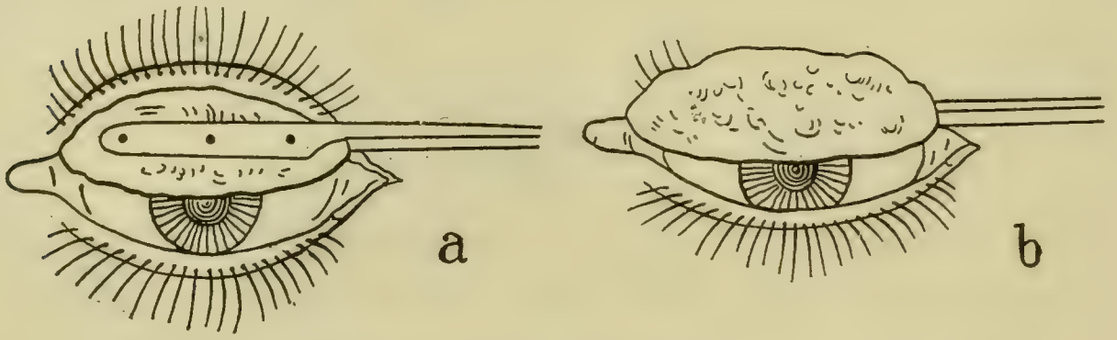

Fig. 5.—Eversion of the Eyelid with Toothed Forceps.

If the caruncle is too much infiltrated, the simplest plan is to remove it with scissors. If **pannus** be very marked, there need be no hesitation in treating it very cautiously with the curet, scraping from the center toward the periphery, and carefully avoiding sound tissue. This delicate stage of the operation, which is called for in about 14 per cent. only of the cases, should be completed by a careful washing with sublimate.

Then, with the forceps shown in Fig. 5 we secure perfect eversion of the eyelid and at the same time a support for the conjunctiva, which is usually folded and flabby. In order to avoid tearing the tissues, the eyelid, as shown in Fig. 5a, should be seized a couple of millimeters from its free border. The instrument being thus held parallel to the edge of the lid, a movement of rotation around the axis of the forceps pushed well behind the eyeball

will expose the stretched conjunctiva completely without at the same time tearing the membrane (Fig. 5b). Under this traction succulent granulations are apt to burst. Scarifications are cautiously made in such a way as to incise all the granulations. If the latter are few and discrete, a bistoury or a discission needle will suffice for the purpose.

If, on the contrary, all the conjunctiva and the cartilage are infiltrated, it is advisable to employ the **triple-bladed knife** shown in Fig. 6. This instrument has the advantage of allowing the scarifications to be made quite parallel and more rapidly. The depth of the incisions

Fig. 6.— Triple-blade Knife.

should be proportionate to the thickness of the granulous infiltration, the object being to expose the contents of the granulations, while sparing the conjunctiva as much as possible. The gelatinous contents of the granulations escape through the scarified conjunctiva, whence they must be most carefully wiped away.

After the parts have been minutely treated with the curet, nothing remains to be done except to practise complete brossage of the scarified and curetted surface. This may be done with a simple small toothbrush, the bristles of which are stiff and short. The brush should be disinfected before it is used by prolonged immersion in formol-alcohol, followed by a solution of sublimate or mercury cyanid, 1:500. When carrying out brossage, the brush should be moistened as frequently as possible in a 1:50 solution of the cyanid. It should be used vigorously, in order to reach all infiltrated tissue, but without dragging away and tearing the tongues of conjunctiva spared by the scarifications. When we are satisfied that all diseased parts have been scarified, scraped, and brushed. the forceps are removed. But it must be remem-

bered that the forceps, narrow though they be, may have concealed some diseased spots, which are easy enough to destroy, since they lie near the border of the eyelid.

Scarifications, as well as curetting and brushing, should always be made parallel to the edge of the eyelid, since in that way the mucous membrane is preserved as much as possible. In trachoma it is invariably the upper culdesac which is the chief focus of the disease, and upon that structure the chief efforts of the surgeon should be brought to bear.

There is still one point to note, namely, once the eyelid is well everted, scarification and brushing should be commenced on the tissues that lie farthest away from the palpebral edge, since the conjunctiva when scarified retracts and some of the posterior parts may under such circumstances remain hidden. Scarifications may, in general, be larger and deeper in the upper than in the lower eyelid, since the disease strikes deeper in the former, the tarsal plate of which is often infiltrated in its whole thickness.

After the eyelids have been thoroughly scarified, scraped, and brushed, the raw surfaces are washed very carefully with wool steeped in a solution of mercury cyanid, 1 : 500. If it is thought necessary to widen the palpebral fissure permanently, the canthoplasty is completed by insertion of sutures in the classical way. As a dressing, simple compresses of wool moistened with mercury cyanid, 1 : 2,000, and kept in place by a bandage, are applied.

It is advisable to remove the bandage and to wash the eyes frequently with the 1 in 2,000 lotion, the eyelids being opened as much as possible for the purpose of allowing blood to escape. In the interval, iced compresses are useful.

On the following day, after the instillation of cocarenalin, we pass between the eyeball and the eyelid a probe coated with guaiacol ointment, with the object of preventing the formation of symblepharon.

The lower eyelid can readily be everted, and be freed

from secretion with a bit of wool damped with mercury cyanid lotion, 1:500.

The patient should keep his eyelids open as much as possible, and move the eyes about, and from time to time should raise the eyelid with his fingers. The same lotions and compresses are continued. Ten per cent. argyrol, used as an instillation or even as an eye-bath, is well-borne and has the advantage of preventing the reproduction of the infective elements.

On the condition that he secures perfect antisepsis and remains under observation, the patient may be considered cured a few days after the operation. For a month, however, sublimate or mercury cyanid lotion, alternating with instillations of argyrol, should be used. These remedies are then to be replaced by mild touchings once a week with the glycerol of lead, the underlying idea being as much to keep the patient under observation as anything else.

Chronic trachoma is the form that benefits most from surgical measures. This statement applies equally whether we are dealing with a few discrete granulations, which may be got rid of in a few séances without narcosis, or with large and numerous granulations with much succulent infiltration, which must be operated upon under general anesthesia.

The treatment of granulation by radium is likely to be of great service, but this product is so expensive and so difficult to procure that its employment cannot yet be recommended to the practitioner.

At the present time, thanks to the generalization of the surgical treatment of trachoma, we but rarely see pannus thick enough to call for the use of **jequiritol.** On the other hand, this energetic agent is of great service in many cases of scrofulous leukomata and pannus, but we must not forget that its application may be accompanied by certain unpleasant complications. The violence of the local reaction to jequirity is of relatively little importance,

since it may be arrested by a few instillations of jequiritol serum. It is, however, not so simple a matter to stop a medicamentous dermatitis, simulating erysipelas.

Xerosis or Xerophthalmia is a terminal complication of trachoma with chronic pannus, which ends by covering the whole of the cornea with cicatricial tissue, which has then nothing beyond an epithelial or mucous surface. Under these circumstances the eyelids become adherent to the cornea, and the eye atrophies. Treatment can effect little at such an advanced stage of the disease. In the beginning, however, service may be rendered by jequiritol, dionin, autoplasties of the mucous membrane of the mouth, etc.

Pemphigus of the conjunctiva is characterized by the development of bullæ, which are observed also upon the skin and the mucous membrane of the mouth and throat. The conjunctival manifestations, however, may in rare cases be the sole evidence of the disease. Bullæ are seldom visible upon the conjunctiva, because they rupture very quickly and are replaced by an ulceration which leads to cicatricial contraction and eventually to complete xerosis of the eyeball.

Pinguecula is characterized by hyaline degeneration of the episcleral tissue (Fuchs). It tends to make its appearance toward forty years of age. It takes the form of a fatty-looking spot lying in the conjunctiva at the inner or outer margin of the cornea and possessing a slightly yellow color. Although the condition is absolutely devoid of danger, it produces such an impression upon the minds of some patients, that one is compelled to ablate it by a stroke of the scissors.

Pterygium is represented by a vascular membrane which advances in the form of a triangle toward the center of the cornea and sometimes encroaches upon the pupillary area. Its cause is entirely unknown, but lack of care and dirt have probably something to do with its formation. In this condition we may try frequent instil-

lation of adrenalin, followed by massage with mercurial lanolin. The only efficacious treatment, however, is transplantation or total ablation of the pterygium down to its root.

Hyaline and amyloid degeneration of the conjunctiva are extremely rare. The conjunctiva is pallid, whitish, lardaceous, and much thickened. The treatment, purely surgical, is the excision of all of the degenerated mucous membrane.

CHAPTER XIX.

DISEASES OF THE CORNEA AND SCLERA.

Wounds and Infections.

The simplest type of ocular ectogenous infection and the one easiest to study is a corneal erosion or any other superficial wound of the eyeball, which has allowed penetration of infective microorganisms. Under these circumstances we must consider the various clinical indications which may present themselves.

The infective organisms which give rise to corneal complications are numerous. Their virulence extends from the action of the bacillus of Weeks and the diplobacillus of Morax to the dangerous effect of the gonococcus and Löffler's bacillus. The microorganism, however, which is without doubt most commonly found in infective ulcerations of the cornea is the pneumococcus.

Very many maladies of the cornea of the most varied description originate from a superficial infection by simple epithelial erosion, perhaps traumatic, perhaps by a primary neurotrophic lesion. After an almost imperceptible wound by a foreign body, we often see around it the production of a grayish aureole, which may sometimes invade a great part of the cornea and entail complete loss of the latter by suppuration. That is what occurs in serpiginous ulceration, which is generally caused by the pneumococcus, and which is often found among farmers and laborers. The condition cannot always be traced to the initial traumatism, but experience teaches us that what we call "abscess of the cornea" is almost always a local infection, the origin of which has passed unperceived.

It is astonishing to note how often an inflammation of the cornea that has been attributed to a generally debili-

tated state of the patient is due to a local inoculation which has remained latent for some time. Such, for example, are the dry abscesses of the cornea (Fuchs, Arlt)—that is to say, more or less central and circumscribed infiltrations of the cornea, which may persist for months without leading to suppuration and terminating by leukomata. Fuchs recognizes that in such cases we are dealing with local traumatic infections of low virulence. The writer has long held this opinion, and therapeutic experiments have given him almost the proof in the remarkable action of subconjunctival injections and, still more recently, of dionin. Other affections of analogous nature are to be found in arborescent keratitis (**keratitis dendritica**) and stellar keratitis (**keratitis stellata**), which reproduce faithfully the figures of cultures made upon solid media. It may also be questioned whether the so-called arthritic keratitis may not often be the outcome of a local infection, although it may be kept up by a general dyscrasic state.

A phlyctenular keratitis frequently appears after a very slight injury of the cornea or the conjunctiva, just as eczema of the eyelids may develop after a trifling irritation of the skin.

In presence of an infected wound of the eye, the first and most important indication is to destroy locally, as completely as possible, the focus of the infective agent. The best method of doing this is by the careful application of the **galvanocautery.** When dealing with a central corneal infiltration, too deep or too extensive an application of the galvanocautery may be followed by a leukoma, which may compromise seriously the vision. Subconjunctival injections alone often succeed in stopping the morbid process. They have the advantage not only of possessing a powerful antiseptic action, but also of stimulating the nutritive activity of the ciliary processes and of the corneal elements, thereby often reconstituting the tissues without leaving behind cicatrices or leukomata.

Treatment of Early Cases of Corneal Infection.—After

removal of any foreign body under cocain anesthesia, the extent of the injury should be exactly determined by means of fluorescin, and then, on account of its lymphagogic, detersive and antiseptic qualities, a drop of dionin should be placed in the eye. Next, the conjunctival sac is washed as carefully as possible and the corneal wound is cleansed particularly and inspected minutely, as are also the lacrimal passages. The latter should be irrigated if there is the least trace of suppuration or even evidences of lacrimal stasis. Protargolage is indicated when the eyelids or the cilia are agglutinated by suspicious-looking secretions.

Should the conjunctiva be free from suppuration and the patient have no pain, xeroform is instilled, and a simple occlusive and aseptic dressing is applied, so as to protect the corneal wound from all ulterior infection and to secure more rest and security for the patient.

When for any reason a bandage is contraindicated, merely an antiseptic lotion will suffice or, still better, a collyrium of dionin and mercury cyanid or of collargol, 2 per cent. By the adoption of these means cure usually comes about very quickly, and by the antiseptic precautions adopted infections which might assume grave proportions are often avoided.

Treatment of Advanced Infections.—In these cases the corneal wound is usually larger or already infiltrated with the eye painful and discharging. The first step in such cases is to cover the corneal wound with powdered dionin, which cleanses the wound energetically, provokes a salutary reaction and an analgesic condition, which renders less painful ulterior treatment, and often prevents the lively pain of traumatic keratalgia.

When dealing with a gravely infiltrated wound of the cornea, we should inject beneath the conjunctiva at the level of the upper culdesac a quarter, a half, or a syringeful, according to the seriousness of the case, of a solution of mercury cyanid, 1 : 5,000. The following formula should be employed under such circumstances:

Mercury cyanid	0.01
Sodium chlorid	1.00
Distilled water	50.00

After the injection is made, there is applied an occlusive bandage or rather an alcohol dressing, of which the potent and lasting lymphagog action, generalized throughout the orbital region, stimulates the processes of nutrition. On the second day the patient is sometimes almost cured. The artificial chemosis which results from the liquid injected beneath the conjunctiva, is usually resorbed after the first day, but if this is not the case, the bandage should be worn for another day. It is rarely necessary in this prodromal stage of infection to practise a second or a third subconjunctival injection.

Whenever we have to deal with a slight traumatic infection in an ulcer of the second degree, we may hesitate between the subconjunctival injection of sodium iodate, sodium chlorid, or of a weak solution of mercury cyanid. When the patient comes from a distance and cannot present himself again without great difficulty, mercury cyanid should be the agent selected for injection, and the wounded eye should be covered with an occlusive dressing that may be kept in place for two or three days. If cure is not then complete, the patient should return. If, on the contrary, the patient has been admitted to the hospital, or is able to attend regularly, the surgeon may make his choice of the different agents named earlier. Indeed, he may sometimes reach a good result, without other intervention than simple antiseptic lotions, compresses, and instillations. Such treatment may be the only kind available to those patients who dread anything approaching an operation. Moreover, in certain particular circumstances, the subconjunctival injections may be replaced by frequently repeated instillations of a collyrium of sublimate or of collargol, more especially if serotherapy is employed at the same time.

The trials made with antidiphtheritic serum, anti-

pneumococcic serum, etc., merely represent the first step toward treatment by chemical agents, which are still imperfectly understood. However, our knowledge of oxydases and colloidal metals enables us to foresee a large field of future usefulness.

The treatment of grave infective ulceration of the cornea and of all traumatic infection of the eye may be divided as follows:

1. Aseptization of the orbital surroundings, savonnage of the eyebrows, cilia, and skin, followed by cleansing of the conjunctival culdesacs, lacrimal passages, and of the cornea itself by means of a 1 : 2,000 solution of mercury cyanid.

2. The impregnation of the surface of the ulcer by means of fluorescin or methylene blue or violet, so as to penetrate into the deepest parts of the ulcer, and thus show with exactitude the whole extent of the infective infitration which should be eliminated. The entire infiltrated zone is then covered with powdered dionin (after the preliminary application of cocain) for the purpose of setting up an intensive detersion of all the morbid tissue and of rendering the diseased parts as analgesic as possible. In order to secure its full effect, the dionin should be allowed to act for at least half an hour.

3. Destruction, as completely as possible, by the curet or, rather, by the galvanocautery, all the diseased tissue, which should be removed to the limits of sound tissue. The galvanocautery may be replaced by the curet, but this instrument has the disadvantage of the possible inoculation of infective germs into sound tissue, should an abrasion of the epithelium be accidentally produced. This danger may be avoided by the use of the galvanocautery. The cautery, however, should be fine, not too incandescent, and be managed with a delicacy which can be obtained only after long clinical experience.

Applications of the galvanocautery are quite painless if neither speculum nor fixation forceps is employed,

since analgesia is secured by the dionin and cocain which have been applied to the eye. But to insure complete insensibility, it is usually necessary to touch the base of the ulcer with a little powdered cocain or stovain. After the cauterization we must never leave at the bottom of the wound the eschar carbonized by the galvanocautery, since it is likely to act as a foreign body. In these cases it must be removed by a probe wrapped with cotton wool moistened with a very small quantity of phenic acid, formol, or 20 per cent. zinc sulphate.

4. If a notable amount of pus be present in the anterior chamber and the tension of the eyeball is raised, the pus must be evacuated by the galvanocautery if the cornea is ulcerated or infiltrated in its whole thickness, or, better, by peripheral incision with the knife, which is preferable in most cases, or, lastly, when the ulcer is of wide extent, by Saemisch's transfixion.

5. Lastly, infection almost always spreads to regions which are not directly accessible to therapeutic measures, as shown by iritis and synechiæ which complicate almost every grave ulcer of the cornea. It is then that subconjunctival injections are unquestionably indicated. Under such circumstances they give remarkable results, and serotherapy also may be useful. We can definitely fix the value of the different therapeutic measures employed in ulcers of the cornea, as, for example, subconjunctival injections, galvanocauterization, paracentesis, and serotherapy, only when in each clinical observation we have the results of careful bacteriologic examinations. For instance, if it is determined that an infective ulceration is due to the common diplobacillus, then cure can be readily obtained by zinc sulphate, employed as a 5 per cent. collyrium dropped into the eye every hour and applied locally by the ophthalmic surgeon in a more concentrated solution (20 per cent.) by means of a Bowman's probe moistened with the liquid.

It is sometimes necessary to cauterize deeply and

intensely a quickly spreading ulcer of the serpiginous form in order to conserve the still transparent portion of the cornea, but it is more often indicated to practise light and punctiform cauterizations, to avoid very opaque leukomata.

Despite our extensive therapeutic arsenal, it is not yet possible to cure all cases that fall under notice. In fact, there are forms of corneal ulcer which in spite of all intervention are capable of destroying the whole cornea very quickly if an intelligent and desperate resistance be not opposed to them from the outset. Other very grave forms of infective ulcer of the cornea are consecutive to purulent ophthalmia, to diphtheritic conjunctivitis, and even to certain deep scrofulous infiltrations of the cornea, when occurring in extremely debilitated subjects. These various complications require special indications, although the treatment indicated for ulcers in general should be applied. In all grave infective ulcers we should invariably try the instillation every two hours of a 2 per cent. collyrium of zinc salicylate.

Serotherapy, which has given such marvellous results in the ocular manifestations of diphtheria, appears destined to open up a new era in the treatment of infective ulcers of the cornea, as, indeed, in all infections of the eye. It is clinically admissible and even proved by many facts that when faced by an infection localized to the eye it is advisable to apply immediately serotherapy as a general means of treatment, without awaiting the results of a bacteriologic examination, while adopting at the same time the various local measures already described. We have a choice between antipneumococcic, antistreptococcic, and antistaphylococcic sera, but since they are not always readily available, it is advisable to administer at once antidiphtheritic serum. This product appears capable of replacing to a greater or less extent all the others in ocular infections until such moment as we are able to find a vaccin or a serum that is really more active (see Serotherapy).

The first injection should be made with the serum most readily available, and when the bacteriologic examination has given more precise indications, it may be replaced by another serum, without our having to dread that the first injection has done the least harm. At the same time when in the presence of a grave infective ulcer of the cornea, we must not depend exclusively upon serotherapy. It is the same in cases of diphtheritic ulcers of the cornea, where even the specific serum does not always cure quickly enough to prevent perforation of the cornea. There is always strong reason for not trusting entirely to general medication, either antiinfective, eutrophic, or tonic. We must also employ dionin and such caustics as zinc sulphate (a sovereign remedy when dealing with diplobacillary infection), phenic acid, iodin and especially the galvanocautery, although the last agent like subconjunctival injections, should be applied only when the condition can be seen to be getting worse. We must never exhaust all our therapeutic resources at once.

Infective Traumatism of the Eyeball.

What has been said of infective ulcers of the cornea applies equally to infected wounds as the result of accidental or surgical traumatism, although the situation may be complicated by the different circumstances. Thus, the suppurations consecutive to cataract operation possess quite a special gravity, owing to the remains of the crystalline lens suspended in the aqueous humor, and this is true for the infections that may supervene after injuries of the crystalline lens. The gravity of the situation is enhanced if the posterior capsule of the lens has been torn or perforated, since such an accident allows the rapid propagation of suppuration to the vitreous body and the deeper membranes of the eye.

It is of the greatest possible importance to secure as complete asepsis as possible of the wound and of its sur-

roundings. Most careful lavage should be followed by the application of the galvanocautery to all the infiltrated, grayish, or yellowish parts, as recommended by Abadie. When this is indicated, we need not hesitate to plunge the point of the galvanocautery into the depths of the cataractous crystalline or into the vitreous body itself, if the last-named be already threatened with profound suppuration.

If the cauterization has been carefully made, the asepsis of the wound and of the infective focus will be almost complete. But in order to render the disinfection still more efficacious, we do not hesitate to practise, immediately after, a subconjunctival injection of mercury cyanid, the stronger and more abundant the more advanced the infective process. A full syringe or a half syringe, according to the case, of a 1:5,000 solution should be injected deeply behind the eyeball, so as to avoid too pronounced a chemosis. After it has been possible to effect this aseptization, it is desirable to cover the wound with a conjunctival flap, in order to protect it against any new infection. This protection of the wound was praised by Abadie and E. Meyer. More recently it has been warmly advocated by Kuhnt, who has advocated conjunctival protection as a method of treating all losses of substance of the cornea, ulcers, injuries, etc.

In order to **cover with conjunctiva** the wound made in the course of removing cataract, we proceed as follows:

An injection of cocain, 2 per cent., with alypin, 1 per cent., is made beneath the conjunctiva above the edge of the wound to be covered. The injection should be abundant enough to detach the mucous membrane of the episcleral tissue and thus to prepare, as it were, the flap in its entire extent. The dissection then becomes a very simple affair and can be made with strabismus scissors. One need not be afraid to detach the conjunctiva as far as possible even to the bottom of the culdesacs, from the internal rectus to the external rectus by passing above the

insertion of the superior rectus. Before turning down the conjunctival flap above the wound, care must be taken to freshen the latter either by a cutting instrument, as knife, scissors, or curet, which is always preferable, or by touching with chemical agents, such as silver nitrate, tincture of iodin, or the galvanocautery.

It is now desirable to see that the conjunctival flap will cover without traction one-third or, better, one-half of the cornea. In order that the conjunctiva may cover a larger surface of the cornea without undue dragging upon the sutures, Kuhnt makes a liberating incision toward the bottom of the conjunctival culdesac. The flap is maintained firmly in place by a double suture of silk, applied on each side of the horizontal diameter of the cornea. If the sutures have not already come away at the end of four or five days, they may be removed. The conjunctiva adheres only to the parts which have been freshened, and, owing to the retraction of the conjunctiva, too large a cicatricial fold need not be apprehended.

The foregoing procedure is the one that has succeeded best in all ocular injuries that involve the periphery of the cornea. It is much superior to the purse-string suture and to covering the parts with detached strips.

Even when the wound is securely protected, the case must be kept under close observation until cure is complete. A sufficiently violent reaction may set in the same day or the following day. The dressing must then be removed, two to four leeches be applied to the temple, and continual instillations be made of the following collyrium:

Mercury cyanid	0.01
Cocain hydrochlorid	0.10
Dionin	0.10
Sterilized water	10.00

Of this collyrium two or four drops should be instilled into the diseased eye every half-hour; 0.05 of atropin or of eserin should be added, according to the indications furnished by the state of the pupil.

After the inflammatory reaction has passed, the question arises whether fresh subconjunctival injections should be made. In case of doubt, abstention is not wise. One or two injections too many are better than one too few. Here, as always, clinical sense is our only guide. It is easy to make a mistake in the difficult battle with the infective elements. We may appear to have stopped the progress of the mischief when a few days afterward infection is re-born, as it were, from its own ashes. We must never disarm, and patients must be kept for a long time under observation, so that we may intervene whenever the clinical indications are precise. Cauterization and subconjunctival injections must almost always be renewed several times, and sometimes we must even resort to intraocular injections.

We possess nowadays in serotherapy a new and most powerful aid which allows us to furnish to the organism the powerful elements of defense which second our local antiseptic efforts. In all infective accidents of the eye we should not hesitate to give from the beginning antidiphtheritic serum, which must be regarded as the most active and the most certain of the serums and one that can always be obtained. The writer has published five cases of postoperative infection, as well as numerous cases of traumatic infection, cured by serotherapy and local measures. Such satisfactory results he had never succeeded in obtaining before. He, therefore, looks upon serotherapy as an important factor in the treatment of all ocular infections.

Ophthalmic surgery in the treatment of these cases is becoming more and more unnecessary.

Enucleation must be practised whenever the injury is too grave to allow us to hope to keep the eye useful as regards sight or shape and also whenever the eye contains a foreign body that cannot be extracted.

Wounds of the ciliary region have always been regarded as of the most serious description. Experience has shown that a penetrating wound of this part of the

eye (apart from immediate complications) may often entail sequels of a most serious nature, as, for example, acute suppurative iridochoroiditis, which may terminate in abscess or atrophy, and which may often become complicated by a secondary iridochoroiditis of the other eye (sympathetic ophthalmia). In this way complete blindness may often be the consequence of a simple wound of the ciliary region.

The primary cause of this gravity of a relatively slight traumatism remained obscure until the comparatively recent discoveries of microbiology. For a long time it has been known that the iris and the ciliary processes play an important part in the nutrition of the eyeball. From that fact it follows naturally that a profound alteration of this portion of the eye may have grave consequences for its future.

Where formerly we saw merely an action of a purely mechanical nature we now see an infective process, which invades the tissues of the eye more and more deeply, and which may even spread by a more or less direct path to the eye of the opposite side. It is now recognized that simple wounds of the cornea may bring about a panophthalmitis, progressive phthisis of the eyeball, and even sympathetic ophthalmia. The same may be the case for wounds which involve the sclerotic exclusively, even though neither the ciliary body nor the iris has been injured. In fact, the gravity of any penetrating wound of the eyeball, no matter what its situation, is absolutely subordinate to the degree of asepsis in which the wound is kept until its complete cicatrization.

One peculiarity of wounds in the ciliary region is also the difficulty experienced in some cases of knowing whether infection has or has not taken place, inasmuch as infection may make its way from behind in a slow and insidious way and invade little by little the ciliary zone without producing very pronounced reactional phenomena until the eye is on the point of atrophying or until sym-

pathetic ophthalmia breaks out suddenly. In wounds of the cornea, on the contrary, the changes are always visible, and danger may be avoided by timely intervention.

Burns.

Burns of the cornea by **curling irons** are quite frequently seen. Although such injuries may be extremely painful, they are seldom of any gravity. The corneal ephithelium only has been destroyed, and the patient can be cured in twenty-four hours by an occlusive dressing after careful washing and the instillation of dionin.

If the injury, however, has been inflicted by **hot metal** in a state of incandescence the burn may be much more serious. The eyelid is often more or less burned, and the cornea may be injured beneath Bowman's membrane. The transparency of the cornea is then seriously imperiled, and cure, slow and difficult to produce, may entail a more or less thick leukoma, to say nothing of the violent pain not infrequently experienced by the patient. In these cases cocain is almost without action, although dionin may succeed in calming the pain. The best treatment, however, is to apply an occlusive dressing, after having placed in the eye an ointment compounded of picric acid, 1 per cent., orthoform, one-tenth, and anesthesin, or, better still, an oily collyrium of acoin. The smarting, which is severe at first, is followed by a period of analgesia, lasting from four to six hours. The dressings and applications, therefore, must be renewed every four or six hours. The cicatrization of these burns, like that of all deep and large ulcerations of the cornea, takes considerable time.

In grave cases there is no plan so efficacious as to cover the conjunctival wound and the corneal ulceration with a large conjunctival flap (autoplasty). The ulcer should be completely covered and hidden by the conjunctival graft. When conjunctival autoplasty is not feasible,

it is advisable to place between the palpebral conjunctiva and the cornea a delicate sheet of gold or of silver, or, better, some of the white membrane which lines an egg-shell, which should be renewed every two or three days until the surfaces of contact have become covered with epithelium.

By the adoption of the foregoing means we sometimes obtain an unexpectedly good result—the rapid cessation of the pain, the arrest of conjunctival and corneal sphacelus, and complete cicatrization in three or four days; while by the use of collyria and ointments the parts may take two or three months to heal, and the process may be accompanied by a thick pterygium and a dystrophy with flattening, perhaps only partial, of the cornea and a very notable reduction in vision.

Vapor burns are usually not dangerous to the cornea. In such accidents the eyelids close so quickly that the vapor has no time to act deeply. As a rule, the epithelium alone suffers, and is reproduced in the course of a day or so. The regeneration may be hastened by the application of dionin.

Burns by ammonia gas under pressure are much more dangerous. A patient injured in this way in both eyes presents himself with the two corneæ densely white. At the end of several days this white eschar becomes detached (it involves probably all Bowman's membrane), leaving the cornea completely transparent. The joy of the patient on finding that he sees clearly is, however, short-lived, for in a few days the corneæ become cloudy and cicatricial tissue forms, leaving the two eyes absolutely leukomatous. In one such case transplantation was performed, the cornea of a guinea-pig being used for the purpose. The new cornea remained transparent for three weeks, and then became opaque. The patient remained completely blind.

Burns of the cornea by **lightning** or **electricity** (by short circuits of 500 volts) may also lead to complete necrosis of the corneæ, although lesions of such gravity are excep-

tional. The cilia and the eyebrows are burned, the skin is swollen and of a deep red color, and the opaque cornea seldom regains its transparency.

Molten lead projected in a certain quantity into the eye gives rise to appearances that are more alarming than serious. We often see the corneæ covered with a pellicle of lead having a spherical shape, which, when it is removed with gentleness, reveals a perfectly transparent cornea. Indeed, the eyelids and the conjunctiva often suffer more than the cornea.

Burns by caustic agents, such as acids, caustic potash or soda, may set up extremely grave lesions. Thus, if the corneal tissue is affected down to Bowman's membrane, a dense leukoma always results, and if perforation is imminent, the corneal wound should be covered with a conjunctival flap (autoplasty). In mild cases the treatment should consist especially of occlusive dressings of iodoform ointment or of picric acid, 1 per cent., after careful cleansing with sterile water and aseptization of the wound and of the culdesac. Burns of the eyelid should be dressed with the same ointment, which is at once analgesic and cicatrizing.

Burns by lime should be washed with milk and then dressed with oil or euvaselin.

The vast burns caused by the criminal throwing of **sulphuric acid** into the face provoke such extensive destruction that once cicatrization is obtained after long months of treatment we are usually compelled to repair contractions, ectropion, symblepharon, etc., by autoplasty. There is often an advantage from the first day in sacrificing the burned parts and by covering the tissues at once with skin-flaps, pediculated or otherwise, the tissues having previously been freshened and freed. By this means a much more rapid cure and one almost free from pain may be obtained, while the dressing of burns is very painful and, as a rule, should be made at long intervals.

Keratitis.

The Treatment of Keratitis.—For clinical purposes, cases of keratitis may be divided into two great classes, superficial and deep. Superficial keratitis almost always ends in ulceration of the cornea, and we must keep in mind all the relative indications to the rendering aseptic of the morbid focus, which exposed, as it necessarily is, to the air and to the secretions of the eye will scarcely fail to become infected, no matter how antiseptic the tears may be. Almost invariably also there exists a concomitant conjunctivitis, and sometimes also a blepharitis.

In all these cases there should be attempted sterilization of the conjunctival culdesacs and the edges of the eyelids by frequent lavages and especially by soaping of the eyelids with protargol, which yield excellent results.

Atropin should not be looked upon as *the* special therapeutic agent in cases of keratitis. It is really indicated only in cases in which keratitis is likely to be complicated with inflammation of the iris. The practitioner should understand how to prescribe and how to suspend its employment in accordance with the indications of the particular case.

Lymphatic, Phlyctenular, Pustular, or Eczematous Keratitis.—This affection, in which the general state plays the predominant part, but in which secondary infection may be formidable, is usually quickly cured by the classical treatment with yellow ointment and general tonic medication. By means of a small glass rod, previously placed in the flame for purposes of sterilization, we introduce into the affected eye a small piece of 5 per cent. ointment, as large as a millet grain, and repeat the application every day or every other day. Between these applications we prescribe frequent washings and instillations, four or five times a day, of a collyrium of 5 per cent. argyrol. If at the end of a few days we see that the yellow ointment has lost its efficiency, we may try a 2 per cent. guaiacol

ointment, which sometimes gives good results. This latter fact seems to show that these cases of phlyctenular keratitis are tuberculous, as seems sometimes to have been proved by microscopic examination.

In the grave cases, with deep infiltration and corneal abscess, there is no better treatment than the employment of subconjunctival injections. The satisfactory effect of this local intervention has been shown by Secondi and many other writers. The injections have not only the advantage of ending the pathologic processes, but also of augmenting the rapid resorption of the morbid infiltrations and of effecting the transparency of the diseased corneal tissue. The same facts have been noted by Mellinger after the injection of saline, to which we may add a stimulating action upon the circulation of the nutritive lymph of the eye, bestowing upon this liquid a greater fluidity, together with a more marked dissolving and resorbing power. The subconjunctival injection of sterilized air often relieves photophobia and pain, and in this way hastens the cure. Dionin may also be of great service.

By a series of very interesting anatomic and experimental researches, Leber has been led to conclude that conjunctival or corneal phlyctenulæ are the result of an endogenous infection, the first peripheral localization of which is found in the intima of the small vessels. Numerous giant cells and the clearly tuberculous aspect of a phlyctenule make one think of a tuberculous infection, although no one has yet succeeded in finding caseation or bacilli. Scrofula and tuberculosis are quite analogous.

It is therefore rational to insist particularly upon the general treatment of children affected with pustular keratitis. Good hygiene, adequate feeding, arsenic, iron, and quinin should be recommended in the first place. Cod-liver oil, quinin, and the iodotannic preparations also render the greatest services. In certain rebellious forms extremely small doses of mercury combined with potassium iodid, as in the following formula, should be tried:

Potassium iodid	5.0
Mercury bichlorid	0.05
Cognac	30.0
Syrup of orange flowers	30.0
Water	120.0

One to four teaspoonfuls a day should be given, according to age, for three days a week.

Fascicular keratitis is really a form of eczematous, strumous, or lymphatic keratitis, and although more tenacious than the latter, responds to the same treatment. In these cases, as in those which are accompanied by a central ulcer of the cornea, atropin is indicated, while it is useless in the treatment of phlyctenulæ involving the limbus or the periphery of the cornea, which can be readily cured without it.

Strumous pannus of the cornea calls for patient and prolonged attention. Dionin applied at longer or shorter intervals of time renders great service. Adrenalin should be used cautiously and only when no epithelial change is present, as proved by fluorescin. The best treatment consists in massage with yellow ointment or calomel, together with general treatment, salt-baths, and plenty of fresh air.

In **pannus crassus,** jequiritol may be very useful, even more so than in cases of trachoma.

The marginal ulcer (catarrhal ulcer), also called **arthritic ulcer** of the cornea, is generally observed among aged persons, who are more or less rheumatic, and is often accompanied by violent symptoms of irritation. As a rule, it cicatrizes completely without a leukoma, although it often recurs. In this type of ulcer, irritant collyria and violent caustics must be most carefully avoided. The general state should be the object of especial care. In arthritic or gouty subjects, of especial value are the preparations of salicin, and, in particular, aspirin, of which the antineuralgic action is most useful in these cases when given in an average dose of 2 or 3 grms. a day. Sodium

benzoate and the salts of lithium are of service among gouty subjects, but if their action is not sufficient, it is advisable to employ colchicin very prudently in a dose of from 1/2 to 3 mgrms. a day. Among those affected with arteriosclerosis, 0.20 to 0.50 a day of sodium iodid, combined with a milk diet, gives good results.

As local applications Abadie recommends simple alkaline lotions with Vichy water or a 0.4 per cent. solution of sodium bicarbonate. Asepsis of the edges of the eyelids may be secured readily by protargolage of the eyelashes. In case of violent pain, the following collyrium may be prescribed:

Dionin	0.10
Cocain hydrochlorid	0.10
Sodium bicarbonate	0.20
Distilled water	10.00

A drop to be placed in the affected eye four to six times a day.

All the cases are not similar and are not influenced in the same way by our therapeutic agents. When pain is not relieved by the employment of dionin, sodium salicylate, or aspirin, alone or combined with quinin, good results may follow the administration of the tincture of rhus toxicodendron, of which five drops should be given three or four times a day in a little sweetened water. The occlusive dressing is most useful in these cases, and may by itself lead to cure of the condition.

Infective ulcers of the cornea have been discussed when dealing with traumatic erosions of the cornea.

Superficial arborescent keratitis, without being exactly serious, is often rebellious to all treatment, especially when it occurs in aged and decrepit subjects. In these cases all general medications are inefficacious, and the multiplicity of the local remedies praised is enough to prove that none of them may be looked upon as a specific. In order to attain a cure that shall be as prompt and as radical as possible, we cannot arm ourselves with too many precau-

tions. The caustics most in vogue are tincture of iodin, concentrated phenic acid, quinin, argyrol, etc. Should these remedies fail, we should proceed as follows: After the extent and topography of the lesion have been defined by means of fluorescin, we effect as complete an asepti-zation as possible of the cornea, conjunctiva, and lacrimal passages. Then, having lightly touched the most diseased points in the cornea with the galvanocautery brought to a dull-red heat, we inject beneath the conjunctiva a syringeful of a solution of sodium iodate, 1:1,000. The eye is kept bound up with an occlusive dressing of xeroform for a couple of days, and if after this any notable portion of the old lesion is stained by fluorescin, the treatment described above is repeated as often as may be necessary to obtain complete cure. In rebellious cases we need not hesitate to have recourse to antiinfective serotherapy.

Herpes febrilis of the cornea (well studied by Horner) is most often a syndrome of febrile affections accompanied by labial or cutaneous herpes. The treatment of this affection is directed toward cleanliness, antisepsis, and to such general measures as may be indicated by the disease. Cure is rapidly obtained with or without the application of yellow ointment, iodoform ointment, and an occlusive bandage. As general treatment, quinin is of service. In tenacious cases electricity and even serotherapy may be tried.

Graver still are the vesicles of herpes corneæ in **zona ophthalmica.** In these cases there is an affection of the trigeminal nerve, of which the primary cause is to be sought in a lesion of the great sympathetic, the trophic filaments of which accompany the large nervous trunks. In these cases the cornea is generally insensitive, although that does not prevent the patients from sometimes suffering excruciating pain.

Serotherapy employed at the commencement of zona may abrogate the pain and shorten the suppuration. In the later stages, we endeavor to calm pain by the local

application of dionin, 10 per cent., in a solution of mercury cyanid, 1:1,000, which keeps the ulceration of the cornea in a condition of asepsis as complete as possible. Subconjunctival injections of 0.01 to 0.02 of dionin often succeed in calming pain. Pyramidon, 2 to 3 grms. a day, may be prescribed. Ointments containing iodoform, xeroform, guaiacol, or collargol may have a good effect, and an occlusive bandage will protect the cornea against external irritants. Quinin and the constant current form the basis of general treatment. Good results have sometimes been obtained from orthoform, anesthesin, and acoin ointment. After the application of these remedies there is lively smarting until an occlusive bandage is applied, when a period of calm, lasting for four to six hours, supervenes and allows the patient to sleep.

Vesicular or bullous keratitis often appears upon corneæ which have already suffered from trophic disturbances—for example, in absolute glaucoma. We now and then see the epithelium of the cornea raised over most of its extent by transparent liquid; but such cases present only a secondary therapeutic interest, as vision is already lost. There are also cases in which small transparent vesicles make their appearance upon corneæ seemingly healthy, without any exact cause.

Vesicular keratitis occurs nearly always with repeated relapses, which leave, after the shedding of the pellicle covering the bullæ, an ulcer, to which the name of "relapsing ulcer" is commonly applied.

The nervous element must in these cases be regarded as one of the principal causes of the affection. The reflex may be excited by peripheral irritation or by errors of refraction and, in particular, by astigmatism. The general treatment should be directed to the cause. Locally, we employ ocular analgesics, dionin, and an occlusive bandage, and the oily collyrium of acoin.

The corneal complications of glaucoma are influenced very favorably by subconjunctival injections of sodium

iodate, 1 : 1,000. The dose is 1 c.c. These injections, which produce scarcely any pain, immediately reduce the tension, at the same time abolishing the pain. When the vesicles are not dependent upon glaucoma, the subconjunctival injection of sterilized air often gives a very good result. Finally, it is always advisable to make certain that the corneal changes do not proceed from a dental reflex.

Pemphigus of the conjunctiva usually entails grave lesions of the cornea. The cornea becomes the seat of ulcerations, and, little by little, its surface becomes sclerosed, leaving little transparent tissue. Treatment is without effect. Dionin, instillations of tepid milk, etc., are useful anodynes.

Macular keratitis or superficial punctate keratitis is characterized by the presence of numerous small, gray spots situated in the anterior layers of the corneal tissue. It forms, as it were, a kind of eruption of subepithelial foci of infiltration, evidently of infective origin. This affection is observed almost always after influenza. When we are fortunate enough to see the disease very early, the rapid disappearance of the maculæ may often be obtained by alternating with the local application of powdered dionin, subconjunctival injections of sodium iodate, 1 : 1,000, mercury cyanid, 1 : 5,000, or guaiacol, 1 per cent., together with the administration of quinin internally. When the lesions have lasted for ten days or so, their disappearance is much slower. Under such circumstances they may persist for longer than three months, despite repeated massage with mercurial lanolin or iodoform following the treatment recommended above.

Another species of deep macular keratitis, equally infective, is furnished by a particular form of **syphilitic macular keratitis.** It is rare, and, in general, not well-known. The maculæ, which do not, at the outside, exceed half a dozen in number, lie in the deep layers of the cornea, beneath Bowman's membrane. They are not

scattered, as in superficial macular keratitis, over all the corneal surface. Usually they are conglomerated in one sector of the cornea, and sometimes spare the pupillary area, which may lead to the malady being overlooked by the patient for some time. In these cases therapeutic efforts are poorly rewarded. On the contrary, if the lesions are seen at their commencement, cure may be obtained in a reasonable time by subconjunctival injections of mercury cyanid, 1 : 5,000, alternating with the local application of dionin, and aided by a series of mercurial intravenous injections, made at first daily and then every second day. Treatment is always lengthened. If the lesions are of long standing, months or years are required to arrive at a more or less complete cure, for then the deposits may have become infiltrated with calcareous salts.

Keratitis punctata, or more simply **descemetitis,** characterized by more or less marked deposits on Descemet's membrane, is far from being a morbid entity. It is, in fact, a physical sign which denotes the presence of an inflammation of the ciliary processes or the iris, proceeding from the most diverse causes (syphilis, rheumatism, tuberculosis, influenza, and sympathetic ophthalmitis). Treatment in these cases depends upon the cause.

Filamentary keratitis is manifested at first by a superficial lesion of the corneal tissue, the epithelial cells of which elongate and become rolled into mucous filaments which contain leukocytes. The galvanocautery may be employed to destroy the primary lesion of the cornea. If the lesion lies near the border of the cornea, an attempt may be made to cover it with a bridge of conjunctiva.

Acne rosacea of the cornea is most often met with in women over thirty years of age. It occurs usually after acne rosacea of the face, especially when the root of the nose and the eyelids have been the seat of efflorescences for some time. An old remedy, the turpeth mineral (mercury subsulphate), gives very good results, causing the manifestations of acne to disappear and preventing

their return, provided the application of the medicament is continued without interruption as a part of the daily toilet. Night and morning the following ointment should be rubbed energetically into each affected spot for ten full minutes:

Turpeth mineral	2.0
Lanolin	15.0
Oil of almonds	15.0

A drop to be placed in the affected eye four to six times a day.

Once the pustules of acne have made their appearance upon the cornea it is easy to cure them, but they invariably leave a very white and punctiform cicatrix which, should it happen to lie in front of the pupillary orifice, causes much visual disturbance. If many recurrences should occur, the resulting disturbance of sight may be so marked as to call for surgical intervention (optical iridectomy).

Local treatment includes dionin applied to each pustule at intervals of a week, or, better, as soon as a fresh manifestation occurs, yellow ointment, turpeth ointment, or guaiacol ointment applied by massage to the cornea, and changed according to the indications of the case. General treatment should be employed in acne. A rigid régime should be ordered, and intestinal asepsis should be secured. Exercise and hydrotherapy have a good effect, as have currents of high frequency, etc. The following powder may be recommended on account of its laxative and antiseptic properties:

Sulphur	30.0
Calcined magnesia	30.0
Wood charcoal	30.0

A tablespoonful to be given daily.

Aspergillary keratomycosis is caused by the penetration and development of a fungus, the aspergillus, in the

thickness of the cornea. This exceedingly uncommon affection usually follows an injury. Its treatment should be purely surgical. After cocainization, by means of a curet, we remove the mycelian felting, which sometimes comes away in one piece. The after-dressing should be of iodoform, argyrol, or collargol ointment.

Primary marginal ulcerations of the cornea appear without obvious cause upon the edge of the cornea. The reaction is not marked. In general, the ulceration remains limited to the limbus, and does not invade the center of the cornea. The lesion should be treated by instillation of 2 per cent. collargol, and, once a week, a drop of 5 per cent. dionin should be applied to the eye, in order to induce a reaction susceptible of hastening cicatrization. Iodoform ointment will sometimes be found useful.

Lepromata of the cornea are scarcely found except in patients suffering from leprosy. In these cases there are upon the cornea small exuberances of a whitish-yellow color and more or less vascular. The leproma sometimes does not form a projection, but remains, as it were, interstitial. At other times it may ulcerate. Diagnosis depends essentially upon the presence of cutaneous and nervous lesions. Treatment is by atropin, hot compresses, and oil of Chaulmoogra internally.

The etiology of Mooren's **rodent ulcer** is still obscure. In this condition we see an ulceration commence at the periphery of the cornea, and progress slowly but steadily between the superficial layers of the membrane. Its evolution may take three or four months before it has invaded the whole of the corneal surface and produced a total leukoma. Perforation is a rare event. Tincture of iodin, phenic acid, lactic acid, and the galvanocautery are the best means at our disposal of fighting this redoubtable affection, although without much success.

Keratite en bandelette, Keratitis transversalis, keratitis e lagophthalmos, neuroparalytic keratitis, and ulcera-

tions of the cornea following exophthalmos are lesions which exact no special indication except that of protecting the cornea against air and dust. The best means to accomplish this is the temporary suture, complete or partial, of the eyelids. Dressings are, in general, inadequate for the purpose. In mild cases, however, we may employ a dressing with 5 per cent. collargol ointment, which is not irritating and which retards the development of the microorganisms. During the day instillations of a 1 per cent. oily collyrium of collargol may be practised.

Keratomalacia is a special corneal infection met with in quite young infants. It generally leads to perforation of the cornea almost without reactional symptoms. All authors agree that the corneal lesion depends upon the general state: insufficient nourishment or a morbid hereditary process, such as congenital syphilis. Keratomalacia is observed especially in Russia after the great fast. The object of treatment should be to invigorate the powers of the infant and to excite the vitality of the corneal tissue. Dionin, oily collyria of pilocarpin are indicated; and it is important to secure good closure of the eyelids during sleep, since by apathy the babies no longer shut their eyes. In suitable cases energetic antisyphilitic treatment should be adopted. The palpebral opening is filled with iodoform or collargol ointment made with euvaselin. Euvaselin, having a somewhat high melting-point, remains in place for a considerable time,

Xerosis of the Cornea, Xerophthalmia.—Epithelial xerosis depends essentially upon a disturbance of the general state. The conjunctiva loses its shining and moist aspect. Somewhat thickened, it becomes dirty, opaque, and covered with white and dry foam (*mousse*). The cornea is often invaded by this thickened and dirty conjunctiva, which may end by soldering the eyelid to the limbus. Treatment is almost without effect. But frequent vaporizations, instillations of milk, oily collyria of guaiacol, dionin, glycerin, etc., may be tried.

Deep Keratitis, Parenchymatous Keratitis, Interstitial Keratitis.

Strictly speaking, the syphilitic macular keratitis already described is a deep keratitis. We must guard against grouping together all cases of corneal infiltration, more or less deep, more or less diffuse, and more or less widely spread. There exist corneal infiltrations (meso-keratitis) of very different origin. There are cases of benign parenchymatous keratitis of circumscribed form and rapid evolution, while there are others of a most serious nature, which may last for years and may sometimes even lead to blindness, as the result of various complications.

Striated Keratitis (**La keratite quadrillee** or **keratite en grillage**), described during the last few years, is probably due to an infiltration of the corneal spaces by fine granulations, seen by the naked eye as long stripes, resembling canals, crossing each other generally at a right angle. This form of corneal infiltration sometimes clears very rapidly under the influence of subconjunctival injections of sodium chlorid, sodium iodate, or sodium salicylate, and, indeed, even under the influence alone of instillations of dionin.

The cases of striated keratitis so far reported have been slight in nature. Among patients affected with rheumatism, however, cases of remarkable intensity may be sometimes observed. In these cases at first the cornea takes a grayish aspect, so that even close inspection with the naked eye shows an apparent intense infiltration of all the lymphatic spaces of the cornea, crossing almost at right angles, and giving the effect of cross-hatching. In the course of a month the cornea becomes in this way completely white, and it is secondarily only that circum-corneal hyperemia together with fine deep vascularization of the cornea makes its appearance. Resorption is noticed only at the end of several months.

That this form should be looked upon as a special form

of **rheumatic parenchymatous keratitis** is borne out by the effect of antirheumatic treatment—salicylates, hot applications, ocular massage, etc. Subconjunctival injections of sodium salicylate, badly borne at first, have brought about during the period of resolution a rapid clearing of the cornea. Generally speaking, deep discoid keratitis, which occupies the center of the cornea, is usually much less favorably influenced by subconjunctival injections than the more superficial forms which occupy the periphery of the cornea.

Striated keratitis after extraction of cataract is due to a folding of Descemet's membrane. Therapeutic results are slow, no matter what the treatment employed.

After the penetration of a foreign body into the cornea there is often seen around the wounded spot a zone of parenchymatous infiltration, which generally disappears spontaneously after removal of the foreign body. At the same time such infiltrations may entail small films of the cornea, and in such cases it is advisable to make either repeated instillations of a collyrium of dionin or to practise a few subconjunctival injections of 2 or 4 per cent. sodium chlorid.

The same plan of treatment should be adopted in certain disturbances of the cornea consecutive to violent contusions of the cornea (**traumatic mesokeratitis**), which sometimes simulate parenchymatous keratitis and may be mistaken for it, especially when the injury affects a more or less predisposed individual. When dealing with subjects predisposed by hereditary syphilis or scrofula, we often see the development of a true parenchymatous keratitis follow an injury or even the presence of a foreign body in the cornea.

Until the last few years it was pretty generally admitted that parenchymatous keratitis represented one of the principal manifestations of the so-called **"Hutchinson's triad"** (alterations of the teeth, ears, and eyes characteristic of hereditary syphilis). Recently, however, in-

teresting works have appeared which prove that many cases of parenchymatous keratitis are of tuberculous origin. Some authors have gone so far as to maintain that tuberculosis, as well as scrofula and all dyscrasic affections of long duration, may, like syphilis, give rise not only to the corneal changes but also all the trophic disturbances that characterize Hutchinson's triad, and that, consequently, we should not consider the ensemble of these signs as a proof of hereditary syphilis. Clinical observation and therapeutic experiment agree in showing that parenchymatous keratitis may be seen in those who are simply scrofulous or debilitated, and among the tuberculous only very rarely. Before long we may hope that clinical work, aided by experiments and pathologic anatomy, may place in our possession the signs whereby the differential diagnosis may be established between the different forms of parenchymatous keratitis.

In many cases the tuberculin reaction allows us to class apart tuberculosis of the cornea. But to syphilis must be left the stigmata of Hutchinson, which constitute a convincing clinical proof. In this connection it is to be hoped that further tests with Wassermann's reaction may prove of value. When dealing with a case of parenchymatous keratitis accompanied by dental stigmata, it is safe to conclude that the patient is affected with hereditary syphilis.

A grave case of parenchymatous keratitis, with more or less complete loss of the transparency of the cornea, should be treated by the hypodermic or intravenous injection of soluble mercurial salts or by long-continued inunctions, and treatment should be kept up for months, naturally with periods of rest.

The analogy between syphilitic lesions and certain tuberculous affections, notably those of the bones, articulations, glands, and skin, has naturally suggested the idea of utilizing against these local tuberculous manifestations the means employed in dealing with syphilitics, namely,

iodin and mercury. Iodin has for long been employed in the treatment of chronic adenitis. In hypodermic injections, according to Durant's method, it has been frequently used of late for the cure of surgical tuberculosis. But as Durant's solution, as well as that of Lugol, causes lively pain, attempts have been made to replace it by other solutions. Iodin trichlorid and other unstable mineral salts present this advantage, that as soon as they are in contact with the tissues they are split up and thrown into the circulation as nascent iodin. In fact, these preparations have an action quite different from that of potassium iodid.

In parenchymatous keratitis in children we have recourse to hypodermic injections and inunctions. Intravenous injections are more difficult to make in children, and should be reserved for older and more docile patients.

During the acute period, which may last for several months, all irritating applications should be avoided, and we must content ourselves with the repeated instillation of atropin and the frequent application of hot compresses. An excellent remedy under these circumstances is the mercurial poultice.[1] But the chief dependence during the acute and painful period of the disease should be placed upon general treatment. At a later stage subconjunctival injections, made at the opportune moment, exert a capital influence upon the evolution of the morbid process.

In benign, atonic cases of parenchymatous keratitis, which are often only the first stage of a grave form, when the infiltration is circumscribed and the reaction is moderate or lacking, subconjunctival injections sometimes give excellent results. After each injection one often sees the corneal infiltration pushed, as it were, from the periphery toward the center, since each injection sweeps, so to speak, the whole of the corresponding segment of the cornea. In this way one may go around the cornea so well

[1] After 2 grms. of mercurial lanolin have been well rubbed into the parts surrounding one or both orbits, a linseed meal poultice, which should be large, thick, and as hot as the patient can bear, should be applied and left on all night.

that in some weeks the infiltration can be seen only in the central parts of the cornea. It would appear, then, that the fluid injected beneath the conjunctiva reaches no farther than the lymphatic spaces most distant from the sclerocorneal limbus.

At this stage massage with mercurial lanolin will render the greatest service. After cocainization, a bit of the ointment, the size of a grain of wheat, is placed between the eyelids, and massage, which should be rotatory, smooth, and prolonged, is carried out. These frictions may be alternated with hot compresses, vapor douches, and mercurial poultices.

Sydney Stephenson has noticed that in cases in which specific treatment has remained without effect he has obtained very rapid results by combining with the action of mercury that of atoxyl. The atoxyl is to be injected once a week in a dose of from 0.25 to 0.50, and the total amount given in a series of injections, which are made deeply into the muscles of the buttock, should not exceed 6 grms. In almost all the cases Stephenson found that a dozen injections sufficed.

Martia has published a careful and complete work dealing with the therapeutic action of subconjunctival injections of saline in parenchymatous keratitis. He concludes that by stimulating energetically the lymphatic exchanges the injections have a most favorable action upon the resorption and elimination of the noxious elements infiltrated in the tissues of the cornea. The saline injections, moreover, have the very important quality of causing very little pain. Sterilized sea-water has also given very good results. According to Demicheri, sodium nitrate has a very powerful stimulant action upon the blood and lymph circulation.

Lastly, during the last few months the subconjunctival injection of a 1 to 2 per cent. watery solution of guaiacol has given the author such encouraging results that he would not be surprised to find in this drug the injection

most indicated in cases of ocular tuberculosis. The injections are scarcely painful. For a couple of minutes the patient experiences smarting, but he feels nothing more, guaiacol being manifestly analgesic.

Resume.—The following is the treatment to be adopted in cases of parenchymatous keratitis:

1. General treatment is the first indication. It should be based upon the etiology of the disease and the constitutional state of the patient. The best results are usually obtained from hypodermic or intravenous injections of mercury cyanid. When injections cannot be given —as, for example, in very young subjects—inunction may be resorted to, or sublimate may be given by the mouth.

2. During the acute stage, local remedies should be limited to collyria of atropin and dionin, hot compresses, mercurial poultices, and dressings of alcohol, guaiacol, salicylate, etc. Such cleanliness and antisepsis should be carried out as may be indicated by intercurrent affections of the eyelids and conjunctiva.

3. When after this period of expectation we see that the conditions lend themselves to more energetic local treatment—that is to say, when there is no marked conjunctival hyperemia and when the subject is docile and of a certain age—we may proceed to subconjunctival injections, beginning with half a syringeful of 2 per cent. sodium chlorid at a temperature of about 32° C., or sea-water, or sterilized air, which are the substances best supported.

If the first injection is resorbed completely, a second is made in two days after; but the evolution of parenchymatous keratitis being extremely slow, it is better not to hurry and to practise the injections at intervals of at least three days. The injections, commenced with a half syringeful of 2 per cent. sodium chlorid, should be progressively increased both in volume and in strength, so that a syringeful of a 4 per cent. solution may be injected.

When about a dozen injections have been made,

there should be a break, during which the patient should continue, with or without interruption, general treatment, in addition to atropin and hot applications.

When the subject is manifestly syphilitic, or even in cases in which other treatment has not succeeded, we should without hesitation adopt the subconjunctival injection of mercurial salts. Under these conditions the most active and best solution is the following:

Mercury cyanid	0.01
Sodium chlorid	1.00
Distilled water	50.00

The foregoing solution represents a solution of mercury cyanid 1:5,000 with 2 per cent. of sodium chlorid. At first, a quarter of a syringeful is injected every second or third day, and the dose is progressively increased until a syringeful is reached. The injection is better borne, more quickly absorbed, and more efficacious when the liquid is injected at about a temperature of 32° C., and when a hot compress or an alcohol dressing is applied. The pain attending the injection may be abolished by the addition of a few drops of a 1 per cent. solution of acoin to the contents of the syringe.

Of all the mercurial preparations tried up to now the least painful and the best borne is mercury salicylarsenate, 1:500. Of this liquid two to six divisions of the syringe should be injected. Pain is little marked, and if one is careful to make the injection deeply, chemosis is scarcely visible. With this salt it is not necessary even to use acoin, which notably augments chemosis.

When the keratitis is clearly of tuberculous origin, we must give the preference to subconjunctival injections of 1 or 2 per cent. guaiacol. The basis of general treatment should be the administration of tuberculin. If too violent an ocular reaction is provoked by the tuberculin, pain and congestion may speedily be controlled by one or two local injections of guaiacol.

It should be remembered that it is not wise to administer many subconjunctival injections when they are not followed by a good result, and especially when they are badly borne. As soon as we perceive that a somewhat marked irritation is produced by the treatment, the injections should be made at rarer and rarer intervals, or they may even be suspended for a certain time, while insisting upon the necessity of general treatment and hygienic precautions. Real benefit in cases of this kind may follow saline baths.

Cases of parenchymatous keratitis are almost always complicated with iritis and often also with choroiditis. The treatment of these complications is discussed at length in the special sections devoted to the therapeutics of these infections.

Despite all treatment, there are often cases in which the cornea remains infiltrated and sometimes leukomatous to such a degree as to greatly limit vision. In such cases, should infiltration be central, optical iridectomy may be performed with advantage.

Corneal Opacities.

Slight and superficial opacities, when situated in front of the pupillary orifice, often cause a greater difficulty in vision than very thick leukomata which encroach only partially upon the pupillary area. Unfortunately, the treatment of corneal opacities is very discouraging. At first douches of vapor directed upon the cornea for five to ten minutes may be used. Afterward prolonged rotatory massage either with yellow ointment or with calomel, and once a week dionin, is applied to the eye. At home the patients may drop the following collyrium frequently into the eyes:

Oil of turpentine	5.0
Oil of almonds	5.0
Essence of cloves	1.0
Oil of almonds	9.0

Gomenol (*Malaleuca viridiflora*), a vegetable essence is stated to have clearing powers when used as an instillation in cases of parenchymatous keratitis and superficial leukomata.

According to Schermann, Brunner, and McGee, corneal opacites may be appreciably cleared by thiosinamin in doses of 0.06 taken for several weeks. Lately, instillations of thiosinamin have been praised:

Thiosinamin	1.0
Antipyrin	1.0
Sterilized water	10.0

In calcareous infiltrations there may be used as a collyrium:

Ammonium chlorid	4.0 to 10.00
Tartaric acid	0.02 to 0.10
Water	100.00

Good results have been obtained from subconjunctival injections of lithium benzoate, potassium iodid, etc. Caustic applications, such as concentrated citric acid, 50 per cent. lactic acid, the applications being well localized by strong hydrogen peroxid, and electrolysis have also been advised.

Opacities consecutive to too violent cauterizations with silver nitrate, even in cases in which the entire cornea is opaque, may be notably improved by eye-baths of sodium hyposulphite, 5 per cent., applied for ten minutes. After complete cocainization, the epithelium of the cornea is scraped away with the back of a Graefe's knife, so that the hyposulphite may penetrate the parenchyma of the cornea and there dissolve the infiltrated salts of silver (Marquez).

The surgical treatment of corneal leukomata has given some success. The leukomatous portions, after removal, have sometimes been replaced by transparent tissue. In extremely opaque leukomata a disc, removed by the trephine, has been replaced by a disc of transparent cornea.

Most of these operations, however, are unsuccessful. It is much better, as a rule, to tattoo the leukoma, especially as regards its prepupillary border, and then to practise a very small incision of the sphincter or an optical iridectomy.

Opaque staphyloma of the cornea is characterized by a more or less voluminous ectasia of the cornea rendered leukomatous and attenuated by previous ulcerous or inflammatory processes, and nearly always complicated by adhesions between the iris and the posterior surface of the cornea. Treatment proceeds upon purely surgical lines: 1. Complete ablation of the staphyloma, the iris, and the crystalline lens—Critchett's operation; 2, ablation of a semilunar flap from the cornea, followed by removal of the lens, suture of the corneal flap, with conjunctival autoplasty, in order to give a more solid and resistant cicatrix. The remains of the cornea may be tattooed, if the tissue is thick enough to give a stump of passable appearance, making in the center as black a pupil as possible. The cornea may be tattooed in various colors, as black, blue, and brown (Chevallereau and Porak).

Diseases of the Sclera.

Episcleritis may be readily diagnosed by dropping upon the conjunctiva a 1 : 1,000 solution of adrenalin. The conjunctival redness then disappears, leaving a more or less localized swelling, with deep vessels of violet hue. Sometimes these represent small nodosities of scleral tissue. The affection is connected, as a rule, with tuberculosis, syphilis, rheumatism, or gout.

Anterior sclerochoroiditis generally originates from primary lesions in the uveal tract. Inflammation which invades the medial layers of the scleral tissue diminishes the resistance of the latter. The sclerotic all around the cornea shows slate-colored spots, which when all hyperemia has disappeared, become blue by transparence. There ensues a progressive thinning of the sclerotic, which little

by little yields to the intraocular pressure. In this way there results an ectasia of the entire anterior segment of the eye, or staphylomata, localized to the most affected points. The choroid is nearly always involved. It is of the highest importance to act in cases of scleritis with energy and perseverance. Modern ophthalmologists admit that the great majority of cases of anterior sclerochoroiditis are due to tuberculosis or hereditary syphilis.

In the treatment of this disease at the beginning subconjunctival injections act by the specific power of the medicament employed and by the production of connective tissue, which gives more resistance to the thinned sclera. The cautery also acts advantageously, and if the intraocular tension is raised and synechiæ of the iris are present, an iridectomy should be practised. Staphylomatous ectasia may involve all the anterior segment of the globe, and it may be necessary to practise its total ablation by Critchett's operation.

Posterior sclerochoroiditis is generally caused by high myopia. Such lesions may be prevented by proper hygiene of the eye, the wearing of proper lenses, massage, etc. In acute attacks we prescribe leeches, the darkened room, mercurials, revulsives, and mustard foot-baths.

Scleritis and sclerokeratitis associated with the arthritic or rheumatic diathesis, are often quickly improved by administration of the preparations of salicin when employed in adequate doses. In simple rheumatic episcleritis, with the infiltration localized in the episcleral and subconjunctival tissues (the "subconjunctivitis" of von Graefe) without corneal complication and much pain, we use six to eight times a day a collyrium of adrenalin. As each instillation gives rise to marked anemia, we take the advantage to practise gentle, prolonged rotatory massage, which hastens the resolution and resorption of the infiltration beneath the conjunctiva. The massage may be made with different ointments, among others with mercurial lanolin, the powerful resolutive action of which is

known, and which gives excellent results in many cases of scleritis and episcleritis.

Should there be a suspicion of syphilitic antecedents, general mercurial treatment, by inunctions or injections, should be adopted without delay. On the other hand, if only rheumatism be in question, a 5 per cent. ointment of sodium salicylate should be used for the massage, and in cases of tuberculosis an ointment of guaiacol, together with dressings of salicylated alcohol.

In painful episcleritis pain may be often relieved by the use six to eight times a day of a collyrium of dionin. At the commencement of a gouty episcleritis, after two or three generous applications of dionin followed by a violent reaction, pain may disappear completely and episcleral infiltration become rapidly dissipated. Fresh and violent recurrences of episcleritis may be considerably improved by the action of powdered dionin. This affection, it is true, often occurs in the form called by Fuchs "episcleritis periodica fugax," but the instantaneous effect of dionin cannot be doubted.

When a rheumatic etiology is evident, the patient is given sodium salicylate or aspirin in doses of from 2 to 4 grms. a day. If severe pain persists in spite of aspirin and dionin, the following capsule should be prescribed to be taken at the moment of the violent crises:

Antipyrin	0.50
Phenacetin	0.30
Citrate of caffein	0.20

Sodium salicylate, when administered by the mouth, is often borne badly. It may cause ringing in the ears, and disturbances of the brain and stomach, which make many patients unwilling to continue its use. Aspirin has been praised as an agent which possesses all the virtues of sodium salicylate without any of its drawbacks. Insoluble in acid media, aspirin passes the stomach without alteration and is absorbed only in the alkaline fluids of the intestinal canal. In serious cases it is perhaps best

to inject into the veins sodium salicylate. Thanks to this means of administration, it is sometimes possible to bring about in a few days a rapid resolution of the morbid process.

The preparations of salicin are relatively less valuable in chronic rheumatism or gout; and, unfortunately, many cases of episcleritis or scleritis arise from this affection, which is often hereditary. In these cases after having employed for fifteen or twenty days at the most the preparations of salicin, alkalies, and lithium, brilliant and prompt results may often be obtained from colchicin. Granules of colchicin, each containing a half mgrm., are employed, and of these one to six a day are administered separated by equal intervals of time. Care must be taken to avoid large doses, which are extremely toxic. The patient should be warned to discontinue the medicine on the least appearance of colic, which may be very violent, and which constitutes the precise indication that the therapeutic effect has been obtained. It would perhaps be going too far to say that this reaction must be provoked if we wish to obtain a rapid and manifest curative effect. But it shows both the quality of the product and the limit of its physiologic action, which should never be pushed so as to reach a toxic effect.

Therefore, when there has been reached a dose which provokes colic, the administration of colchicin is discontinued for a day or two. After that, it is again given in the original dose of half a mgrm., which is augmented daily until colic is again produced. And this plan is continued for a month or longer at the most. If no therapeutic effect is produced, the reason is to be sought in the fact that we have not been dealing with a really gouty affection or that the patient is not responsive to this method of treatment. Under such circumstances we must seek for other means which will allow us to effect a cure. But before abandoning antirheumatic treatment, it is well to try the effect of the local application of sodium salicylate or of lithium.

either by subconjunctival injections (2 per cent.) or by dressings of salicylated alcohol. Other means that may be tried include vapor baths, diaphoresis by pilocarpin or by dry heat, light-baths, high-frequency currents, etc.

Punctate cauterizations of the scleral nodules is often useful. The galvanocautery, however, should be very delicate and be brought to a dull red heat. It acts rapidly, and its management is simple. The cauterizations have a potent revulsive action, at the same time that they provoke the development of connective tissue, which brings about rapid cicatrization. Finally, the powerful resolutive action of punctate cauterizations, slight but often repeated, is aided in a remarkable way by the continued employment of adrenalin, of which one drop of a 1 : 5,000 solution is placed in the eye every two hours.

In these cases also treatment has been advocated by ionization with salicylic or lithium ions (Courserant-Norsa). The constant current and the local application of overheated dry air have been recommended. The general health should be looked after in these cases, and it is sometimes desirable to complete the cure by a visit to a suitable spa, the employment of massage, and a course of physical exercise.

Sclerosing keratitis is not a morbid entity, but rather a nutritive disturbance of the cornea due to an impediment, bearing either upon the vessels or the nerves of the sclerocorneal limbus. In the majority of cases, however, sclerosing keratitis is of tuberculous origin. Most frequently it is a nodule of scleritis which compresses the organs essential to the nutrition of a sector of the cornea, which at this place accordingly becomes more or less opaque, opalescent and glaring. If the sclerotic change is not promptly stopped, the corneal opacity may become indelible. On the contrary, if treatment is applied in time, the corneal infiltration may undergo regression.

Episcleral nodosities, such as button-like scleritis (*la sclérite boutonneuse*), are often of tuberculous nature.

In these cases the best results are given by cauterizations, massage with iodoform or guaiacol lanolin, iodoform internally, and, lastly, general injections of tuberculin and especially subconjunctival injections of 1 to 2 per cent. guaiacol. In these cases guaiacol has really both therapeutic virtue and diagnostic value. Tuberculous episcleritis is more common than is generally reported.

In all serious cases the use of atropin is necessary, since there are often complications in the iris and the ciliary processes, and under these circumstances the treatment of the iritis becomes imperative.

CHAPTER XX.

DISEASES OF THE IRIS AND CILIARY BODY.

Iritis, Iridocyclitis, Iridochoroiditis.

The diagnosis of iritis is most important and very simple, yet it calls for great prudence on the part of the practitioner. There may be confusion with conjunctivitis when the patient is seen first with only a red, watering, and photophobic eye. An attentive examination with the binocular loupe shows whether there are exudations or deposits upon the iris or the anterior capsule of the crystalline lens, and when such are found all doubt is dispelled. In case there is not at hand a binocular loupe, we instill a drop of adrenalin or, better, of cocarenalin. In cases of simple conjunctivitis all conjunctival hyperemia disappears at the end of a couple of minutes. If, on the contrary, iritis is present, deep violaceous hyperemia persists around the cornea. After waiting for about half an hour, during which the cocain exercises its mydriatic power, the pupil will dilate freely and regularly if nothing beyond conjunctivitis is present, while if iritis exists, it will dilate badly, and allow exudations, more or less marked, to be seen upon the edges of the iris.

When iritis has already been present for some days, the diagnosis is readily made by the discoloration of the iris, the obvious ciliary redness, and the more or less irregular contraction of the pupil.

The diagnosis may be difficult in persons of an age when we may fear an early glaucoma, and we must then carefully avoid the use of atropin, or even of cocain, for fear of provoking an attack of acute glaucoma. Such cases must always be sent to the specialist, who will not

instil atropin until he has examined the eye with the binocular loupe and the ophthalmoscope and assured himself that the intraocular tension is not raised.

Iritis is generally due to an infection, which may come from the outside by an injury or an erosion of the conjunctiva or cornea. It may be propagated by contiguity from an affection of a neighboring tissue, such as keratitis, infective ulceration, episcleritis, etc. Lastly, it may be due to the localization of a general infection, among which may be mentioned syphilis, rheumatism, gonorrhea, tuberculosis, and acute infective diseases.

The pathologic evolution of the syphilitic, rheumatic, and gonorrheic inflammation is much the same for varying degrees of intensity, and includes hyperemia, cellular infiltration, exudations, decoloration, iridic synechiæ, and occlusion or seclusion of the pupil, capable of causing the most serious complications, such as glaucomatous degeneration or atrophy of the eyeball. The acuity of the inflammatory phenomena may depend upon the virulence of the infection, the resistance of the individual, and a number of other associate circumstances. Much trouble is taken even to-day to assign to the different infections a well-characterized clinical form. But, in general, it is possible to make the diagnosis of syphilitic or rheumatic iritis only by general examination of the subject and inquiry into his history, rather than by the particular specific form assumed by the morbid process.

Naturally, we speak here only of classical iritis and not of the more special forms accompanied by gummata, condylomata, or tubercles, which carry with them the more or less pathognomonic stigma of their origin. At the same time in many such cases the diagnosis is far from certain, for there exist mixed or doubtful forms, with regard to which the most competent authorities may hold very different views. Plastic iritis, exudative iritis, parenchymatous iritis, and suppurative iritis may represent different degrees only of an identical pathologic process

with general signs of redness, pain, and photophobia, and special signs of miosis, with a greenish disturbance in the color of the iris, which may very slowly undergo changes in hue. In cases of very acute iritis the various symptoms appear with great suddenness, are accompanied by violent pain and abundant exudation, and produce many adhesions between iris and capsule of lens. On the contrary, we sometimes observe insidious iritis, the development of which is so slow that the patient experiences no trouble at first and is brought to us by synechiæ, which may be so numerous as sometimes to necessitate surgical intervention. Between these two extreme forms a variety of intermediate cases finds place, and among these may be included serous iritis, which arises rather from an inflammation of the ciliary processes than from the iris itself.

The treatment of this important class of ocular maladies must be studied in detail, since the least mistake may entail the gravest consequences. Even the application of atropin, commonplace though it be, requires a certain experience. In many cases of glaucoma mistaken for iritis there has been loss of the eye by the untimely use of atropin; on the other hand, many synechiæ have resulted from insufficient mydriasis.

The first measures to institute when an iritis begins with violence, accompanied by lively reaction, photophobia, deep pericorneal injection, chemosis, and so forth, are those antiphlogistic in nature. The inflammatory phenomena must be subdued as quickly as possible, at the same time the pupil is dilated and the pain calmed. (The free use of hot applications should be given fair trial, before resorting to the medicinal anesthetics, analgesics, or narcotics.)

Antipyrin, phenacetin, quinin, and the preparations of salicin are, generally speaking, the anesthetics most to be recommended for subduing the ciliary pain and the violent headaches produced by iritis, but they fail occa-

sionally. Opiates cause sleep, but, they depress the nervous system, as do such agents as potassium bromid and paraldehyde. In case of intolerable pain, injections of morphin constitute our supreme resource.

When, in order to subdue the pain of an iritis or iridocyclitis, we employ energetic calmatives, it must be remembered that we depress all the faculties of the organism, the cerebral as well as the digestive functions. The heart and the circulation are often also affected by the free use or abuse of narcotics and general analgesics.

We possess in dionin an ocular analgesic of profound action and long duration, whereby the pain of iritis and iridocyclitis may often be calmed and sometimes be made to disappear permanently. For this purpose a few drops of a 5 per cent. solution of dionin should be instilled into the conjunctival sac. Chemosis, often of a very marked description, is set up by the application, and in the course of one or two hours the pain is attentuated and may often disappear completely. Under some circumstances the analgesic action of dionin is *nil*. In other cases suffering makes its appearance again at the end of twelve or twenty-four hours, when we must repeat the instillations. But as tolerance to the medicament is produced in two or three days, the pain then becomes more difficult to calm locally.

At the same time that we seek to relieve suffering, we must, before all, and at any price, safeguard or reestablish the freedom of the sphincter pupillæ by producing as wide a dilatation of the pupil as possible. For this purpose 0.5 per cent. atropin should be prescribed as a collyrium. The practitioner himself should supervise the first applications, which should be made every two hours until the pupil is completely dilated. After that, atropin is used twice a day or oftener so as to maintain complete mydriasis. The smaller the pupil the greater the need for atropin. Hot compresses and poultices will second the effect of the atropin.

Atropin is the most popular and the most trustworthy mydriatic. In cases in which dilatation of the pupil can be obtained by no other means, Fuchs recommends that we place in the conjunctival sac a small quantity of powdered atropin. We may resort to an even more powerful mydriatic, namely, scopolamin. A drop of the following formula should be placed in the affected eye three or four times a day:

Scopolamin bromohydrate	0.025
Cocain hydrochlorid	0.25
Distilled water	10.00

Dionin not only assuages ciliary pain, but also provokes the more rapid resorption of pupillary exudations and reduces the intraocular tension. In painful iritis, we should therefore prescribe the following collyrium to be instilled into the affected eye six to eight times a day:

Dionin	0.10
Cocain hydrochlorid	0.10
Atropin, neutral sulphate	0.03
Distilled water	10.00

This collyrium causes perhaps somewhat more smarting than the ordinary collyrium of atropin, but it now and then presents great advantages over the latter. Besides, dionin has the power of reducing intraocular tension, and thus prevents the risks of hypertension so often set up by atropin. When the iritis is slight and not accompanied by too much pain, it is preferable not to prescribe dionin at first, but to reserve this valuable but delicate agent for cases in which violent pain may appear. Should severe pain supervene in an eye which has become accustomed to dionin, the local analgesia of that agent may be impossible to obtain. There are very exceptional cases of plastic iritis in which dionin has provoked extremely marked miosis (Suker, Wray). This should be avoided by using atropin to the eye some hours before dionin is applied.

When iritis is accompanied by violent inflammatory

phenomena—pericorneal hyperemia, chemosis, swelling of the eyelids, radiating pains, intense photophobia, etc.—we need not hesitate to abstract blood locally, although this course has been decried by some clinicians the last last few years. Every impartial clinical observer who has witnessed the metamorphosis undergone by an exceedingly acute iritis after the application of two to four leeches to the temple, or even when one has been applied to the inner angle of the eye, will not be inclined to deny the efficacy of this ancient empiric remedy, even although the physiologic explanation of the phenomenon appears to him to be most unlikely. Yet it is most natural to think that organs as vascular as the iris and ciliary body, gorged with blood like a sponge, are unable in those conditions to respond to the influence of a mydriatic, while after local abstraction of blood the action of atropin is manifested with both rapidity and intensity.

Scarifications of the conjunctiva have recently been recommended for this purpose. Leeches, however, present an advantage over all the other means, such as wet cups of all kinds, bleedings, etc., for their application causes no pain, and they can under all circumstances be applied by the patient or by a lay attendant. It is certain, that after an adequate abstraction of blood the patient often opens his eye more readily, bears light better, and his pupil, which before failed to respond to atropin, becomes widely dilated after one or two fresh instillations. Orbital pain and headache also are notably reduced under the influence of the depletion.

There still remain cases in which, despite all the means described above, the violent pain cannot be subdued, and this is especially true when the tension of the eyeball is notably augmented. Under such circumstances we may be compelled to employ subconjunctival injections of sodium iodate or even have recourse to puncture. Paracentesis of the anterior chamber under such circumstances is apt to be very painful despite the previous

employment of cocain and adrenalin. Narcosis by chloroform or ether lasts too long, but that given by ethyl chlorid yields rapid and satisfactory anesthesia, followed by scarcely any sickness. The puncture may be made with a knife or with a syringe armed with a very sharp needle, since the cornea is extremely difficult to puncture. One may profit by the necessity for paracentesis by inoculating guinea-pigs with the fluid withdrawn for purposes of diagnosis, and replacing the liquid evacuated by an injection of sterilized air which often exercises a most favorable therapeutic effect.

As a rule, the measures named—mydriatics, dionin, leeches, etc.—supplemented by such general treatment as is indicated by the etiologic diagnosis, induce a prompt recession of the inflammatory processes and cure may result without further effort. But often patients return without serious relapses, because being free from pain after dionin applications, they believe that they are cured, and consequently stop all treatment. Patients should always be warned that they must not attach undue importance to the disappearance of the painful phenomena and that general treatment must be kept up until the complete disappearance of all signs of alteration in the iris.

There are cases in which other therapeutic measures of secondary importance are capable of rendering real service. For example, it is by no means rare to meet with cases of serious iritis which have resisted the most varied treatment and which are influenced very favorably by energetic intestinal derivation. A purgative strongly recommended is the following:

Calomel, vaporized..... 1.0
Scammony..... 1.0
To be divided into two cachets, one of which is to be taken at night for two successive nights.

Calomel possesses, in addition to its purgative action and cholagogic effect, a very marked antiseptic and resolu-

tive action. When iritis is caused by syphilis its action is particularly beneficial.

Cutaneous revulsives, as blisters, setons, the cautery, and mustard foot-baths, are still recommended by some practitioners, although their importance has probably been exaggerated. Nevertheless, it is well to understand how to employ these minor measures. To deny their efficacy merely because our physiologic knowledge does not yet explain their mode of action is unscientific.

It must not be forgotten that in certain forms of iritis rebellious to all treatment it is advisable so to vary our means of treatment that we shall never be taken unawares by the aggresive, incessant, and multitudinous recurrences of a disease born again, as it were, from its ashes. Rapid as is the tolerance of the organism to the most varied remedies, we must always have at our disposal some new means of action. There is perhaps no affection of the eye the evolution of which is so irregular as iritis and iridocyclitis, especially those forms which are connected with the rheumatic diathesis. We often see a relatively slight iritis, apparently checked at about the tenth day, exhibit a fulminating recurrence under some such influence as cold, bright light, eye strain, or other cause that often escapes careful surveillance.

Syphilitic Iritis.

The etiologic diagnosis of affections of the iris is far from always being precise and exact, and the indications that we are able to draw from it as often lack precision. When syphilis is admitted and its date is relatively recent, one may feel sure that this infection is the true cause of the iritis, although the exciting cause may be a chill, an injury, or any other casual irritant.

Syphilis is certainly the most frequent cause of iritis. At the same time syphilitic iritis can rarely be diagnosed by the aspect of the eye, unless it takes the form of a gum-

matous iritis. The gumma, or rather the condyloma, is readily visible and can scarcely be confused with anything else, unless it be a tuberculous formation, when the diagnosis may present real difficulties. The history may be conclusive, but there are often cases in which syphilis is denied, especially in women. Wassermann's serodiagnosis may then be of great service, allowing us to affirm with great probability the syphilitic origin of the disease.

Finally, when the diagnosis of syphilitic iritis has been made, general treatment as well as local measures should be adopted from the first day. It cannot be repeated too often that as valuable as local measures are, they must always be preceded, accompanied, or completed by general treatment. The best treatment of the ocular manifestations of syphilis is the administration of mercury by inunction, by subcutaneous injections or, best of all, by intravenous injections of the cyanid or salicylarsenate. The intravenous injections should be repeated at first every day and then every other day, according as they are more or less well-borne, until twenty or thirty injections have been given. By this means extremely severe iritis, even in broken-down subjects, may be cured in a very short space of time.

If intravenous injections cannot be made, we adopt general mercurial frictions in a dose of 4 grms. a day or administer pills containing 0.02 to 0.05 of the protochlorid or 0.02 to 0.03 of the bichlorid a day. It is essential that the treatment be always carried out under the direct control of the physician. Patients are always inclined to stop treatment prematurely.

Mercurial frictions around the orbit followed by the application of poultices, by their peculiar action on the infected lymphatic region, often form an admirable adjuvant. Potassium iodid has been much overrated in the treatment of iritis and of all the diseases of the uveal tract, in which its action is much inferior to that of mercury. It is indicated only when the iritis is almost cured; it has

hardly any curative action except in gummatous iritis. On the other hand, its prolonged use may consolidate the cure and prevent recurrences, more especially if its employment be alternated with more or less prolonged series of mercurial injections.

Subconjunctival injections of mercury cyanid have in certain subacute forms of iritis a remarkable therapeutic action. Atoxyl has recently been vaunted as a remedy whose antisyphilitic action is comparable to that of mercury and potassium iodid. Cases of iritis have been cured rapidly after four or five injections of 0.5 of this arsenical product. But as serious accidents (gastrointestinal and hepatic disturbances) have been produced as the result of these large doses, it is advisable to act with much prudence in dealing with so active a medicament. In men we inject 0.50 of atoxyl into the buttocks three times during the first week, twice during the second, and, lastly, a sixth injection may be made a week after the fifth. In women the doses should be 0.40 only, and if abdominal pain or nausea supervene the interval between them should be lengthened. Syphilitic iritis, in general, is apparently cured after six injections have been given; but, nevertheless, mercurial treatment should be instituted; for, in spite of all, this is the specific treatment for syphilis. Atoxyl is valuable during the periods of mercurial repose, but it must be employed only with circumspection in affections of the fundus oculi and of the optic nerve, inasmuch as several cases of atrophy of the optic nerve have already been published consecutive to the administration of large doses of this substance. According to Ehrlich and Neisser, arsacetin (sodium acet-arsanilate) possesses the same antisyphilitic action as atoxyl without being toxic. Its solutions are very stable.

Rheumatic Iritis—Gonorrheic Iritis.

Although the distinct diagnosis is difficult and often doubtful, at the same time it is recognized that an appre-

ciable proportion of the cases of iritis are of a rheumatic nature. Should an attack of gonorrhea precede or be synchronous with iritis, the relationship is determined; but when there is present merely an endometritis or "a morning drop," the nature of the iritis may be overlooked.

In blennorrhagic iritis, especially in the acute form, there is sometimes seen an exudation into the anterior chamber so fibrinous and abundant that when it begins to retract, it may be mistaken for a dislocated crystalline lens. This appearance, however, must not be looked upon as peculiar to blennorrhagia, for many other infective maladies, and rheumatism in particular, may be the cause of abundant exudations into the anterior chamber.

Goldzieher regards potassium iodid as the specific for blennorrhagic inflammation of the iris. In general, sodium salicylate in doses of 3 to 5 grms. a day, and aspirin in the same doses should be regarded as the base of the treatment of these forms of iritis. The intravenous injection of sodium salicylate is even more efficacious and does not provoke the symptoms of intoxication which may follow the administration of that salt by the mouth. Many patients treated by aspirin or salicylate,taken at first by the mouth and then subjected to the intravenous injection of salicylate, have been rapidly cured. Even when the blennorrhagic origin is manifest, salicylate gives very good results. It goes without saying that the urethral discharge should be energetically treated at the same time.

In certain very grave cases of blennorrhagic iridocyclitis, in which all the classical means have failed, curative results have been obtained rapidly by about a dozen intravenous injections of collargol in progression from 0.04 to 0.10 a day. In two of the observed cases there were also very tenacious articular pains. In a third case a rebellious episcleritis was promptly cured by injections of collargol.

The very acute forms of iritis which are often of rheumatic nature, can be cured, as a rule, easily and quickly.

More than ever should local and antiphlogistic treatment be continued with general treatment, and more than ever should treatment be kept up for a long time, and great precautions must be taken to avoid the relapses so common and easily induced in all affections which proceed from a rheumatismal infection. Indeed, we might almost term recurrent iritis rheumatic iritis. There are periods when the medical man sees return to him almost at the same time, all his patients affected with rheumatic iritis, the recurrences being due to rapid changes in temperature brought about by humid and cold weather.

When rheumatic iritis becomes chronic, its treatment becomes most difficult, and the practitioner should call to his aid all the means indicated for dealing with rheumatism, such as hygienic precautions, special régime, avoidance of dampness, sunlight, fresh air, physical exercise, dry rubbings, vapor-baths, light-baths, massage, diaphoresis by pilocarpin, etc.

Tuberculous Iritis.

The study of ocular tuberculosis has made immense progress thanks to the more generalized employment of tuberculin. Tuberculous iritis is now recognized more often and more readily, and may be treated with more chance of success. Another means of diagnosis and of treatment of great service clinically has been found in guaiacol, which may be regarded as the antituberculous specific much in the same way as mercury is in syphilis.

In presence of a supposed tuberculous iritis, then, the first indication is to endeavor to obtain a reaction by tuberculin, which serves both as a means of diagnosis and also as a method of treatment. Cure by this means is slow, although it may be hastened considerably if with it is associated treatment by guaiacol.

The plan of treatment to be pursued is as follows: The local and general reactions characteristic of the disease having been obtained by hypodermic injections of

tuberculin, we apply guaiacol locally, either by rubbing, twice a day, a 3 per cent. guaiacol ointment into the parts around the orbit, or by applying to the eye dressings of 2 per cent. guaiacol-alcohol. Lastly, if they are well borne, we may make once a week a subconjunctival injection of cacodylate of **guaiacol** (2 per cent.), alternated with injections of sterilized air. Thanks to these means, which have at the same time a special antituberculous action, the doses of tuberculin may be increased more rapidly and in this way cure be notably accelerated.

In cases in which tubercles of the iris are numerous or voluminous and deposits are present in the anterior chamber, it is advantageous to aspirate the cloudy aqueous humor with a syringe and to replace the fluid by the injection of sterilized air. For that purpose we employ a syringe armed with a very sharp and short needle of platinum-iridium, first well heated in a flame. The instrument should be half-filled with air drawn through the needle brought to a red heat in the flame of a spirit lamp. The needle having penetrated subconjunctivally into the anterior chamber, the liquid is lightly drawn into the instrument, great care being taken not to wound the iris, the crystalline, or Descemet's membrane. The syringe being held with the needle upward, the aspirated liquid naturally falls to the bottom of the instrument and the air rises to the top. On pushing the piston, air then penetrates into the anterior chamber. Not more than a quarter of a cubic centimeter must be injected, and the tension should be closely watched in order to make sure that it does not rise above normal. Air thus injected forms a large bulla, the resorption of which may occupy several days. The pupil should be kept as large as possible by the repeated instillation of atropin. The injections of sterilized air may be repeated according to the way in which they are tolerated. The liquid withdrawn from the anterior chamber may be used for inoculation of the guinea-pig and also for microscopic examinations.

Unhappily, if not treated energetically at its commencement, tuberculous iritis may entail such serious consequences that enucleation often may be necessary. The operation is performed to avoid generalization. It is difficult to decide whether the eye lesion is primary or secondary. We must not for fear of generalization practise the removal of an eye that might be retained. In these circumstances the conduct of the practitioner must be guided by his clinical acumen.

In metastatic purulent iritis or iridochoroiditis the treatment of selection is paraspecific serotherapy along with such local antiseptics as are recommended in traumatic iritis and iridocyclitis and infected wounds of the cornea. In several cases of purulent iridocyclitis of the most serious nature, antidiphtheritic serum, administered either by injection or by the mouth, has brought about in eight to ten days the complete disappearance of pus from the anterior chamber, no other means being adopted except 40 to 50 c.c. of serum (8 to 10,000 antitoxic units of Behring). In two cases sight became normal; in the third the eye had been affected with detachment of the retina for several years (Darier).

Local Indications in the Treatment of Iritis.

In syphilitic iritis when the first assault upon the morbid process has been made by general treatment and mydriatics, and the violence of the symptoms has been attenuated and the ground prepared by those measures for a more energetic local intervention, brilliant results may be sometimes obtained by the **subconjunctival injection of mercury cyanid.** After a fortnight's treatment by general measures and the instillation of atropin, the pupil having kept its irregular form as the result of posterior synechiæ, we may see the pupil dilate completely after a single injection either of two or three divisions of a 1 : 1,000 solution of mercury cyanid or a half-syringe of a 1 : 5,000 solution of the same salt. Several

injections, however, may be called for in order to arrive at this result. Many observations of this kind have been reported by different authors. In order to secure the desired result, the eye must be in a state of favorable receptivity and ciliary irritation must not be too violent. The contrary conditions furnish a contraindication to the employment of subconjunctival injections. It is then better to rest contented with leeches, hot compresses, alcohol dressings, mercurial poultices, etc.

Certainly, the cases most favorable to these local interventions are the so-called gummatous iritis when a yellowish oval elevation, which deforms the pupillary orifice, is observed, without producing too marked a hyperemia. In cases of this nature after two or three subconjunctival injections, in the course of five or six days, we have seen large gummata melt away almost under the eye. Such patients, however, must be warned as to the necessity of prolonged general treatment for fear of even graver relapses.

A case in point was that of a female, aged fifty-five years, affected with grave senile syphilis and violent iritis with condylomata and hemorrhages of the iris, in whom the pupil refused to respond to atropin even after ten days' treatment with periorbital inunctions and hypodermic injections and the repeated application of leeches. In this patient a single subconjunctival injection of sublimate was followed by lively reaction, and two days after the pupil was dilated and the iritis tended toward cure.

The following case shows again how often syphilis is ignored, then the remarkable antiglaucomatous action of subconjunctival injections of sodium iodate and, lastly, the powerful action of subcunjunctival injections of the mercurial salts. The patient presented slight descemetitis without as yet any change in the iris; the pupil, in fact, dilated well and regularly without any deposits upon the anterior capsule of the crystalline lens. Violent inflammatory phenomena suddenly appeared: the pupil was no

longer round, but oval and a little decentered, and there was the impression of a gumma of the ciliary body of the size of a large grain of wheat lying behind the iris at the level of the ciliary processes. Those points were recognized through the cornea, which was cloudy and edematous, by a sharp elevation of intraocular tension, as well as by striations of whitish infiltration. The tension was notably reduced by dionin, followed by subconjunctival injection of sodium iodate, 1:1,000, and a couple of leeches to the temple. Great improvement followed three subconjunctival injections of mercury salicylarsenate. The gumma seemed to diminish from day to day, and after five injections had been given in twelve days, the pupil became circular, the peripheral elevation was scarcely visible, the cornea was much clearer, the tension was normal, and vision rapidly improved.

In the foregoing case mercurial treatment was urgent, but its adoption was impossible owing to diseased state of the kidneys; without subconjunctival injections, the eye would probably have been lost.

But it is not only in syphilitic subjects that the resolutive action of the injections is seen. In one case small granulomata of the iris disappeared so rapidly under the influence of three or four injections that we concluded that what had been taken at first for tubercle was merely an atypical form of syphiloma of the iris. Yet a year later the patient died from tuberculosis. It is certain that a syphilitic subject may succumb to tuberculosis, but it must be admitted also that in the absence of more precise data the tuberculosis in this individual began with slight granulomata of the iris.

All forms of iritis or iridochoroiditis are not benefited to the same extent by subconjunctival injections. Apart from those cases which improve sometimes in a surprising way, there are others which fail to respond from the treatment. Indeed, there are even cases in which an acute attack may be precipitated by an untimely inter-

vention, and others in which a clumsily performed injection brings on such pain that the patient refuses all further attempts of this kind. Therefore, we must not invariably urge the employment of subconjunctival injections for most of the cases of acute iritis can at first be cured perfectly without them. This energetic means should be reserved for the particular class of cases already indicated.

Generally speaking, the practitioner will find in subconjunctival injections a valuable adjuvant to general therapeutics and even a substitute which will give a salutary rest to an organism saturated with medicines. These alternations of local with general treatment cannot but be very favorable to ultimate cure.

In certain exceedingly grave forms of iridochoroiditis, with violent attacks of inflammation and glaucomatous tension, when energetic interference is urgent and cannot be delayed under pain of serious consequences there can be no question of iridectomy, which would not be possible under these circumstances. Subconjunctival injections may then render the greatest service, on the express condition that they are combined with paracentesis of the anterior chamber. The puncture evacuates the altered fluid from the anterior chamber and provokes a salutary retardation of the whole ocular circulation. Even an abundant subconjunctival injection is speedily resorbed and contributes powerfully to the renovation and wholesomeness of the intraocular fluids. Truly remarkable results may be obtained by the combination, repeated more or less frequently, of evacuation of the aqueous humor with subconjunctival injections. In these cases more or less concentrated liquids should be employed in proportion as we believe they will be well borne. In general, we shall do well to inject a syringeful of the following solution:

Mercury cyanid	0.01
Sodium chlorid	0.10
Distilled water	50.00

There are cases of iridochoroiditis with hypotony, which often end in atrophy of the eyeball, in which subconjunctival injections have produced such a transformation that more or less complete cure has been obtained, even though the eye had been looked upon as lost. In an iritis definitely rheumatic in origin, the subconjunctival injections of 2 per cent. sodium salicylate, made at the opportune moment, render very great service, as injections of guaiacol have, as it were, a specific action in tuberculous affections of the eye.

It must never be forgotten that in cases of chronic iridochoroiditis, with deposits upon Descemet's membrane, synechiæ, and vitreous opacities, cure can be reached and blindness avoided only by desperate treatment kept up for two, three, or even for five years. In these cases, then, the medicaments must be varied. Mercury, given by **intravenous injection,** should be the foundation stone of the treatment. To begin with, the injections should be made every day, and when the first signs of intolerance manifest themselves, every second day only. When thirty or forty injections have been made, the veins should be given a period of rest, making meanwhile a series of subconjunctival injections or injections of air into the anterior chamber. The patient is then given several days of rest with hygienic needs, such as fresh air, exercise, massage, overfeeding, etc. At the end of the third month, a new series of intravenous injections of mercury cyanid should be made, supposing that the first series succeeded well, but in the contrary event, we should try a series of ten injections of collargol, of 0.04 to 0.10, every day, then every other day. We may also administer several series of pilocarpin injections. Lastly, in cases in which these measures have not succeeded or have lost their effect there is another method which may be of great service, namely, **iodic medication.** This does not consist in administering potassium iodid, but in injections of Lugol's solution or, better, of Tourneur's leukolytic preparation of iodin. After

ten or twenty of these injections, we return to mercurials. It is possible that in atoxyl we may find a valuable aid.

Sympathetic Ophthalmia.

We should not consider exclusively infective sympathetic iridochoroiditis, as the infection is caused by direct or indirect migration or may originate by endogenous infection by autointoxication favored by ciliary vasomotor irritation. Simple sympathetic irritation, produced by a painful stump, is an irritative reflex, which disappears immediately after the exciting eye has been enucleated.

The sympathetic ophthalmia evolves in the following way: An eye has suffered from an injury, operative or accidental, following which a more or less intense infection is produced, but which ends in apparent cure, since if the eye suppurates completely sympathetic ophthalmia is never produced. Infection, therefore, remains in the injured eye in a latent state, as it were. It invades the ciliary body, then the choroid and the optic nerve, and reproduces itself on the opposite side, where it provokes typical infective iridochoroiditis, which sometimes begins in the optic nerve, but which shows its presence clearly only when it has affected the ciliary body and the iris. The difficulty of identifying in anatomic preparations the route taken through the optic chiasm leads us to inquire, even at the present day, the way in which sympathetic ophthalmia is transmitted from one eye to the other. This much is certain, that true sympathetic iridochoroiditis is recognized by everybody as a process of infective origin.

Treatment.—We understand that the cause of the affection is a microbic infection, the origin of which is a focus in the eye originally wounded. The first indication, therefore, should be to remove that eye, the primary source of infection, without unduly considering the amount of sight that it may still retain. After the eye has been

removed, together with as much of the optic nerve as possible, we inject deeply into the orbit as far as the optic foramen and even if possible into the nerve and its sheaths a syringeful of a 1 : 500 solution of cyanid of mercury. Then, taking advantage of the narcosis induced for the operation of enucleation, we inject deeply beneath the conjunctiva behind the globe affected with sympathetic ophthalmia a syringeful of a solution of mercury cyanid, 1:1,000. A dressing is placed over both orbits, and on the following day two to four leeches are applied to the temple, and the patient is submitted to an energetic mercurial course by means of inunction of 4 grms. a day of mercurial lanolin. As soon as the subconjunctival injection has been properly absorbed and all chemosis has disappeared (about the fourth day on the average) we do not hesitate to make a second injection and maintain the effect by the application of two or three leeches to the temple. The depletion of blood effected by this means reduces the ciliary hyperemia and the chemosis which result from the liquid injected.

In the interval between injections a few drops of the following collyrium should be instilled every half-hour:

Atropin sulphate	0.03
Dionin	0.10
Cocain hydrochlorid	0.10
Solution of mercury cyanid, 1 : 1,000	10.00

In proportion as improvement shows itself by a more complete dilatation of the pupil, the diminution of exudations upon the posterior surface of the cornea, and the disappearance of photophobia and ciliary hyperemia, we diminish the number and the strength of the subconjuntival injections. At the same time we must be very careful not to stop all treatment prematurely; for relapses of sympathetic iridochoroiditis, more than any others, are most dangerous, and we run a great risk of losing the mastery if treatment is abandoned before we have extinguished all trace of infection.

Recurrences of sympathetic ophthalmia may arise

even after years of apparent cure, and they are of great gravity, and often lead to loss of sight. Under such conditions we should proceed as follows: 1. Resect the extremity of the atrophic optic nerve. 2. Inject into the bottom of the orbital funnel a syringeful of mercury cyanid, 1:500. 3. Inject beneath the conjunctiva of the sympathizing eye a syringeful of mercury cyanid, 1:3,000. 4. Practise every day general mercurial frictions. Lastly, this treatment may be followed by several séances of sweating by pilocarpin and sodium salicylate. Thanks to this energetic treatment, several eyes have regained good sight after a grave recurrence of sympathetic ophthalmia (Abadie, Darier). It is said that in sympathetic ophthalmia large doses (4 to 6 grms.) of sodium salicylate give even better results than mercurial inunctions (Lindhall-Widmark).

Zur Nedden has tried the effect of injecting serum, taken from individuals suffering from sympathetic ophthalmia, into other persons having the same disease. This is, however, a serum almost impossible to obtain. In these cases we may always practise paraspecific serotherapy, but without ever neglecting the local treatment already described.

A long experience with subconjunctival injections has shown that an injection made on one side manifests its therapeutic action upon the second eye as well.

Under certain circumstances it is possible to check sympathetic ophthalmia while retaining both eyes. Several cases of this nature have been published since the introduction into ocular therapeutics of subconjunctival injections of mercury cyanid. But the risk run is so great (often the loss of both eyes is the price of tardy enucleation) that such practice is not to be recommended to young practitioners.

Enucleation, then, should be the rule in the majority of cases, and should be considered imperative when the eye exciting sympathetic ophthalmia is in such a state as to pre-

clude the hope of its regaining useful sight. When, on the contrary, the disease is in its incipiency, when the two eyes possess almost the same vision, it is but natural, before resorting to enucleation, to try the effect of conservative treatment. The steps that should be taken may be summarized as follows: 1. Apply the galvanocautery to every infected part of the wound, even if in doing so the platinum loop at white heat must be pushed into the crystalline or even into the vitreous. 2. Cover the wound, first cleansed and vivified, with a flap of conjunctiva fixed in place by several sutures. 3. Inject a syringeful of mercury cyanid, 1:1,000, deeply into the orbital tissues. As complements, antiinfective serotherapy may be practised, to be followed at an interval of several days by a course of mercurial inunctions, succeeded by sweatings by sodium salicylate and pilocarpin. As regards the sympathizing eye, subconjunctival injections should be practised in accordance with the clinical indications. Although several cases of sympathetic ophthalmia have been thus cured without enucleation, yet great prudence cannot be too strongly urged, and in really serious cases we must not hesitate to remove the exciting eye.

When it is possible, as recommended by Haab, to introduce a small rod of iodoform into the anterior chamber, this may be a valuable adjuvant, but cases of sympathetic ophthalmia have been known to supervene even after such treatment.

Panophthalmitis or abscess of the eye is usually the consequence of a traumatic or operative infection, although it may also be metastatic in origin. It is generally provoked by the penetration into the vitreous body of the pneumococcus, although other microbes, including among the number the B. subtilis, the B. pyocyaneus, and the B. perfringens, may rarely be the cause.

An eye affected with panophthalmitis is lost. As soon as we recognize that all hope is lost, the eye should be enucleated. If suppuration is too advanced, if there

is panophthalmitis and edema of the eyelids, it is better to perform evisceration or the evacuation of the globe by means of the thermocautery; since after enucleation in such cases we have reason to fear death from septic meningitis.

The Surgical Treatment of Iritis.

Chronic or relapsing iritis, terminates often, especially among aged persons, in more or less complete loss of vision. In fact, there is set up a progressive atrophy of the iris and ciliary body, which causes, by inadequacy of secretion, a softening of the eyeball, which may go on to complete phthisis, or the trophic disturbance may cause opacity of the crystalline, complicated cataract, always difficult to treat surgically.

At other times, repeated attacks of iritis leave pupillary synechiæ, more or less thick and numerous, the entire pupil becoming soldered to the capsule of the lens—the condition known as **"seclusion pupillæ."** Atropin is without effect in these cases, or its employment may even provoke hypertony. Its use must, then, be discontinued, and recourse must be had to miotics.

The aqueous humor secreted by the ciliary processes, being no longer able to penetrate into the anterior chamber, pushes the iris forward and glues it to the cornea. From this an augmentation in tension generally arises. Against this glaucomatous state we must act by performing, as speedily as possible, in iridectomy, an operation which, had it been practised after two or three relapses of iritis, would have prevented such a complication.

Iridectomy under these circumstances is difficult. In cases of seclusio pupillæ the incision through the cornea without at the same time wounding the iris, becomes difficult or even impossible. Many surgeons do not hesitate under the circumstances to traverse iris and cornea at one stroke, so as then to seize the iris from behind, to draw

it forward, and to excise it. This operation, however, has the disadvantage of exposing the crystalline to injury and of provoking hemorrhage from the iris, which may so complicate the operation as to compromise its final result.

In these cases, we proceed as follows: Taking a lance-knife in each hand, we penetrate the anterior chamber at two opposite points, distant one from the other some 6 mm. to 7 mm. The point of each knife should penetrate into the anterior chamber, and push back the iris without traversing it. The two blades are then withdrawn. By means of a fine knife with protected point passed in by one of the incisions and out by the other, we cut the bridge of cornea which separates them. In this way the anterior chamber is widely opened, without the loss of a drop of blood or the iris having been injured. Iridectomy may then be performed with the greatest facility and in the best possible conditions for success.

This procedure may render signal service under many other circumstances, as in certain cases of glaucoma and of complicated cataract, and in some corneal staphylomata—in short, whenever effacement of the anterior chamber renders keratotomy difficult.

Isolated posterior synechiæ may now and then be ruptured by the alternate instillations of eserin and atropin, although in this case we should wait until the inflammatory period has passed.

The surgical rupture of the synechiæ by means of hooks or forceps has little to recommend it. When two or three recurrent attacks of iritis have come about at intervals of some months, it is better to perform a good iridectomy, which often prevents new attacks of inflammation. In preventing relapses of iritis, iridectomy is successful in 81 per cent. of the cases; it brings about an improvement in sight in 62 per cent.; vision remains the same in 28 per cent.; and sight is diminished in 10 per cent. In iridochoroiditis accompanied by reduced tension, the pressure is rendered normal in 70 per cent. of the cases, while

sight is improved in 28 per cent. and remains without change in 69 per cent. (Hallauer).

As general measures in cases of iritis, we must before everything prevent pupillary contractions by absolute rest of the eyes and protection against light by means of dark glasses (preferably yellow or dark brown). Rest in bed is necessary only in very grave cases.

CHAPTER XXI.

DISEASES OF THE CRYSTALLINE LENS.

Congenital aphakia is usually noticed in badly-developed microphthalmic eyes. The selection of proper glasses is the only treatment indicated. It is the same in cases of **coloboma** of the crystalline and in anterior or posterior **lenticonus.** Under some circumstances, however, extraction of the lens or optical iridectomy may have to be considered. The same remark applies to congenital **ectopia** of the crystalline. **Persistence of the hyaloid artery** often manifests itself by a posterior polar opacity.

Congenital cataract may appear under several forms. There is usually an hereditary familial cause, although this often skips a generation.

Zonular cataract is characterized by an opacity which occupies the layers intermediate between the nucleus and the periphery, although it is rare for the central parts to remain completely transparent. In general, sight is very defective, even with the best chosen glasses. When the cataract is central or nuclear, and when the peripheral parts are very transparent, fair sight may be obtained by performing optical iridectomy, which has the advantage of allowing preservation of accommodation.

Pyramidal or anterior polar cataract, whether congenital or consecutive to a perforation of the cornea, has the same indications. In general, a very small iridectomy gives good results.

Removal of the Lens.—When congenital cataract is total, or when the foregoing forms are too pronounced to secure an adequate optical result, the cataractous lens must be removed by surgical means, for nothing is to be

hoped from medical treatment in these cases, and even specific treatment in hereditary syphilis yields no result. In children, we generally prefer to induce resorption of the crystalline by successive discissions rather than by performing the immediate extraction of an incompletely opaque lens. Dressings and after-treatment are, in fact, very difficult in subjects whose age precludes the possession of judgment.

Discission may be readily carried out with a curved needle. By rotating the handle the capsule may be widely dilacerated as well as the crystalline masses, without any risk of dislocating the lens, the needle acting always in the direction of its cutting-edge (Darier).

Preference should be given to **simple extraction,** with or without aspiration, even in infants, when we are dealing with white and soft cataract, and especially with semi-fluid cataract (Morgagnian cataract). In all these cases it is sufficient to make a very large incision with the keratome, and to evacuate the diffluent crystalline masses from the capsule by the means of the cystotome. The masses may then be expelled from the eye by pressure, combined with the use of the curet. Should all the masses not be got rid of by these means, they may be sought with Daviel's curet or aspirated by means of a special syringe. It is sometimes advisable also to irrigate the anterior chamber with physiologic salt solution at a temperature of 36° C.

Extraction or aspiration of cataract in the child should always be carried out under anesthesia by ethyl chlorid or chloroform. The pupil should previously be dilated *ad maximum* with atropin, and the same drug which may be used in ointment form should be placed in the conjunctival sac before the dressings are applied. Atropin should also be applied every time the eye is dressed after the operation, but care must be taken not to produce an attack of glaucomatous hypertension. In this event physostigmin is to be at once substituted for atropin; dionin should be applied, vibratory massage should be employed, and

especially, subconjunctival injections of 1:1,000 sodium iodate should be made. At the same time, as the cause of the increased tension is the too rapid swelling of the crystalline masses, the surest means of relief is evacuation of the swollen masses by puncture of the cornea. Iridectomy should be performed at the same time if there is entanglement of the iris or capsule.

Wounds of the crystalline are not uncommon. In **contusion** of the eyeball, without penetrating wound, we may see, in addition to disturbances of the pupil, a tear or a simple distention of the fibers of the suspensory ligament of the crystalline. In young subjects whose crystalline elements still possess good elasticity, the lens being no longer enclosed in the zonular fibers, tends to assume its normal form and thus to enlarge its anteroposterior diameter. From this results a **traumatic myopia** (Darier), which may reach 2 to 8 diopters, according to the age of the subject and the violence of the contusion. If the blow has been a lateral one, the relaxation of the zonule may be partial only, and we then observe a lateral displacement of the pupil, which is usually oval, and at the same time more or less marked **astigmatism.**

In order to obviate these optical disturbances, we prescribe a 2 per cent. collyrium of pilocarpin to be instilled two or three times a day. Although the adoption of this empirical means may appear paradoxical, yet its value is established. Vibratory massage may also be adopted, but it must be applied very gently and at sittings separated by intervals of some length.

Lastly, the injury may be so violent as to completely **rupture the zonule of Zinn,** and to expel the lens from its place. Under these circumstances the crystalline is said to be dislocated, partially (subluxation) or completely (luxation).

In **subluxation** the lens is only slightly displaced laterally, but it remains within the pupillary field. The pupil in these cases is somewhat displaced, dilated, and

oval. As a rule, the iris and the crystalline tremble with each movement of the eyeball (**"tremulous iris"**). In a somewhat higher degree, the edge of the lens may be visible in the pupillary aperture. With the opthalmoscope, the fundus of the eye is readily seen either through the lens, as in a normal eye, or by its side, as in aphakia. Monocular diplopia is often observed in these cases. In every instance vision is compromised, and the refraction of the eye undergoes modification. Thus, through the crystalline the patient sees clearly only with correcting glasses, generally concave or cylindric, while he can read only with strong convex glasses (plus 12 D. or plus 15 D.) through the aphakic part of the pupil.

In these cases medical treatment has little effect. Miotics may be useful by causing the diplopia to disappear, and, whenever such is possible, bringing the pupil opposite the crystalline lens. Expectation is the only indication in these conditions. Glaucomatous complications are much rarer than in cases of complete luxation. But in subjects aged and predisposed to glaucoma we should hold ourselves ready to perform iridectomy. The employment of eserin or of pilocarpin, then, is here the best empiric treatment.

Complete luxation of the crystalline lens may take place behind, into the vitreous body; forward, into the anterior chamber; or laterally, under the conjunctiva, when the sclerotic has been ruptured. Lastly, when the conjunctiva yields, the lens may be expelled completely from the eye, with more or less abundant loss of the vitreous humor.

Conservative treatment consists in rest and the employment of miotics. When, however, the lens lies in the anterior chamber, it should be removed as quickly as possible. In general, this should be undertaken under general anesthesia by ethyl chlorid if one believes that adequate insensibility cannot be secured by cocain, or that cocain may increase the hypertension. The cornea is incised by means of a very narrow Graefe knife, so that

it may traverse without undue resistance the peripheral layers of the crystalline lens, a thing almost impossible to avoid under the circumstances. In these cases it may be advisable to practise incision of the cornea by the method already described.

In order to lose as little vitreous as possible, the extraction should be carried out with very careful avoidance of pressure on the cornea. The crystalline may also be harpooned by a hook introduced into the anterior chamber from one of the ends of the incision, and by a movement of tangential traction a movement of rotation is communicated to the lens, which causes it to emerge much more readily.

When the lens is dislocated into the vitreous body it should almost always be extracted by means of the curet or, rather, the Snellen or Milleé loop, since the production of glaucomatous accidents is always to be apprehended. But if these complications are present, it is very difficult to practise the extraction correctly, and under such circumstances even an antiglaucomatous iridectomy is powerless to save the eye.

The removal of a mobile crystalline lens from the vitreous body is one of the most delicate operations in ophthalmic surgery, since the crystalline tends always to escape from the loop. The following procedure may be tried: By means of a curved and extremely sharp hook, the sclerotic is traversed behind the equator, and (under the guidance of the ophthalmoscope) the crystalline is held lightly applied against the wall of the globe. The hook is then entrusted to an assistant, and we proceed to incision of the cornea and extraction, the loop taking the place of the hook, which should be withdrawn except as regards its point (Abadie). There is always a notable loss of vitreous humor.

Traumatic Cataract.—Wounds of the crystalline lens are generally produced by perforating traumatisms, by pieces of steel, copper, stone, glass, etc., or by sharp in-

struments, such as needles, steel pens, knives, scissors, etc. Under these circumstances a traumatic cataract is the result.

Traumatic cataract by simple contusion of the eyeball is also observed, but it is often long after the accident that the patients observe that their sight has fallen, and that the physician finds more or less complete opacity of the crystalline. If the contusion has produced a tear of the posterior capsule, the opacity is much more rapid, and the cataract is usually soft and white.

In penetrating wounds, if the injury has been so slight that the capsule of the lens alone has been wounded and only over a small area, the resulting opacity of the crystalline lens may be so slight that, if no infective complication ensues, we may abstain from all interference. The same applies to cases in which the injury has been somewhat peripheral, so that sight remains almost intact.

On the contrary, if the opacity although very slight lies in the pupillary orifice, we are compelled to perform an optical iridectomy opposite the most transparent part of the crystalline lens. Cases have even been reported in which wounds of the lens have healed completely, with perfect resorption of the resulting opacities.

We also sometimes see very small foreign bodies, which have penetrated by an injury into the interior of the crystalline, remain *in situ* for years without provoking the formation of complete cataract. The opacification remains confined to the parts around the foreign body. These cases, however, are exceptional. Usually, the lens, wounded however slightly, becomes white and opaque, the more rapidly as the more widely and more deeply the capsule has been opened. Under these circumstances we observe the crystalline substance imbibe the aqueous humor, swell, protrude through the anterior capsule, and sometimes fall in clumps into the anterior chamber. The lens may become completely opaque in the course of a few days. If the subject is young, and surgical inter-

vention has been necessitated by no complication, all these masses may be resorbed spontaneously, so that at the end of several months we see in the pupillary area nothing except a more or less opaque membrane, which represents the crystalline sac, together with some débris, which soon becomes infiltrated with calcareous salts.

Eyes so injured may sometimes be left in the condition described, although more frequently the whitish aspect of the pupil necessitates the extraction of the capsular cataract. The cornea is divided with a knife, and, by means of a toothed forceps, the capsule is firmly seized, and extracted by making very light and progressive movements of traction in every direction. If the traction is not too violent and if the hyaloid has not been ruptured, there is no loss of the vitreous humor. In these cases discission, while giving very good optical results, is not usually satisfactory when we are particularly desirous of obtaining a perfectly jet-black pupil.

In general, surgical intervention is the rule in wounds of the crystalline lens, and it should be undertaken as soon as possible, because there is usually at the same time a wound of the iris, cornea, and sclera. Above all, then, care must be taken to close the wound properly, in order to prevent all chance of secondary infection. To this end the corneal wound should be clean and quite free, and if the iris is adherent to it or to the wounded lens, an iridectomy is indicated with the removal of all suspected parts of the iris. If the wound is large and does not close well, it should be covered with a large conjunctival autoplasty.

If during these interventions crystalline masses present in the wound, they should be removed by gentle pressure or by means of Daviel's curet. It is, however, better to trust to good asepsis and complete occlusion of the wound than to run any risk by employing the least violence to the wounded eye. Nature often succeeds better than the surgeon, and one is astonished at the end of a few days

to observe the improvement by treatment of a simply conservative character. One can then choose quietly the opportune moment for intervention, which will be more precisely indicated, easier, and more useful.

The great danger in cases of traumatic cataract is secondary infection, which has already been studied at length when discussing injuries of the cornea. Other complications are studied in the discussion of senile cataract and of removal of the transparent lens in cases of high myopia.

Senile Cataract.

Nonsurgical Treatment.—Incomplete cataract is more frequent than is generally believed. Many persons have peripheral lental opacities which they fail to perceive until such time as one of the opacities advances into the pupillary area. On the other hand, when the crystalline opacities are central, nuclear cataract, anterior or posterior polar cataract, visual disturbances are immediately noticed.

The cause of cataract is still very obscure, although in certain cases great heat (glassworkers' cataract), diabetes, etc., have been blamed with good reason. As the result of numerous experiments upon animals, Roemer has been convinced that the peripheral lental disturbances result from cellular alterations produced by toxins either elaborated by the individual himself or coming from the outside. These cytotoxins damage the vitality and nutrition of the cells, the fibers of the crystalline lens. Starting from this view, Roemer has tried to furnish, as it were, the counter-proof by his experiences in treating 165 patients affected with senile cataract with an **extract of the crystalline lens** obtained from young and healthy mammals. The lental protoplasm of these animals, being identical with that of man, this substance is readily assimilated and might replace that which had become cata-

ractous. Of course it is not expected that all forms of cataract would be influenced by this organotherapy, but those which are characterized by cortical, subcapsular opacities have after several months of this treatment shown a constant and progressive improvement in sight. If these facts are confirmed by a larger number of observations a great step will have been taken in the prophylaxis of lental opacities and in the medical treatment of cataract.

If we observe closely the evolution of lental opacities, we are sometimes surprised to see that they may undergo spontaneous regression. Cases have even been published of the **spontaneous resorption of cataract.**[1] Such instances have been acclaimed by certain charlatans selling specific collyria supposed to cure cataract without operation. However, during the last few years reliable observers have noticed after treatment for a long time with collyria of potassium iodid either an arrest in the evolution of cataract or else manifest regression of the opacities with improvement of sight (Badal). Later, in place of contenting themselves with collyria or eye-baths, other surgeons have made subconjunctival injections of sodium chlorid (Darier) or of 1 per cent. potassium iodid (Verdereau), and the results have been better than with collyria.

Pflugk conceived the idea of controlling experimentally these facts by provoking in the rabbit naphthalin cataract, which he then treated by subconjunctival injections of 1 per cent. potassium iodid. Studying with the microscope the lesion produced by naphthalin, he found, first, a swelling of the lens; then the appearance of vacuoles in the protoplasm, and then in the nuclei; and, lastly, a detachment of the endothelium. Pflugk then studied the ways in which potassium iodid when injected beneath the conjunctiva gained entrance into the crystalline lens. He was able thus to confirm the conclusions reached by

[1] The editor has published a monograph on this subject in the Journal of the American Medical Association, October 18, 1902.

Deutschmann by showing that the penetration of the iodin took place especially by the anterior suture and by the posterior pole of the crystalline lens. With these two orders of facts known, Pflugk studied the action of subconjunctival injections of iodid upon the initial microscopic lesions of naphthalin cataract. Under the influence of the iodid, he found that 87 per cent. of the cases presented no aggravation, while 31 per cent. were much improved. In 37 per cent. of the cases an eye submitted to the action of the iodid had the naphthalinic lesions less marked that its congener which had not been treated. In 19 per cent. there was no difference; 12 per cent. showed an aggravation due to excess of the iodid employed. Applying, then, the same treatment to man, Pflugk reached the conviction that treatment by the iodid was to be recommended in every case in which the cataract was beginning and in those in which operation was absolutely contraindicated. He obtained twenty-nine very pronounced ameliorations, eighteen ameliorations, while in seven cases the condition remained without change. There was aggravation in one case associated with macular choroiditis.

The present-day **medicinal treatment of commencing cataract** may be formulated thus:

1. The instillation, as often as possible (six to eight times a day), of the following collyrium, which is quite painless:

Potassium iodid	0.20
Sodium iodid	0.20
Sterilized and distilled water	10.00

2. An electrolytic eye-bath with the following solution:

Potassium iodid	5
Distilled water	100

3. The eye-baths may be replaced by inunctions around the orbit with iodosol or iodized vasogene, the absorption of which is rapid.

4. Every week when the patient is seen for the purpose of controlling the treatment, an application of dionin should be made, so as to produce an abundant lymphatic inundation capable of stimulating the resorption of the opaque masses.

5. If the result is not sufficiently manifest, we inject beneath the conjunctiva, once a week, first a 1 per cent. solution and then a 2 per cent. solution of potassium iodid, which is well borne if one is careful to follow the technic already described. In the interval between successive injections, the instillations of potassium iodid, dionin, etc., should be continued.

6. When the organotherapy praised by Roemer has made its proofs and when its formula has been published by that author, we shall have a powerful weapon to add to those enumerated above. But for the moment the medical treatment of advanced cataract can scarcely be taken seriously.

The surgical treatment of cataract is now so certain, so little dangerous, and so free from pain that, whenever the cataract is almost "ripe," unless the patient refuses absolutely, appropriate operation should be performed.

Daviel endowed us with a perfect method of extraction, to which von Graefe added iridectomy, and, lastly, Pasteur and Lister showed us how to prevent infective complications, which have been reduced by asepsis from 10 per cent. at least to 1 per cent. To-day, thanks to serotherapy, we can prevent almost with certainty most of the late infections which are still liable to occur.

The technic of the operation is fully described in the volume on ophthalmic surgery, but many minor, though important, points may be discussed here.

1. **Should we operate upon a cataractous eye when the other eye is quite healthy without trace of even peripheral opacities?**

If the patient is habituated to his work, experiences no inconvenience, and is able to compensate the reduction

in his visual field by an appropriate inclination of his head, he is able very well to get on without operation. Moreover, extraction of cataract under these conditions does not offer great advantages from the functional point of view, since binocular vision is never possible after the operation. As the visual field is enlarged, the patient is able to perceive obstacles formerly hidden from him by his nose. That is, however, a very important point. Patients, as a rule, ask to be operated on because they desire to be freed from a disfiguring white blemish, and also because they fear, with reason, that they will be rendered completely blind if an accident happens to the sound eye.

An eye affected for long with cataract is likely to become divergent. Early extraction, it is true, prevents this deformity, but does not cause the squint, once established, to disappear. Operation undertaken in time even if it fail to give perfect binocular vision, yet gives a fusion of the images enough to prevent divergent strabismus.

2. **What plan should be adopted when one eye is completely cataractous and the other begins to be affected?** In this case the action of the surgeon must be quite otherwise. He should operate as quickly as possible on the more advanced cataract, so that while the second cataract evolves the eye which he has operated on may have time to become accustomed to the wearing of exactly correcting lenses. It takes more than three months for such an eye to appreciate distance and depth. While this process takes place by short stages, the other eye becomes "ripe" for operation.

3. **In cases of double and complete cataract, should both eyes be operated on at the same time?** The most elementary prudence returns to this question the answer No! It can be justifiable only in exceptional circumstances, as when the blind person can pay only a flying visit to the oculist. Both eyes may, then, be operated on the same day, for we are able nowadays to prevent almost to a certainty all infective complications, and even should

such occur, they can be cured in 80 per cent. of cases by paraspecific serotherapy.

4. **When is the most favorable moment for removing a cataract?**

Should we wait until such time as the sight of the eye is completely extinguished, as advised by some? When one eye is alone affected, complete maturity may be awaited —that is to say, until the central and peripheral masses have lost their transparency. On the other hand, when both eyes are already involved, the more advanced eye should be operated on as soon as the patient becomes unable to perceive with it the title of a paper or, perhaps, whenever the patient becomes absolutely unable to attend to his work.

In the case of central opacities, sight may be often much improved by dilating the pupil with atropin or by wearing very dark glasses. Under these circumstances, **preliminary iridectomy** is definitely indicated. This operation has the advantage of preserving to the patient, often for a lengthened period, sight sufficiently useful to retard extraction of the cataract. Moreover, by the performance of preliminary iridectomy extraction is rendered easier and much less dangerous, since the coloboma made in the iris allows the cataractous lens simpler and more complete exit. Preliminary iridectomy is equally indicated whenever we have reason to fear a difficult operation either by reason of the indocility of the patient or for fear of infective accidents among those suffering from general maladies, such as pronounced diabetes, albuminuria, etc. Another indication is furnished by cases in which the patients are compelled to go home after operation.

A patient who has been operated on for cataract with iridectomy may, an hour or so after, return to his home several kilometers distant, and come back for the eye to be dressed every day or every other day. Naturally, in cases in which patients can be admitted to hospital, this is more convenient both for doctor and patient; but many

persons who still retain the sight of one eye are only too happy to be able to return to their homes after operation. This plan of ambulatory operation, which has been adopted for more than twenty years upon about one-half of the patients operated upon by the author, has yielded results absolutely as good as those obtained when the patient was kept in the hospital or confined to his own house. This marks a very important progress from the point of view of public medical assistance, since we may now say that opthalmologic services need only one-half the beds they formerly required. On the other hand, the practitioner may now operate upon a great number of poor persons whom he was once obliged to send to hospital, not being in a position to care for them at his own expense. At the same time great care should be exercised when the operation must be performed without iridectomy. It is better to reserve these patients for hospital treatment, for the exertion of going away after removal of cataract may provoke a prolapse and hernia of the iris. Preliminary iridectomy renders ambulatory operations much easier and more certain. Extraction should never be made less than four weeks after iridectomy, and never until all traces of reaction have disappeared.

The Precautions that Should be Taken before Extraction of Cataract is Undertaken.—The first essential is to be quite certain that the operation will give a good result. We must assure ourselves that sight is impeded only by the obstacle opposed to the light rays by the opacity of the crystalline lens. This may be ascertained by moving in front of the affected eye either the light of candle or the reflection from the ophthalmoscopic mirror. Under these circumstances if the patient can tell the direction from which the light falls upon the eye—from below, from above, or from the side—we know that luminous perception and projection are good, and that the functions of the optic nerve and retina are consequently intact. On the contrary, if the patient cannot see the light when it falls from above or from the

side, there is strong reason for dreading a detachment of the retina below or on the opposite side. This diagnosis may be confirmed if the tension of the eyeball is low, since that nearly always accompanies detachment of the retina. Choroidal changes and disturbances in the vitreous humor are usually associated with a form of cataract which commences at the posterior pole. When the cataract is already far advanced, it is not possible to say where it commenced. In any case considerable reservations should be made in poor light-perception and obvious contraction of the luminous visual field, since in those circumstances atrophy of the optic nerve is to be feared. We must also beware of cataractous eyes which manifest divergent strabismus.

When we are assured that the eye is in condition for operation, we must also know whether the patient bears within himself the causes of infection.

If the urine is found to contain a large amount of sugar, the patient before operation should be placed under appropriate treatment. Those suffering from chronic eczema or from active rheumatism, in short all such maladies, should be operated on only after we have obtained a period of relative recovery.

Chronic blepharitis complicated with pronounced ectropion, purulent or granulous conjunctivitis, xerosis, or intense lacrimation are more or less temporary contraindications to the extraction of cataract. But in the course of several days we can, thanks to modern methods, place these patients in a sufficiently good condition to allow of their operation with a great chance of success. In such cases we must carry out an intensive and rapid cure of conjunctivitis, or remove the lacrimal sac when detersive injections and probing appear to be inadequate.

The night before the operation, the patient must take a bath and change all body-linen and clothes. By some a purgative is administered, and a "test-dressing" applied over the eye which is to be operated on. On the

next day, if the dressing should be soiled with pus, the operation is postponed. Those precautions are possibly a little exaggerated, especially when we are dealing with apparently healthy eyes. It is preferable to wash the face and the eyelids carefully, soaping minutely the cilia and the eyebrows. Epilation is not necessary, neither is it necessary to shave the eyebrows nor cut the eyelashes. The structures may, if necessary, be washed with benzine or simply with a soap which contains cyanid or mercury, 1:500. Excellent means of preparing the field of operation are to be found in savonnage with protargol and instillation of argyrol.

Thirty minutes before operation an aseptic solution of 3 per cent. cocain[1] is dropped into the eye, and the application is repeated every five minutes, the eye being covered in the intervals with a wool compress, so as to avoid the loss of epithelium often observed in a cocainized cornea. Five minutes before operation we proceed to the toilet of the eye. This is commenced by injecting through the lacrimal passages a syringeful of mercury cyanid solution, 1:1,000. The patient is then placed upon the operating-table, and the parts around the orbit and especially the eyebrows and eyelashes, are again soaped. The conjunctival sac should be simply washed and irrigated with warm, aseptic physiologic salt solution.

The exact method of operation matters little provided that it is executed under proper aseptic precautions. The surgeon and his assistants should wash their hands carefully with formolated or other antiseptic soft soap, and the operator should wear a gauze veil before his mouth. Instruments, sterilized at 140° C. in the autoclave, before operation should be placed in sterilized water under a pressure of 120 degrees.

It is important to make the **corneal incision** rather too large than too small. Daviel made his incision include

[1] To secure perfect asepsis, it is advisable to employ sterilized collyria put up in ampoules. This suggestion applies to the other solutions that may be needed, as atropin or eserin, as well as to cocain.

half of the cornea. As a rule, it suffices to include two-fifths of the cornea, the knife passing horizontally a little above the center of the pupil and emerging clearly and cleanly at the limit of the transparent cornea. Too much importance has been attached to the cutting of a conjunctival flap, the object of which is to protect the wound. The advantages of this flap are open to considerable discussion. A good and purely corneal incision, if it is well coapted, after perfect reduction of the iris, is closed in the course of twenty-five minutes, so that the anterior chamber retains the aqueous humor.

We must introduce into the eye the **minimum of instruments** compatible with the exigencies of a good operation—that is to say, knife, iris forceps, capsulotome, and spatula. Every instrument that has been introduced into the eye should be put aside, and if we are obliged to remove masses with the curet, there must be as many curets available as will enable us to employ a clean one on each occasion. Certain surgeons have pushed operative dexterity to such a point as to employ only a single instrument in the operation. The knife alone is used to incise the cornea and the capsule, to express the cataract from the eye, and to reduce the iris. The eye is simply fixed between the thumb and the index-finger of the left hand. Apart from some losses of vitreous humor, the results appear to be very good.

On the other hand, some operators have found it useful to add to the ordinary procedures corneal or conjunctival sutures. This is an absolutely useless complication if the operation is done with iridectomy, while in the contrary case it is not shown to have any great advantage. "Simple" extraction, as it is called, is followed by hernia of the iris in from 4 to 8 per cent. of the cases. The operation should be restricted to carefully selected patients; and in order to avoid prolapse of the iris care should be taken not to apply the dressing until the anterior chamber has been reformed, which usually occurs in twenty

to thirty minutes after the operation. If the wound be not coapted at the end of this interval, the cause should be sought with a binocular loupe and good lateral illumination, and one may then find that a shred of capsule or of conjunctiva is entangled in the lips of the wound, or that the iris is adherent to the incision, and that there is a prolapse of the iris. Before applying a dressing these complications must be remedied—first, by reducing capsular entanglements, and, second, by excising any iris which tends to prolapse.

A very important step in the operation is the expulsion of the cortical masses when these do not come away with the nucleus. In general, it is better to get rid of them by external manipulation of the eye, but if this fails, Daviel's curet may be introduced or irrigation of the chamber with physiologic solution may be carried out. The salt solution must be tepid and absolutely aseptic.

After the cortical masses have been extracted leaving the pupil black, the surgeon should devote all his attention to reducing the iris with the spatula, and to taking care that no conjunctival flap is caught up between the lips of the wound.

After-treatment.—Both eyes are covered with compresses, and the patient is allowed to lie down for twenty or thirty minutes, and a dressing is not applied until such time as the anterior chamber has been reformed. To the eyes of patients operated upon in hospital, a binocular bandage is applied. If the patient must return home, the eye which has been operated upon is covered with the classic bandage, while the eye that still retains sight should be covered by two or three turns of an independent bandage, so that in case of urgency the patient may raise the folds without running any risk of interfering with the dressing of the other eye.

As a rule, the dressing need not be changed for forty-eight hours, unless the patient has experienced some pain, in which case we must at once take steps to ascertain the

condition of the wound. When the dressing is changed, one or two drops of an aseptic solution of atropin are instilled, and the edge of the eyelids is carefully soaped with a wool tampon rubbed with cyanid of mercury soap. If there be some reaction and secretion, several drops of a 2 per cent. solution of collargol are put into the eye. Collargol is nonirritating, and, owing to its marked antiseptic properties, has a very evident preventive action as regards slightly infective processes. The dressing is completed by oiling the eyelids with collargol ointment, 15 per cent. When there is suspicion of affection of the lacrimal passages, the nasal canal must be irrigated at each dressing

For a week, the dressings must be changed daily or every second day. The eye is then left without a bandage for a part of the day, protected only by dark amber or yellow glasses, which have the advantage of attenuating the blue vision of which patients who have been operated upon for cataract complain.

Accidents During Operation. — The surgeon may by inattention introduce the knife with its back turned toward the place where he expects to make the incision. The instrument must be withdrawn, and if the anterior chamber is empty, the operation should not be undertaken until such time as the aqueous humor has resecreted.

At other times, the aqueous humor having escaped before the section of the cornea is completed, the iris falls in front of the cutting-edge of the instrument. Under such circumstances we should not hesitate in the operation. The section should be completed, and a flap of iris cut away, so that an iridectomy is performed, which, if necessary, may be then trimmed up. The piece of iris which has been excised will be expelled from the eye with the lens or during washing of the anterior chamber.

During performance of the iridectomy a movement of the patient may cause the tearing away of a flap of iris, sometimes of considerable size. The immediate re-

sult of this accident is usually more or less abundant hemorrhage. This operation should be completed as quickly as possible. If the bleeding is too violent, ergotin should be at once injected into the temple, and calcium chlorid be prescribed. On the following day two or three leeches are applied to the temple, so as to induce quick resorption of the effused blood.

Loss of vitreous should be extremely rare in the hands of a prudent operator. Sometimes a sudden contraction of the eyelids while the speculum is in place will cause simultaneous expulsion of the vitreous body and crystalline lens. When dealing with nervous subjects, who screw their eyelids together at the least touch, the speculum should be discarded, and the eyelids held apart by the fingers of an assistant or by means of Desmarres's retractors. In such patients, too, it is unwise to unduly prolong expulsion of the cortical remains.

The lens may be dislocated into the vitreous body while the section of the cornea is being made or, more often, during discission of the capsule. In such case the lens must never be left in the eye. An attempt must be made to extract it by means of Snellen's loop, and there is always a notable loss of vitreous humor when this is undertaken.

After marked loss of vitreous, the globe is sometimes so collapsed that the coaptation of the wound becomes extremely imperfect. Before employing sutures of the cornea, always very difficult to pass in a half-opened eye, we bring the lips of the wound together as well as possible, and the patient is left for an hour or two upon the bed, with a simple compress over the eye. At the end of this time we are sometimes surprised to find that the eye has largely recovered its volume, and that the wound is more or less closed. The parts are placed in the most favorable position, and an occlusive dressing, not compressing the eye, is applied.

Irregularly coapted wounds call for strict super-

vision, inasmuch as they become infected with great ease. We should be ready to inject 10 cm. of antidiphtheritic serum at the least alarm of infection.

Collapse of the cornea and of the eyeball may be observed in certain predisposed individuals, without the least loss of vitreous humor. As already recommended, we wait an hour or two before we apply a dressing, in order that we may supervise coaptation of the wound.

Hemorrhage beneath the conjunctiva may be produced either by the fixation forceps or by the knife while cutting a conjunctival flap. Like those seen in the anterior chamber, they are of no significance. In the rarer expulsive hemorrhages, which come on, as a rule, after section of the cornea or during performance of iridectomy, the lens presents through the lips of the wound and is expelled from the eye, and is soon followed by the vitreous body and sometimes by the choroid and the retina. These accidents are succeeded by the continued escape of blood, which even compression of the carotid may not arrest. Sight is irretrievably lost in these cases. In case of such fulminating hemorrhages, we apply a compressive bandage over a large packet of wool, and give at once an injection of morphin or, better, apomorphin, which brings about very pronounced peripheral anemia by the nausea provoked. At the same time we try an injection into the temple of ergotin and an intravenous injection of 10 to 20 c.c. of antidiphtheritic serum, which can be obtained much more readily than simple horse serum.

If the bleeding continues on the following day, we need not hesitate to practice compression or to perform ligature of the carotid or, better, to detach the external rectus and to pass a long curved pair of forcipressure forceps in such a way as to compress between its teeth all the vessels which supply the eye without fear of crushing completely the optic nerve. But the simplest plan, after all, is to remove the eyeball, the sight of which is lost, and then to compress or tie all bleeding vessels.

One of the most frequent and serious complications is **prolapse of the iris** following simple extraction of cataract. If the hernia is very small it may be left alone, but if, as is more often the case, the wound is kept half-open by a pad or iris, we should waste no time by adopting such measures as instillations of eserin, attempts at reduction, cauterization with the galvanocautery, etc., but should excise the prolapsed iris and cover the wound with a large flap of conjunctiva. We instill freely for half an hour the following collyrium:

Cocain hydrochlorid	0.20
Eserin salicylate	0.05
Adrenalin, 1 : 1,000	20 drops.
Sterilized water	4.00

We then inject beneath the conjunctiva, above the level of the hernia, a solution of 1 per cent. cocain, with the object of rendering insensitive all the conjunctival surface that will serve for the autoplasty. Ten minutes after the injection has been made, we carefully dissect up a conjunctival flap from the insertion of the external rectus to that of the internal rectus, passing well above the superior rectus. The flap thus well prepared, two sutures are passed through it, one internally and the other externally, and the sutures are put on one side while the hernia of the iris is cut away. In order to accomplish this, we commence by freeing the adhesions with capsule-forceps, provided with several teeth, and the prolapse is then excised as widely as possible by two or three strokes of the *ciseaux-pinces*. The conjunctival flap is next brought down to cover the wound, and, lastly, the knots are tied. Should the too tightly stretched conjunctiva cover the wound imperfectly, a liberating incision is made through the conjunctiva with scissors, naturally parallel to the corneal wound. By these means we secure a very well protected wound, as well as an iridectomy. At the least alarm of infection, we have recourse to serotherapy, which is always useful and

never does harm. The necessity for chloroform makes the operation more difficult.

Delay in the reestablishment of the anterior chamber is caused sometimes by a slight entanglement of the iris and more frequently by an adhesion between the whole surface of the iris and Descemet's membrane, abraded during discission. During the first two or three days atropin and eserin may be useful. But when the condition has lasted from two to four weeks, we must not hesitate to reopen the wound and to perform an iridectomy, or if iridectomy has already been made, to pass with great care a spatula between the iris and the posterior surface of the cornea, and then to apply a strong solution of atropin.

Glaucomatous complications are sometimes observed after extraction of cataract. When they are due to the immoderate use of atropin, it suffices to suppress all mydriatics and to make a few instillations of dionin and eserin. At other times the rise in tension is caused by an entanglement of the iris or capsule in the wound, and we must then divide the adhesion or enlarge the iridectomy on the affected side. It is good practice also to give one or two subconjunctival injections of sodium iodate (see Glaucoma).

Happily, **infective complications** are now very rare after cataract operation. Nevertheless, we still sometimes observe an unfortunate series of two or three consecutive infections. These are at first attributed to an endogenous infection, and, later, to the fluids or instruments employed. Indeed, the cause often escapes all our investigations, although it is none the less necessary to understand their course well, so that we may combat them the better. Infection may begin in the lips of the wound, which are hemmed, as it were, with a whitish-yellow swelling. The conjunctiva is hyperemic and chemotic. The edge of the upper eyelid is swollen. The patient complains of a sensation as of a foreign body, accompanied by pain in the eyebrow and orbit. If infection has not yet

reached the interior of the eye, the cornea is infiltrated only in the neighborhood of the wound, and, although the iris is contracted, the aqueous humor may still be clear.

If taken at this moment, the infection may be checked by carefully touching the lips of the wound with the galvano cautery, without it being necessary to pass the instrument into the anterior chamber. The treatment is completed by frequent instillations of collargol, 2 per cent., of argyrol, 20 per cent., or of mercury cyanid, 1:1,000, together with atropin and hot compresses.

We should not rest content in the belief that only local treatment is important, that only a treatment which stimulates the physiologic resistances of the organism is able to put an end to infective germs. On the contrary, we should know how to marshal wisely the different therapeutic acts by following attentively the clinical indications.

The immediate local destruction of the *foyer* of infection is of the highest importance when infection has commenced in the lips of the wound. But the case is different when infection has already penetrated into the anterior chamber or into the cavity of the lental capsule, or has begun in the iris or the media of the eye. We must not then hesitate to stimulate the general defensive functions of the body, and for that purpose no means is so efficacious as serotherapy, whereby the individual is supplied with a quantity of antibodies and antitoxins which allows him to offer an efficient resistance to the inroad of the infective germs. This serotherapy has the great advantage of being neither painful nor dangerous, and at the same time of permitting the use of all local remedies capable of aiding cure, such as the application of powdered dionin to the lips of the wound and the galvanocautery, which may be allowed to penetrate, if it is absolutely necessary, into the anterior chamber or even into the vitreous body. Evacuation of the aqueous humor provokes in the ciliary processes an afflux of blood and of antibodies, a process which can equally be set up by the introduction into the

anterior chamber of a rod of iodoform (Haab), or by injecting beneath the conjunctiva sodium chlorid or mercury cyanid or, better still, serum such as is employed in general serotherapy.

If these means have been systematically and progressively employed from the first, one is almost certain to be able to retain an eye with very good sight. On the contrary, if, for any reason, three or four days have been lost, although infection may still perhaps be stopped, so much damage has been done to the vitality of the eye that cure is obtained only with more or less complete atrophy of the eyeball.

The chief remote complication of the cataract operation is **secondary cataract,** constituted by the capsule and some adherent cortical remains. It must be cut or torn through (discission) or be extracted. Care should be taken not to perform discission too soon after the original operation. The eye should be free from the least trace of reaction. The most opportune moment, as a rule, is in the course of the fourth week.

Removal of the Crystalline Lens in High Myopia.—The results of this operation are often brilliant for the first few months. Then myopic complications continue their evolution, and we observe choroidal alterations, opacities of the vitreous body, and opacities of the capsule, which may require discission. Lastly, in 6 per cent. of the cases there is retinal detachment, while in the eye that has not been operated upon, 3 per cent. only are found. It is true that eyes upon which phakolysis is performed are always eyes already in an advanced state of myopic degeneration, and of two eyes the worse is selected for the operation. Hence, without rejecting an operation which is sometimes very useful and brilliant, we should be extremely reserved in the promises that we make to those concerned. We should even warn them that, in addition to its advantages, the operation has numerous and serious drawbacks, and that we operate only upon those who cannot wear any

optical correction and who are not able to exercise any profession. Many young persons, unfit for the simplest work, have, thanks to phakolysis, been able to conduct delicate professions for years.

As to the precise method of operation, among young subjects we give the preference to **repeated discissions** (one or two generally suffice), always keeping the pupil well dilated by atropin. The use of dionin every week helps resorption of the crystalline masses. Massage of the cornea is applied daily, since it prevents rise of tension, and places the crystalline remains in movement and in that way aids their resorption. If, despite all, the tension rises, we must, as quickly as possible, perform **paracentesis** and evacuate as much of the lental material as we can. If tension does not fall despite that, subconjunctival injections should be made of sodium iodate.

If no complication is present and the lens is completely softened, it may be removed by **extraction.** The capsule, however, must usually be treated by discission before clear vision is obtained.

In adults it is preferable to attempt to remove the lens *d'emblée*, and to perform discission some two months later. In any case operations should be as few in number as possible, since retinal detachment has been observed most frequently among patients who have been operated upon several times.

CHAPTER XXII.

THE TREATMENT OF GLAUCOMA.

Before we can acquaint ourselves with the action of the different means employed in the treatment of glaucoma we must first have an idea of the pathogeny of this formidable disease.

Pathogeny.—Glaucoma is an acute dropsy of the eye induced by hypersecretion or by retention. Von Graefe admitted an augmentation of secretion brought about by a special form of serous choroiditis. Donders attributed the hypersecretion to a vasomotor reflex through the ciliary nerves—a secretory neurosis, a theory of which A. Terson is a partisan at the present day: acute edema of the vitreous body. The neurosis of the great sympathetic, as formulated by Abadie, belongs to the same category. Stellwag explained the process as a simple augmentation of blood-pressure in the vessels of the eye. Kniess and Weber explain augmentation of intraocular tension by a venous stasis, whereby the ciliary processes swell to such a point as to push the iris against the cornea and to efface the iridocorneal angle, and in this way close the path of escape of the aqueous humor.

Zimmermann, of Goerlitz, has brought forward a theory of glaucoma, seductive and complete enough to explain satisfactorily the pathologic states observed in the various forms of the disease. He believes that glaucoma is due to a disturbance of equilibrium between the intravascular tension and the intraocular tension. For example, under the influence of a physical or moral shock, the heart may be affected to the point where it produces a sudden and more or less prolonged diminution of the intravascular tension. The ocular tension remaining the same,

the blood-stream carried into the retinal artery does not possess the force necessary to penetrate into the eye (it is then that with the ophthalmoscope the arterial pulse of glaucoma can be observed). There is retinal ischemia. The capillaries suffer in their nutrition and allow leukocytes and blood-serum to transude. In this way there comes about an edematous infiltration of the retina, choroid, and especially the ciliary processes, which in its turn augments the intraocular tension. The tumefaction of the ciliary processes should be the more marked since the long ciliary veins traverse the sclera very obliquely, and would be completely compressed and flattened by the excess of intraocular pressure. These ciliary processes, thus engorged, would lead to effacement of the sclerocorneal angle.

From the foregoing Zimmermann would explain a chronic, simple glaucoma as due, as it were, to chronic arterial hypotension, to an attack of hyperacute glaucoma, passing through all the intermediate stages according as the equilibrium between intraocular and intravascular pressure was able to reestablish itself, either more or less completely or not at all. In this theory the great sympathetic plays a part.

Before Zimmerman's hypothesis can be admitted, it must first be thoroughly tested by clinical experience and experimentation. He has already collected forty cases conclusive to his thinking, and when they have all been published, we shall be in a position to form a better judgment. Even should this theory be completely confirmed, it does not stand in the way of our looking upon iridectomy as the best treatment in established glaucoma. On the other hand, in a number of cases, especially slight ones, when taken at the beginning, we can intervene efficaciously by the adoption of a medical treatment which responds to the clinical indications.

Glaucoma may commence in a fulminating fashion. The patient then experiences violent pain in the

eye, temple, and head, which is sometimes so severe that vomiting may come on and consciousness may even be lost. Sight becomes cloudy and may sometimes even disappear completely. At other times the patient sees, as through a fog, lights surrounded by a rainbow. The eye is red, very painful, and yet we often observe a marked improvement in the cornea. At other times these symptoms come on slowly and progressively. These facts have led to the division into fulminating, acute, and chronic glaucoma. In the last-named we always find an excavation of the optic disc, and a contraction of the visual field, especially on the nasal side. In hyperacute glaucoma cloudiness of the cornea and media render examination of the fundus oculi impossible.

Since the remarkable work of von Graefe, **iridectomy** has been the best treatment in the great majority of cases of glaucoma. In 237 cases of glaucoma treated by iridectomy, Grosz obtained the following results:

In 29 cases of prodromal glaucoma, 96 per cent. of successes.
In 146 cases of established glaucoma, 87 per cent. of successes.
In 62 cases of simple glaucoma, 70 per cent. of successes.

It is often asked by the student, **is it necessary to operate in every case?** Is it not possible that slight attacks of glaucoma may disappear after two or three recurrences, either under the influence of some medicamentous treatment or spontaneously, the occasional cause having vanished and the constitutional state being predisposed to recovery? In a personal case of acute glaucoma, characterized by cloudy cornea, tension *plus* 2, inexplorable fundus oculi, and violent pain, iridectomy was proposed and accepted for the next day. In the interval a collyrium was prescribed of eserin, and 3 grms. of sodium salicylate were given during the day and 0.50 of quinin at night. On the following day the patient felt so much better that he did not return for operation, and when seen a week later, he had made a complete recovery. This

cure has maintained for many years. The youth of the patient, thirty-eight years, was doubtless an important factor in the cure.

In many other cases mild attacks of glaucoma disappear spontaneously, a fact which has led to the name of "prodromal glaucoma." These attacks, however, rarely become permanently arrested despite the careful use of miotics and general treatment, and in the end the patient finds himself compelled to submit to operation.

Rheumatism, gout, and sometimes syphilis have a very marked influence upon the pathogeny of glaucoma, as many observers have known for long. Czermak[1] has formulated a theory of glaucoma based upon a pathologic alteration in the vessels, consecutive to rheumatism, gout, atheroma, arteriosclerosis, senility, etc. Wagenmann[2] has obtained good results in certain forms of glaucoma by an appropriate antigouty treatment, with or without iridectomy. Walter[3] praises the antigouty properties of piperazin, both for preventing attacks of glaucoma and for sustaining the surgical treatment.

Many cases of glaucoma cured by the most various medicaments have been reported. The greatest number has been cured by the persistent and frequently repeated employment of miotics. Pilocarpin is better supported than eserin, which readily gives rise to ciliary pain, and this may sometimes be accompanied by a state of nausea so marked that the patients apply the medicament less regularly owing to their fear of its effects. In the medical treatment of glaucoma great advantage may be obtained from adrenalin, combined with such miotics as eserin and pilocarpin.

Domec[4] has published several cases of attacks of acute glaucoma speedily relieved by frequently repeated séances of massage.

[1] Czermak. *Prag. med. Woch.*, 1897.
[2] Wagenmann. *Archiv. für Ophtal.*, xliii.
[3] Walter. *La Clinique ophtalmologique*, 1898, No. 23.
[4] Domec. *La Clinique ophtalmologique*, 1899.

By their vasoconstrictor properties, several cardiac medicines have shown a favorable action in cases of glaucoma. In the first place, we must name quinin, then digitalis and the other cardiosthenics, as convallaria majalis, strophanthus hispidus, valerian, and potassium bromid.

Dionin may be most valuable in the treatment of glaucoma, as much by its powerful lymphagogic action as by its analgesic properties, which are sometimes so marked that we have seen the pain of an access of glaucoma disappear after a single application. In inflammation if one can eliminate completely the painful element, the phlegmasic process may resolve spontaneously (Spiess). This, unfortunately, is not always true as regards glaucoma. Nevertheless, dionin is very useful by allowing us to await the opportune moment for surgical interference.

Rarely cases of glaucoma have been reported in which the symptoms were rendered worse by eserin, adrenalin, and dionin. In the case of a woman, who was very hypermetropic and microphthalmic, after a couple of instillations of dionin, the pupil, contracted by eserin, dilated, tension rose, and sight diminished very notably (Senn).

Prodromal Glaucoma.—In such a case a patient seeks advice suffering from a slight attack of acute glaucoma. The aspect of the cornea is slightly dull, tension is augmented, the pupil is a little dilated, and the eye is more or less red. The visual field is sometimes contracted on the nasal side. There is moderate headache. The patient has never had a previous attack; he is obviously a rheumatic subject; and he attributes the attack to a chill. Under such circumstances, before performing iridectomy, we are justified in trying to calm pain by dionin, and then in prescribing a collyrium of eserin or pilocarpin at the same time that we administer 3 or 4 grms. of sodium salicylate or of aspirin in the day, and 0.30 or 0.50 of quinin, with a little valerian, at night.

The first instillations of a miotic should be made by the practitioner himself, and these should be preceded

by dionin, the effect of which will be the more active in proportion as it provokes a more violent reaction. The effect of miotics may be accelerated or strengthened by massage of the cornea, which favors elimination of the aqueous humor and notably diminishes the intra-ocular tension.

If considerable improvement is not observed after one or two days of this treatment, operation must be delayed no longer. The performance of iridectomy will have been rendered easier by the measures already enumerated. If the glaucomatous processes show the least tendency to increase under the means recommended, the patient must not be kept under close and continuous observation, and operation should not be postponed even to the following day. In the contrary event, it is possible to wait and to choose the moment most favorable for operative interference.

If the attack passes away completely, and if the patient is young, has a vascular system in good order, and lives near the ophthalmic surgeon, a fresh attack may be awaited before proceeding to operation, taking care that appropriate treatment is adopted, and that the patient lives in good surroundings and follows a careful régime. On the contrary, operation is preferable, even when the attack is over, when we have to deal with an aged subject with arteriosclerosis. The operation will not only be easier, but will also afford more chance of success.

Irritative or Inflammatory Glaucoma.—In these cases the eyeball is hard as a marble, the pupil is oval and dilated, and the iris is glued to the posterior surface of the cornea, which is itself insensitive. Iridectomy should be performed as promptly as possible, and under such conditions as will ensure a good operative result.

Many writers recommend an equatorial puncture as a preliminary step, in order to reduce the high tension and the so-called inflammatory phenomena. Iridectomy is performed several hours or some days later, and the

cornea is often then notably clearer, while the anterior chamber is sufficiently reformed to allow the keratotomy to be made in the usual way. Although equatorial or **posterior sclerotomy** is a very good operation, it is not entirely devoid of dangers. For example, it may set up a retinal or choroidal hemorrhage, which may seriously compromise the final result of the iridectomy. It is therefore, if possible, best dispensed with.

An attempt may be made to bring the diseased eye into a state more favorable for operation by trying at first to calm the pain by means of dionin, which may be prescribed, combined with miotics, as in the formula given below.

Dionin	0.20
Pilocarpin	0.15
Eserin salicylate	0.10
Sterilized distilled water	10.00

A drop of this solution is to be placed in the diseased eye at first every hour, and later every second hour.

Leeches at the temple and the administration of phenacetin and antipyrin second the effect of the dionin if the latter does not suffice to make pain cease. A very pronounced calmative effect may be obtained, also, by the injection of dionin (0.03) into the temple.

Massage, applied very lightly at first, and then with more and more energy, if well tolerated, sometimes brings about a notable diminution in tension and helps in re-establishing the anterior chamber. But massage is badly borne by a very painful eye. Sodium salicylate and quinin are of extreme value in certain cases, and when matters are urgent, they may be given by intravenous injection.

As soon as symptoms are relieved, that is, when the pupil is somewhat smaller and the anterior chamber somewhat deeper, we should wait no longer, but proceed at once to iridectomy.

Chloroform should be administered in most cases of hyperacute glaucoma, since we can rarely obtain by cocain an adequate degree of anesthesia in such an eye. In many cases, however, iridectomy must be undertaken without general narcosis, either by force of circumstance or by the express wish of the patients. In order to secure as profound a degree of anesthesia as possible, it is well to employ for the purpose adrenalin, combined with cocain and eserin, as in the following formula:

Cocain hydrochlorid	0.20
Holocain hydrochlorid	0.20
Eserin salicylate	0.05
Adrenalin, 1 : 1,000	30 drops.
Sterilized distilled water	4.00

One drop is placed into the eye every five minutes for the half-hour immediately preceding the operation.

The incision through the cornea is made either with a keratome or a Graefe's knife, according to the precise indications of each particular case. When the foregoing anesthetic drops have been applied, this step is relatively free from pain, although if the iris is touched by the point of the knife in passing the patient will experience a lively pain, or make a sudden movement, and a traumatic cataract may be caused. The greatest prudence is required for this operation. The cornea once incised, the iris forceps should not be introduced into the anterior chamber at once. It is better to first drop some of the anesthetic collyrium either on the gaping wound or to introduce one or two drops into the anterior chamber. This allows the patient to suffer with more patience the section of the iris, which is by far the most delicate and painful stage of this perilous operation. It is also the most critical point, since upon its correct performance will largely turn the final result. An imperfect section of the iris may be the cause of entanglements sometimes prejudical to cure. On the other hand, a wound of the crystalline lens will result

in a cataract, whereby the vision may be lost for some time. Great help is always given by a large injection of morphin or of dionin (0.04) administered an hour before operation.

Chronic Irritative Glaucoma.—In these cases we have to deal with a patient who has suffered at intervals from more or less acute and prolonged attacks of glaucoma. In him we find all the classic signs of chronic irritative glaucoma. Thus, he complains of seeing aureoles of color around flames, his sight is disturbed, and he sometimes experiences more or less headache. On perimetric examination, we find a marked contraction of the nasal field. The cornea, which is clear or almost clear, allows us to recognize that the optic disc is cupped. The eye is manifestly hard. In such a case we should not hesitate, but operate as speedily as possible, and the result is usually very good. After operation, sight returns almost to what it was before the last attack, and is sometimes actually improved.

Simple Chronic Glaucoma.—This is one of the forms of glaucoma which may be said to lack, as it were, all the cardinal symptoms of the disease. There is never the least corneal disturbance. The pupil is little or not at all dilated. The eye is not appreciably harder than normal. There is no pain. The patients, however, are often migrainous. Sight fails progressively. The field of vision becomes more and more contracted, although the nasal scotoma, almost pathognomonic of irritative glaucoma, is not always present. If it were not for the conservation of color perception, the visual field might be taken for that of optic atrophy. In fact, the optic nerve is atrophied and deeply excavated. von Graefe himself, in his earlier publications, separated this affection from glaucoma, and regarded it as an atrophy with excavation of the papilla. At a later period, however, he abandoned this conception, and conceded the undoubted existence of simple chronic glaucoma.

The characteristic of glaucoma lies in augmentation of the intraocular pressure, the anatomic stigma of which is to be found in excavation of the optic nerve. The fact that we are rarely able to demonstrate the increase in pressure in cases of simple chronic glaucoma is no proof that hypertony does not exist. It may be intermittent, manifesting itself only during the night, during efforts at accommodation, or during physical or psychic activity, and even then at very long intervals. But all these moments, added one to the other for years, suffice at length to produce excavation of the optic nerves. Among the different members of the same family we may meet with all forms of glaucoma, each having an individual evolution—an affair of temperament and of circumstances.

Iridectomy is still the best treatment that we are able to offer to these patients, who, unfortunately, often do not seek advice until the optic nerve is already profoundly atrophied. Iridectomy performed at the beginning still yields fair results, although much inferior to those obtained in the other forms of glaucoma. The failures, however, are many, and some reliable observers deny any curative action of iridectomy in cases of glaucomatous atrophy. Certainly, the question of surgical interference, in an affection of progressive course and almost fatal result, is extremely delicate, and so the surgeon should take all possible precautions and make all necessary reserves.

At the beginning, so long as the visual field is but little contracted, we may content ourselves with treatment by miotics. But if in spite of these means the field of vision continues to contract, iridectomy must be performed, at least when the scotoma has not reached the fixation-point. In the latter case the operation may enlarge the scotoma and suppress central vision, and it is better, therefore, to abstain from iridectomy. When both eyes are affected, it is wise always to operate first upon the worse eye, in order to test the effect of iridectomy.

When the pupil is somewhat dilated and there are temporary obscurations of vision and headache, we should operate.

It must not be forgotten that to tarry too long with miotics is to run the risk of operating too late, and that the various kinds of sclerotomy praised during the last few years possess but a passing and often illusory action. At the most, they should be employed to feel the way in view of an impending iridectomy, which is the only operation meriting our confidence, although unfortunately it too often fails.

Sympathectomy, which belongs rather to the domain of major than of ophthalmic surgery, is an operation which must still be much studied before it can be recommended to the practitioner. Nevertheless, it has already been useful in cases in which other means have failed.

Attempts have been made recently to secure a greater effect to iridectomy by practising at the same time the resection of a tongue of sclera (Lagrange). The future must show us whether this operation has really advantages over the classic iridectomy. Bettremieux has suggested an operation which seeks to thin the sclera at the level of Schlemm's canal, the object being to establish a path of filtration beneath the conjunctiva. By Heine an operation called **"cyclodialysis"** has been proposed. By its means a communication is established between the anterior chamber and the suprachoroidal space, without excising any iris.

In simple chronic glaucoma it becomes particularly necessary to understand how to administer **miotics** for years with persistence. By this means we may prolong for an almost indefinite time fairly useful sight. Since eserin in aqueous solutions speedily undergoes changes, it is advisable to recommend oily collyria:

Eserin[1] (pure)	0.10
Sterilized olive oil	10.00

[1] The eserin should be dissolved in a sufficient quantity of ether, then the oil is added, and the mixture well shaken. Lastly, the ether is evaporated by bringing the mixture to a temperature of 45° C. in a water-bath.

In order to avoid the somewhat painful spasm of the iris, set up in some patients by eserin, this drug should at first be prescribed in weak solution. Its employment should be alternated with that of pilocarpin. Dionin, adrenalin, and massage are valuable alternative treatments. General treatment, also, must never be neglected. In nervous subjects good results are given by quinin and valerian, and in those who suffer from arteriosclerosis, by iodids. Cardiac insufficiency should be combated by tincture of strophanthus or convallaria majalis.

Hydrophthalmus (Buphthalmus).—Infantile glaucoma leads to a very considerable distention of the eyeball in its entirety and particularly as regards the anterior chamber, which then becomes extremely deep. The pupil is dilated, the iris is glaucous, the cornea is bluish, as is also the sclerotic, which looks somewhat transparent. This form of glaucoma is likely often due to an insidious inflammation of the choroid, often intrauterine, congenital, and usually of syphilitic origin. The cases should be treated, as soon as possible, by means of hypodermic injection of mercurials, and by repeated instillations of strong solutions of pilocarpin:

Pilocarpin hydrochlorid..... 0.50
Sterilized water..... 10.00
One drop to be placed in the eye four or five times a day.

Sometimes iridectomy gives a good result, especially when combined with mercurial treatment continued for several years. The incision should be made well in the cornea with a knife, and the iridectomy should be very small. When grown, these children generally show the dental stigmata of hereditary syphilis (Hutchinson, Fournier, Darier).

Secondary Glaucoma.—In glaucoma secondary to grave iritis or iridocyclitis, brilliant results have been obtained by subconjunctival injections combined with para-

centesis of the cornea. The puncture, by evacuating the infective liquid contained in the anterior chamber and by reducing the intraocular pressure, places the eye in conditions more favorable to the effects of subconjunctival injections. The liquid injected then acts as an antiseptic, as a stimulant renovating the nutrition of the tissues, and, lastly, as a method of flushing out the eliminatory paths obstructed by inflammation exudations.

In iritis and glaucoma Schiele has recently recommended subconjunctival injections of sodium iodate, 1 : 1,000, for their resolutive and analgesic action. This method has yielded the author excellent results in all cases of secondary glaucoma:[1]

1. In secondary glaucoma due to swelling of the remains of a traumatic cataract, to rapid swelling of senile cataract, to discission of zonular cataract, or of the transparent crystalline lens in myopes, etc.

2. In secondary glaucoma due to endogenous or traumatic iridocyclitis.

3. In glaucoma coming on in eyes in which an iridectomy had been performed long before.

4. In cases of pupillary seclusion, etc.

Finally, in all cases of glaucoma secondary to any pathologic process whatever, the process may be controlled, and iridectomy may, if possible, be avoided by making two or three injections of sodium iodate, 1 : 1,000, using upon each occasion a syringeful of the liquid, the injection of which is almost painless. It goes without saying that the effect of the injection should be assisted by any treatment which is clinically indicated; as, for example, miotics, dionin, general measures, etc. Should iridectomy be necessary later, it will be performed under the best conditions.

That which has been called **"paradoxical glaucoma"** is produced by instillations of eserin, adrenalin, subconjunctival injection, and even after the performance of an

[1] Darier. *La Clinique ophtalomologique*, 1908.

iridectomy. In these cases we employ the reverse of the provocative cause: eserin = atropin; adrenalin = dionin; etc.

A phenomenon sometimes observed is called **"sympathetic glaucoma,"** *i.e.*, after iridectomy made on one eye, the other eye is seized on the day or two or three days after the first operation with an attack of acute glaucoma. Often, this eye has been until the attack absolutely healthy, but at other times it had suffered from several mild attacks of prodromal glaucoma.

In order to forestall this serious complication, it is always necessary when we operate upon the first eye to submit the second to the action of miotics, especially when premonitory signs have already declared themselves. By most authors this untoward influence of iridectomy is recognized, and all recommend that the eye should be operated upon as soon as possible. But often temporization, armed with the appropriate therapeutic measures, allows us to cure this attack of glaucoma and any that may follow, and thus obtain a definitive result, quite as good as that obtained in the eye subjected to iridectomy.

It is a question whether in these cases the iridectomy after having provoked a violent initial reaction, has then an inhibitory action which allows of cure of the second eye without it being necessary to proceed to iridectomy. Such question deserves careful study. It goes without saying that if serious attacks continue to appear, iridectomy must be performed.

The operation for glaucoma is one of the most beautiful discoveries of modern therapeutics. But it does not lack difficulties, and often its brilliant consequences leave something still to be desired.

Malignant glaucoma is the most serious form, leading progressively toward blindness, with or without operation. It even seems in these cases that iridectomy gives a fillip to the morbid process, thus provoking more or less rapid loss of vision, either with or without hemorrhages. When there is reason to dread a malignant glaucoma, the worse

eye should be operated upon first, for, in general, the affection is bilateral.

It is in such cases that preliminary sclerotomy may be most useful and even give precise indications; since if the operation (preferably the anterior sclerotomy of de Wecker) fails to give even momentary improvement, it is to be feared that iridectomy will not succeed. Sclerotomy usually, however, improves or arrests the process.

Sometimes an iridectomy performed with perfect operative result upon an eye almost completely lost produces a disastrous result upon the second eye by reason of an expulsive hemorrhage.

In a case of malignant glaucoma aggravated by iridectomy, good vision was retained for ten years by the use of sclerotic punctures some days after the iridectomy, until the tension fell to normal and the anterior chamber was reformed (Hegner). In another case in which, despite iridectomy, the first eye was completely lost, the second eye was subjected first to sclerotomy and then to iridectomy, and although the vision was lost, the eye remained hard. A subconjunctival injection of sodium iodate (0.001) brought about, at the end of five days, a cure which is still maintained (Darier). In cases of this kind also, a series of hypodermic injections of pilocarpin may be made (Gruening).

When there is reason to fear hemorrhage, either because retinal hemorrhages have been seen or because the first eye has already been lost in this way, the patient should be submitted to treatment by calcium chlorid in doses of 3 to 4 grms. a day, and by gelatin. A few moments before operation a 5 per cent. solution of gelatin is injected beneath the skin. Iridectomy in cases of acute glaucoma is certainly the most delicate operation in eye surgery, and many failures must be assigned to operations undertaken under bad conditions. In his enthusiasm for his beautiful operation, von Graefe wished that the technic of iridectomy might be taught to all

medical men, so that they might be able to operate in urgent cases even in the most distant countries. It is impossible to protest too strongly against this notion, for most of the discredit thrown upon iridectomy certainly arises from the fact that very often the operation is performed badly or too late. The practitioner should thoroughly understand that he should seek expert advice whenever he has to deal with a serious disease of the eye, and that he should limit himself to prescribing remedies which will allow him to await, with the least danger possible, the advice of the specialist.

After iridectomy, almost all the patients complain of dazzling in daylight or at certain moments of the day. This discomfort is not imputable to the iridectomy alone, but also to the glaucoma itself, owing to defects in the visual field and to rapid exhaustion of the retinal elements. In fact, it is often remarkable to hear how those who have been operated upon for glaucoma complain of seeing with great difficulty, with or without correcting glasses, when our means of investigation do not allow us to find any corresponding reduction of the visual acuity.

In brief, **the results of iridectomy** are not very brilliant except in cases of frank acute glaucoma, and then only when the attack is a first one and the operation is performed quite early. In such cases the patient usually experiences no disability after the operation, and the earlier iridectomy has been undertaken, the better is vision.

In glaucoma of subacute or slow evolution, diagnosis is often reached only when the visual field is already contracted and visual acuity notably lowered, and then operation is not decided upon until after many tergiversations complicated by consultations and different treatment, whereby valuable time is lost. The results are then the less favorable the longer we have waited. But there is no necessity to depart from this general rule, namely, *that every case of acute or subacute glaucoma should be*

operated upon as soon as diagnosis is clearly established. One should speak of subacute glaucoma rather than of chronic glaucoma, since this term lends itself to confusion with simple chronic glaucoma, as to the treatment of which by iridectomy opinions are still divided.

Iridectomy, in general, possesses no real efficacy except when the tension of the eyeball is manifestly raised. Finally, iridectomy gives good results in about 70 per cent. of the cases of acute or subacute glaucoma, while in chronic simple glaucoma the process is arrested scarcely in one-quarter of the cases, and often we observe if not an aggravation, at least a continuance in the reduction of sight, which almost always ends in blindness.

It will be seen, therefore, that the conduct of the most experienced specialist is extremely difficult when dealing with a case of glaucoma. Although he may expect and promise cure, he has always to dread unfortunate unexpected accidents. Moverover, we are not in a position to recognize surely those cases in which iridectomy, instead of leading to cure, may precipitate complete loss of sight.

Before closing this discussion, it should be recorded that attempts have been recently made to treat certain cases of glaucoma by **high-frequency currents** (Truc).

CHAPTER XXIII.

DISEASES OF THE VITREOUS BODY, CHOROID AND RETINA.

Primary affections of the vitreous body (**hyalitis**) are rare and little understood.

Physiologic **mouches volantes** are common, and their shadows thrown upon the retina often give rise to much warranted apprehension. They are generally the result of cellular débris floating in the liquid vitreous. Uncorrected ametropia, prolonged eyestrain, great fatigue, vigils, and long illnesses augment the number and the size of these bodies. Good hygiene and sleep constitute almost the sole treatment of these spots, which may never disappear completely. Quite another significance attaches to floating bodies, black or brown, in the vitreous, which result, as a rule, from choroidal or retinal hemorrhages.

Hemorrhages of the vitreous body may be:

1. Traumatic. These should be treated by leeches, rest, and pilocarpin, if there is increased tension.

2. Due to an alteration in the blood—the "recurrent hemorrhages of adolescents." We must then treat the anemia and intoxications which lie at the root of the mischief, and especially constipation. In addition to laxatives and enemata, it is advisable to prescribe quinin and quinquina. Ten pills daily of the following formula should be given:

Quinin sulphate	0.02
Extract of quinquina	0.30

Ten drops of perchlorid of iron two or three times a day, sulphuric lemonade, and a glass of wine every morning may have a very good effect (Abadie). These medicines

may be alternated with tincture of hamamelis Virginica (20 to 30 drops three times a day) and chlorid or, better, lactate of calcium (2 to 4 grms. a day). Kyrieleis has recently recommended repeated and abundant bleedings in cases of grave hemorrhage of the vitreous body. In a very serious case the carotid was tied by Mayweg with success.

It is possible that warmed horses' serum or the Roux serum administered by the mouth might modify the blood crasis and arrest hemorrhages.

3. Vitreous hemorrhages among aged persons are usually due to vascular alterations, such as syphilitic or tuberculous arteritis, perivasculitis, and especially arteriosclerosis.

Treatment is indicated by the etiology of the disease. By Nieden large doses of potassium iodid and of mercury biniodid are recommended. When the hemorrhages are old they may be treated by electrolysis (Abadie), and by subconjunctival injections of 1 per cent. calcium chlorid or of sterilized gelatin. If one cannot be certain as to the perfect sterilization of the gelatin, it is much better to give the product by the mouth. Roemer had hoped to be able to cause dissolution of hemorrhagic exudations into the vitreous by injecting hemolytic serum into the eye, but this hazardous intervention may provoke grave alterations in the retina and vitreous body (Elschnig). Even when used as a subconjunctival injection, hemolytic serum is not devoid of danger (Darier).

Pilocarpin as a valuable agent in the treatment of intraocular hemorrhage. Employed locally as a 3 per cent. collyrium it has the advantage of preventing glaucomatous accidents. Given hypodermically to a fasting patient on the morning of every second day in the dose of half a centigram, it aids in a remarkable way the resorption of intraocular hemorrhage. Tincture of jaborandi, in doses of twenty to thirty drops three times a day, may also be prescribed.

Lastly, it has quite recently been recognized that patients from whom the thyroid gland has been removed show hemorrhages of the **fundus oculi.** This observation has led Angelucci to prescribe powdered thyroid or thyroidin in intraocular hemorrhages. The dilaceration of very voluminous opacities has been advocated by Stedman Bull, and so have repeated punctures of the vitreous body.

Chronic hyalitis, characterized by the presence of numerous clouds and filaments floating in the vitreous humor, results, as a rule, from syphilitic chorioretinitis which is discussed elsewhere.

Synchysis of the vitreous body, due to the presence of cholesterin crystals, usually gives rise to no disturbance of sight, and calls for no treatment unless there are other organic lesions which require attention.[1]

Cysticercus of the vitreous body is so rare that many ophthalmic surgeons have never even seen a case. In general, surgical interference alone offers a chance of ridding the eye of the parasite—incision of the sclera and removal of the vesicle. Electrolysis may also lead to death of the parasite (Dor).

Vitreous infections, abscess of the vitreous body, panophthalmitis, have been studied when describing ocular traumatisms. When the vitreous is suppurating, the eye is fatally lost; but if the process is only beginning, there is a chance of stopping the morbid process by subconjunctival injections, serotherapy, or mercurial inunctions. Under these circumstances, also, the introduction into the eye of pencils of iodoform has been recommended by Haab, Intraocular injections of sublimate have been suggested by Abadie.

Diseases of the Choroid.

Despite fifty years of observation with so precise an instrument as the ophthalmoscope, the **pathogeny**

[1]Injections of pilocarpin, subconjunctival injections of dilute alcohol, repeated applications of dionin, mercurial treatment in cases of syphilis, etc.

of choroiditis is still ill-understood. Inflammations of the choroid may be classed into central, disseminated, areolar, atrophic, myopic, suppurative, etc. Inflammatory affections of the choroid may result from endogenous or exogenous infection, acute pyogenic infections, metastic infections, and slow infections (syphilitic and tuberculous choroiditis, etc.). Most frequently, the choroid is not the sole structure invaded by the morbid process: the ciliary body, the retina, and the vitreous humor are involved in pathologic disturbances of the choroid.

Until recently, there was practically no local treatment of alterations in the deeper membranes of the eye. The only indications were those furnished by the general affection to which the local lesion was etiologically connected. The remedies employed were all attended with the same indifferent result, so much so, indeed, that abstention became the rule with many practitioners. Alterant treatment alone, by mercurials and sudorifics, yielded some results and that not only in specific choroiditis, but also in the choroidal alterations which are so common in cases of myopia.

Rare, indeed, are cases of diseases of the choroid and retina in which we can speak of cure, for it is seldom that medical advice is sought until these affections have destroyed certain of the anatomic elements. An indelible cicatrix is the consequence. There are, however, many cases in which the disease may be controlled soon enough to retain good sight.

In **disease of the macula** it is most necessary to act with rapidity and intensity, and there is no better way of attaining these indications than by the employment of subconjunctival injections. In most cases results are appreciable from the first or the second injection, but in others a larger number of injections must be given. In macular choroiditis, when central vision is not irremediably destroyed, we can secure, if not normal sight, at least a considerable improvement in visual acuity, and that in a convincingly

short time. It goes without saying that such results can be obtained only when the pathologic processes have not so annihilated the structure as to prevent the possibility of visual function.

Local treatment is indicated in every acute case and in fresh recurrences. Even in cases of very long standing it should always be tried, since many observations prove that even apparently indelible lesions may now and then disappear (Darier).

Speaking generally, favorable results have been obtained in at least 25 per cent. of the cases of choroiditis treated by **subconjunctival injections,** either alone or combined with general treatment by hypodermic or intravenous injections (Darier). These figures may not appear to be very brilliant, but if we consider the gravity of the pathologic processes, and particularly the physiologic importance of the anatomic elements involved by the morbid processes,[1] and if we recall the results obtained by the primitive older methods, we are compelled to admit that local medication by means of subconjunctival injections deserves extended trial.

The action of subconjunctival injections upon diseases of the choroid is particularly remarkable. This fact led some authors to claim that injections have, as it were, an elective action upon the choroid. The explanation of this fact is furnished by the communication that exists between the lymphatic spaces of the choroid and the subconjunctival spaces, by the intermediation of the perivascular sheaths of the vasa vorticosa. In cases of recent and not too deep central choroiditis or chorioretinitis we may study almost mathematically the truly remarkable action of subconjunctival injections.

In all cases of recent choroidal alteration bearing upon the macula or its immediate neighborhood, local treatment is the first indicated, although obviously general measures must not be neglected. Although to obtain

[1] In central choroiditis the retina is invariably involved.

results it is not imperative to act at the very inception of the disease, yet treatment must be begun before the rods and cones have been completely destroyed by the morbid processes. We have seen cases of central choroiditis, taken for congenital alterations, notably improved at first by subcutaneous injections and afterward by subconjunctival injections (Darier). We have also seen disseminated chorioretinitis which had for long invaded the macula much benefited by subconjunctival injections, while general treatment had produced no effect or had ceased to act.

In **pigmentary choroiditis** the results obtained by local treatment are sometimes surprising, even in cases in which specific treatment was without effect. Burri, of Basle, has related cases of macular choroiditis in which favorable results followed the injection of saline. In a thesis published in 1896, Auguste Dufour has reported twenty-five cases of myopic choroiditis, of which twenty-one were treated with success by means of subconjunctival injection of sublimate. Pflüger, of Berne, has been more satisfied in diseases of the choroid with subconjunctival injections than with any other method of treatment.

Sourdille, of Nantes, has praised the good results obtained in myopic macular choroiditis, disseminated choroiditis, etc., from injections of iodo-ioduric injections. Four or five drops of the following solution are injected every other day beneath the bulbar conjunctiva:

Metallic iodin	0.01 to 0.02
Potassium iodid	1.0
Distilled water	30.0

The violent pain lasts for scarcely a quarter of an hour. Sodium iodate, iodin trichlorid, and many other preparations of iodin, however, are much less painful and give equally good results.

It is often impossible to tell, even after a most careful ophthalmoscopic examination, whether a macular lesion is or is not curable. But it may be said that if subcon-

junctival injections have not been tried we have no right to affirm that the lesion is irreparable.

It would be most interesting to decide as to the respective value of sublimate, saline, iodin, etc., but since this study has not been made, we must hold fast to the following formula, which combines the advantages of saline with the powerful resolutive properties of mercury:

Mercury cyanid	0.01
Sodium chlorid	1.0
Sterilized distilled water	50.0

The amount of the foregoing solution to be injected varies from one-quarter to one syringeful, and the best place to make the injection is the equator of the eye, as far as possible from the cornea, and by preference above and out. It is because they have not known how to proportion the doses to the intensity of the morbid process that negative observations have been reported by many authors.

In a recent communication based upon an experience of five years, Senn shows that we are now only beginning to properly appreciate the value of subconjunctival injections of mercury cyanid. He states that prior to the surgical treatment of high myopia, we must always, as a preliminary step, endeavor to improve central vision, which is usually much compromised by choroidal changes. In order to reach this end, no better means are known to Senn than subconjunctival injections of mercury cyanid, 1 : 5,000. He found that injections of sodium chlorid are not active enough or soon lose their efficiency in the treatment of macular choroiditis, myopic or otherwise. All his patients with high myopia are submitted to subconjunctival injections for a period of six weeks, after which the lenses are removed, either by extraction or discission. In this way Senn obtains infinitely superior results as regards the acuity of vision.

Suker has narrated two cases of choroiditis in which

great improvement followed the administration of thiosinamin in pills.

In **dionin** Wolffberg believes that we have a substitute for subconjunctival injections. The lymphagog action of dionin, however, energetic though it be, is too fleeting to give appreciable results in the treatment of choroiditis. Even in ocular diseases due to general affections, such as syphilis, tuberculosis, and rheumatism, local therapeutics is being more and more used.

It has been only of late that we have been able to determine the **tuberculous origin** of many cases of choroiditis the nature of which was unknown. The beautiful work of Sydney Stephenson and George Carpenter[1] has enlightened us upon this subject. It is to be hoped that in these forms of tuberculous choroiditis, subconjunctival injections of guaiacol alternated with those of sterilized air may give results more rapid and still more conclusive than those already obtained by mercurial injections. Areolar and disseminated choroiditis are much less obviously benefited by treatment when they show few central lesions (the only ones that manifestly impair sight). In these cases it is especially to general treatment that we must resort—inunctions or mercurial injections, thiosinamin, potassium iodid, etc.

Suppurative choroiditis, which is usually of a metastatic nature, demands general treatment by antiinfective serotherapy, and local treatment by subconjunctival injections of mercury, 1 : 1,000, hot compresses, intensive mercurial cures, and, finally, often enucleation.

Diseases of the Retina.

In the discussion of choroiditis it has been pointed out that as regards the choroid and the retina there may be a community of the morbid processes, and that we have, as a rule, chorioretinitis to deal with. However, by

[1] Stephenson and Carpenter. *Reports of the Society for the Study of Disease in Children*, Vol. I.

its peculiar vascular system (terminal arteries), the retina itself is exposed to the most serious circulatory disturbances.

Inadequate blood-supply causes sudden but passing disturbances, such as phosphenes, dazzlings, etc. The momentary arrest of the retinal circulation may entail amblyopia, which may go on to complete and definitive blindness. Finally, in embolism and thrombosis of the central artery, the loss of sight is generally irremedial.

Anemia of the retina may be observed in many different conditions. Spasm of the retinal arteries may be caused either by disturbed innervation or by the powerful vasoconstrictor action of certain drugs, as, for example, quinin in large doses, extract of male fern, etc. In these cases the anemia may persist to such a degree that it results in definitive blindness, with atrophy of the optic nerves. But more often cure, complete or relative, results, leaving, nevertheless, disturbances which are sometimes permanent, such as contraction of the visual field, marked pallor of the optic discs, and slenderness of the retinal arteries.

Arterial atheroma is also a cause of retinal anemia, but this form soon results in hemorrhages.

In certain sudden amblyopia resulting from abundant hemorrhage (epistaxis, hematemesis, metrorrhagia, bleedings, etc.) the abolition of sight is not invariably due to a sudden anemia of the retina. There is assuredly a lessened afflux of blood to the retina, but with the ophthalmoscope, it can be seen that the circulation of the fundus is normal. The pupillary reflexes are always present. The cause of the blindness, therefore, must be sought in the cerebral cortex.

The same may be said of **uremic amaurosis,** which is liable to come on suddenly in albuminuric subjects, and which leads to loss of the vision without ophthalmoscopic changes. The loss of sight may be transitory or the reverse, but generally there are several successive attacks. Uremic amaurosis is attributed to a toxemic action upon the cerebral centers, and, in fact, there are noticed at the same time as the blindness buzzings in the

ear, violent headaches, vomiting, muscular cramp, and, finally, loss of consciousness.

Embolism of the central artery of the retina allows one to study *de visu* with the ophthalmoscope all the phases of absolute anemia of the retina. When the patient presents himself on the same day that he has suffered sudden blindness of one eye, we may observe that the retinal arteries are empty of blood and small as threads, while the retinal veins are little contracted. The retina soon loses its transparency. It assumes a cloudy and infiltrated aspect. Around the macula it becomes milky-white, so that the macula itself, by contrast, appears as a spot of bright red color. At a later stage, retinal infiltration disappears. The retina becomes transparent and undergoes complete atrophy. When the central artery is the one obstructed, sight is always lost, but when merely a lateral branch has been involved, a corresponding scotoma persists in the field of vision.

The treatment of embolism of the retina offers very small chance of cure, for our efforts are generally without result. It is necessary to cause disappearance of the embolus which plugs the artery, and this, as a rule, is beyond our powers. At the most we may endeavor to mobilize the plug toward the periphery of the fundus, so that it may affect a less important vascular territory of the retina. With this end in view, **massage** of the eyeball has been recommended by Hirschberg, Mauthner, Perles, Fischer, Fejer, Hesse, and others; and in some cases the results have been very good. Puncture of the anterior chamber by sudden evacuation of the aqueous humor provokes a profound and sharp diminution of the intraocular pressure, and the blood then rushing in with greater force may push the embolus forward. Von Graefe also tried iridectomy. Instillations of dionin, and subconjunctival injections of saline, sodium nitrate, etc., have been equally recommended, but, after all, they are adjuvants of small importance.

We may also try an abundant intravenous injection of sodium iodate, 1 : 100, and at the same time a subconjunctival injection of the salt, 1 : 1,000. Simultaneously, massage of the globe or paracentesis of the anterior chamber may be practised.

But to be of any value, all these therapeutic measures must be employed during the first few days or hours, the reason being that atrophy of the retina is promptly produced, and then all efforts to recover the least sight are useless. It sometimes happens that blindness is not complete. In certain of these cases the macula may be supplied by a so-called "cilio-retinal" artery, which springs from the main trunk before the expansion of the central artery upon the retina. A more common explanation is that the embolus has been arrested *à cheval* at a bifurcation of the artery. The blood, therefore, continues to reach by means of this arteriole that part of the retina which lies between the optic disc and the macula. Many cases diagnosed as embolism are in reality thrombosis of the retinal arteries.

Thrombosis of the retinal veins is a very rare affection, and is equally as disastrous as embolism of the central artery. In all cases the first and most important indication is to practise local blood-letting. We attack the cause of the mischief when it is the outcome of the mechanical compression by a tumor of the orbit. The indication is then obvious, namely, to remove surgically the obstacle to the venous circulation. But in most cases thrombosis is due to a chronic alteration of the vessel walls in old persons suffering from atheroma or cardiac disease, and under these circumstances little may be expected from treatment.

Thrombosis may begin in the sinuses or deep veins, and then spread first to the orbit, and afterward to the eye. Death is the most frequent termination of these cases.

Hemorrhagic retinitis is a general name given to different forms of inflammation of the retina, which are

accompanied by numerous hemorrhages, indicative of an alteration in the retinal vessels. This type of retinitis often occurs as a forerunner of hemorrhagic glaucoma. The best way to hasten the resorption of the retinal hemorrhages is by the repeated application of leeches to the mastoid process. This local bleeding has a really favorable action. And as long as we have not found other means more scientific and certain in their action, it is our duty to call to our aid this old remedy, which, if it has no action upon the pathologic process itself, is certainly that which in the shortest time brings about a marked functional improvement, and often even an obvious resorption of the hemorrhage exudations. It is, however, very certain that the true therapeutic indications will be furnished to us by a deeper acquaintance with the pathology even of the hemorrhages.

The causes of retinal hemorrhages we know to be multiple. First, there may be a particular fragility of the vessel walls, sometimes congenital but more often due to atheroma, arterial sclerosis, such as is seen in aged persons. In such cases all treatment should be directed toward endowing the arteries with more elasticity, as by prescribing sodium iodid and injections of Truneseck's serum, and in proscribing the abuse of alcohol and, in general, all excesses, sudden emotions, and violent efforts. Care should be taken that the intestinal functions are regularly performed, and a watch should be kept on the state of the heart, lungs, and kidneys. The engorgement of the vessels as a consequence of disturbance, general or local, of the circulation predisposes also to hemorrhages (thrombosis of the central artery, emboli, etc.).

Retinal hemorrhages may also be caused by changes of a more or less profound character in the blood-state. To this order belong the hemorrhages we observe in cases of pernicious anemia, leukemia, purpura, scurvy, icterus, albuminuria, diabetes, malaria, etc.

Diseases of the retina are almost always complicated

with alterations of the choroid. Thus, syphilitic retinitis, one of the best known forms of retinitis, is almost invariably accompanied by choroidal lesions, opacities of the vitreous body, and iritis.

Specific chorioretinitis, by reason of the multiplicity of the tissues involved and by the tenacious and profound disturbance of vision which it produces, merits special therapeutic study.

In these cases we find vitreous opacities, usually of both eyes, and sometimes an isolated posterior synechia. It is difficult, as a rule, to examine the fundus of the eye properly with the ophthalmoscope unless the pupil has previously been dilated. We then find the optic disc dirty looking and badly defined, as if clouded in dust, the arteries are usually grayish, and small hemorrhages may sometimes be seen along their course. In some cases the macula is free from changes, but in others it is cloudy, infiltrated, and may present yellowish exudations and spots of blood. Toward the periphery of the fundus we often see pigmented areas which show that the choroid is involved. The prognosis is rendered worse by the condition of the vitreous humor, which is often filled with fine dust or with large black flakes.

The relapsing central retinitis of von Graefe is a neurochorioretinitis, and if it is not complicated with other lesions, it is perhaps the most easily cured, if treated properly. Energetic general treatment must be instituted at once: intravenous injections every day and orbital inunctions of mercury every night. As soon as it is evident that treatment is taking effect, it should be reinforced by a subconjunctival injection of mercury cyanid, 1 : 5,000, and this should be repeated two or three days later when chemosis has disappeared. The more rapid resorption of the liquid injected will be aided by leeches and dionin. In order to augment the effect of the injection, we apply an alcohol dressing or mercurial poultices. After thirty intravenous and about ten subconjunctival injections, a month's rest

is given to the patient, and several days of this period may be devoted to the use of potassium iodid and pilocarpin. During acute periods, absolute rest of the eye, and, after that, relative rest with dark glasses are indicated.

Treatment should be continued with energy for months or years. After the month's rest, intravenous injections are resumed, but are given only on every second day, and if the vessels are difficult to find, an injection of calomel or of gray oil is administered every week. In this way the treatment may be kept up for months.

In more advanced forms, with dust and flakes in the vitreous, we must act with even more energy for eight or ten months, the first and the second year, and not relinquish treatment except with the greatest prudence. The fatigue caused by so intensive a treatment must be offset by good food, hygiene, hydrotherapy, massage, life and sport in the fresh air, and seasons at various watering resorts.

Hemorrhagic retinitis is often seen in syphilitic subjects, frequently leading to **retinitis proliferans,** which, like all deep alterations of the vitreous body, is almost always incurable. Specific treatment should be instituted by subconjunctival injections of calcium chlorid, 1 per cent., and of gelatin-serum alternating with those of mercury cyanide, 1 : 5,000. Hemolytic serum has not yielded the results expected from it. By a fortunate chance, we sometimes observe a tear in the vascularized membrane, and the improvement in sight thereby produced may lead to the illusion of cure, but a relapse is seldom long in appearing.

Hemorrhagic retinitis in subjects suffering from arteriosclerosis manifests itself by small spots in and around the macula, often leading to indelible lesions, with central scotomata and considerable reduction in vision.

Good results are sometimes obtained by treatment of the arteriosclerosis, but only when the lesions are but slightly advanced. The use of sodium iodid and depletive

treatment with waters slightly purgative, such as those of Marienbad, are sometimes useful.

Atrophic macular retinitis is found among aged persons. There is seen in the macula a yellowish-white spot, which increases in size very slowly. A hemorrhagic sigillation sometimes betrays the origin of the lesions. We resort to stimulants, sodium iodid, and the treatment of arteriosclerosis by light nourishment, vegetarianism, and slightly alkaline waters, such as those of Vals, Vitel, and Evian.

Albuminuric retinitis carries not only a bad prognosis as regards vision, but also as regards life, inasmuch as the lesions indicate a profound alteration of the whole vascular system, and the great majority of patients die within a couple of years after the discovery of the retinal changes. The treatment must be that of nephritis. Local measures are not indicated unless there is hemorrhagic or exudative attacks, when leeches, cups, etc., may be of some service. Sudorifics, intestinal derivatives, and mustard foot-baths are indicated.

The functions of the skin especially must be cared for by dry rubbings and massage. In grave cases rest in bed is the best means of keeping the body at a warm and uniform temperature, which prevents congestive kidney attacks. The elimination of toxins by transpiration may be rendered more active by two sudations per week, obtained either by pilocarpin or dry heat. A useful derivation may be obtained by the administration of a drastic purgative once a week.

Naturally, before all treatment we must endeavor to suppress any still active causes of the disease, such as alcohol, lead, and different infections. A very rigid régime should be instituted: at first a diet exclusively of milk, then enlarged by the addition of toast and white meat; no wine or alcohol and very little tea or coffee, light exercise not carried to the point of fatigue. These measures have no action upon the star-like figure of the macula so characteristic of albuminuric retinitis, but they have a

marked effect upon edematous exudations of the papilla and the retina.

When retinitis appears during pregnancy, gravidic retinitis, it may be necessary to induce premature labor.

Tessier, of Lyons, has recently succeeded in considerably improving albuminurics by the injection of 15 to 20 c.c. of serum obtained from the renal vein of animals after that vessel had first been ligatured. The antibodies secreted by the veins, thus rendered hyperemic by stasis, act upon the abundant toxins circulating in patients with nephritis.

Diabetic retinitis carries almost the same therapeutic considerations, although its prognosis is not so grave as that of albuminuric retinitis. The régime should not be absolute, and potatoes and toast may be allowed from time to time. The mineral courses at Vichy, Carlsbad, etc., should be followed, without excess, however. The administration of antipyrin, opiates, and alkalines should alternate with periods of strict régime. These methods do not act against established lesions, but they prevent new attacks, which should themselves be treated by derivatives and depletives, as leeches, cups, etc.

Hemorrhages may also be caused by diabetes insipidus, phosphaturia, azotinuria, etc.

Leukemic retinitis is of bad prognosis, since apparent cure is speedily followed by relapse. During recent times the use of X-rays has acted favorably in these cases. Perhaps by combining them with treatment by arsenic, sulphur, serotherapy, colloidal metals, etc., even more favorable results will be attained.

Malaria, grave icterus, extended burns of the skin, intoxications by phosphorus, lead, carbonic oxid, and naphthalin provoke retinitis, characterized by hemorrhages and exudations. The general treatment is indicated by the cause of the disease.

Septic metastatic retinitis is of the same order and has the same indications as metastatic choroiditis.

Pigmentary retinitis constitutes a well-characterized morbid entity as much by its symptomatology (hemeralopia, concentric contraction of the visual field) as by its peculiar ophthalmoscopic stigmata (dull and atrophic aspect of the papilla, considerable reduction in the caliber of the vessels, and pigmentary spots of the fundus having the appearance of bone corpuscles). It is caused by progressive degeneration of the retina, with migration of pigment from the pigmentary epithelium. The degeneration commences at the periphery, at the end of the smallest retinal arterioles, which explains the reduction of the field of vision.

Retinitis pigmentosa is usually an hereditary and familial malady. Consanguinity has been noted in the parents of the affected patients, and the retinal affection often occurs along with other congenital anomalies, such as deafness, idiocy, hare-lip, polydactylitis, posterior polar cataract, etc.

There are certain forms of retinitis pigmentosa called **"retinitis pigmentosa sine pigmento,"** because they present the clinical picture of the disease, but without deposits of pigment. From the therapeutic standpoint, there is little to do in so characteristic a congenital affection. Nevertheless, some forms of retinitis with gross deposits of pigment having been much improved by the hypodermic or intravenous injection of mercury cyanid, this treatment has been employed in several cases of retinitis pigmentosa. The results thereby obtained have been sufficiently favorable to warrant the trial of this treatment. Improvement also has been known to follow subconjunctival injections of sodium chlorid or cyanid. Retinal opotherapy, as by Doyne's "optocine" or Dor's ciliary extract, has still uncertain indications. Up-to-date retinitis pigmentosa has been really improved only by long-continued mercurial treatment, intravenous or subcutaneous injections given two or three times a week for years. Occasional injections of pilocarpin, and strychnin associated with the constant current, may be recommended with advantage.

Retinal Phototraumatism.

The increasingly general employment of electric currents of high voltage during the last few years has provoked ocular disturbances of various kinds. For example, conjunctivitis and irritations of the eye have been observed as the result of the electric light. Symptoms of retinitis also have followed the prolonged fixation the eyes on an intense light. **Viewing the sun** during eclipses, without protection of the eyes by very dark glasses, has produced retinal dazzling, which has been succeeded by a persistent central scotoma.

Retinal electrocution is caused by retinal concussion as the result of the passage of a short circuit through the upper part of the body and the head. There results not only dazzling by the light produced by the current, but also a sideration of the whole central nervous system. Consciousness may or may not be lost, according to the intensity of the current and the part of the body affected. In every case patients complain at first of the more or less complete loss of vision, with intense photophobia, generally accompanied by very pronounced blepharospasm and by headache, which is rendered worse by light. At this stage photophobia is so marked that for the first few days it becomes impossible to examine the fundus of the eye or to study the reaction of the pupils. The least ray of light, and particularly the electric light, sets up spasmodic contractions of the eyelids, as well as very violent pain in the eyes and head. It may happen that for several days patients are unable to open their eyes in the light, and when they can do so they say that they cannot see clearly. At this moment the exact determination of the visual acuity is very difficult if not actually impossible not only on account of the photophobia, but also on account of retinal exhaustion, the effect of which is to render characters, read at first, speedily indistinct or to disappear altogether. The field of vision also is difficult to take, the patient

becoming exhausted very quickly. In all cases in which it could be mapped out with some approach to accuracy, a very marked concentric contraction for white has been found, while colors were so imperfectly recognized that they could not be registered on the perimeter. As a rule, the pupillary reaction is normal, and the pupil of medium size. Apart from a certain degree of retinal and papillary hyperemia, examination of the fundus of the eye has shown no changes.

It most not be forgotten that simulation may play a part in the disturbances complained of by the injured, who know very well that we can control only with difficulty their statements, especially when they complain that the sight of both eyes is reduced. Employés are likely to discuss among themselves points that are likely to lead the physician astray in order to obtain as high an indemnity as possible. They may add to the visual disturbances, the neuropathic disturbances which depend upon hystero-traumatism. It will be apparent, therefore, that the rôle of the practitioner is very difficult in cases of retinal electrocution. He is anxious to make a report that will satisfy both science and his own conscience, and at the same time endeavor to cure an obscure disease, for the annals of medicine so far contain few cases of this altogether modern affection.

In addition to the phenomena enumerated above, the development of a cataract, commencing a few days after the accident and which may become complete in six weeks, has been noted by Bistis, Terrien, Desbrieres, and Bargy.

The treatment of retinal electrocution demands, in the first place, absolute rest, cold compresses, and hot and prolonged baths. As soon as the patient can bear a little light, he must wear very dark yellow protectors, provided with black silk all around the frames (motor spectacles). The photophobia may be rapidly reduced by the administration of potassium bromid (2 grms. a day), quinin (0.10 five or six times a day), and valerian. Collyria of

cocain, dionin, and adrenalin yield only temporary results. A more profound and durable effect, however, is produced by oily collyria of cocain and, better, of acoin. Headache is calmed by antipyrin, and when the effect of this remedy has been exhausted, by phenacetin, given according to the formula already mentioned, by pyramidon, etc.

A method of treatment which has several times yielded results, paradoxical through it may appear, is that by electricity. The positive pole of a very weak (1 to 2 milliamperes) constant current is applied to the eyes, the negative pole being placed on some indifferent part of the body. These applications act not only by the calmative effect of the position of pole, but also by allowing the exercise of suggestion, the importance of which should not be overlooked in an affection of an essentially nervous type and one so frequently complicated with hysterotraumatism.

The application, prolonged for several hours, of radium by means of radioactive plaques of 1,000 units gives very good results, calming headache and reducing photophobia (Darier).

Commotion retinæ, as the result of violent contusions of the eye without appreciable lesions, is not well-established. At least, when we observe a cloudy disturbance at the macula, we should look for the cause of the disturbance of sight in a distention of the suspensory ligament of the crystalline lens, which sets up a traumatic myopia. By placing before the injured eye concave glasses vision may be brought from 1/10 to 1/2 or 1. This traumatic myopia should be treated by repeated instillations of eserin or pilocarpin, electricity, and by very light massage.

Injuries of the retina by light, as by fixation of the sun, or by prolonged exposure to light rich in ultraviolet rays, are characterized by central or paracentral scotomata, particularly marked as regards colors. Time alone brings about an attenuation of the disorder. Nevertheless, it is well to try applications of dionin, massage, electricity, and injections of strychnin and pilocarpin into the temple.

Detachment of the Retina.

This may be divided into medical and surgical. To the first category belong the compressive bandage, rest in bed, diaphoresis, derivation, local, blood-letting, and instillations of such remeies as dionin, eserin, pilocarpin, and potassium iodid. All these measures may be combined with those belonging to the second category, which include subconjunctival injections, discission of the detached retina (von Graefe), simple scleral puncture (Ware, Sichel, Wolfe, Parinaud, etc.), aspiration or drainage of the subretinal fluid (Galezowski, de Wecker), iridectomy (Dransart, Bettremieux, Boucheron, Galezowski) irritating injections, such as those of iodin (Schöler, Abadie), ignipuncture (de Wecker, Dor, Chevallereau), electrolysis (Abadie, Terson, Darier, etc.), and discission of the vitreous bands followed by injection of rabbits' vitreous (Deutschmann). Despite this array of the most varied measures, lasting cures of detachment of the retina are very rare. Abstention has thus become the rule with very many ophthalmic surgeons. Among 422 cases of detachment Uhthoff could treat only eighty-five, of which eighteen recovered without treatment, ten under medical and eight under surgical treatment. Among 351 instances of cure collected from the literature, cure was spontaneous in 31 per cent., resulted from medical treatment in 45 per cent,. and from operation in 24 per cent. Those statistics do not convey any great encouragement to the partisans of surgical interference.

At the time of his first publications upon the subconjunctival injection of sublimate, the author had occasion to treat a few cases of detachment of the retina, in which he tried, but without much conviction, the value of the new therapeutic method. The first case was in a man of about fifty, who was very myopic, and who in 1892 complained of a marked disturbance in the sight of his only remaining eye, the other having been lost twelve years before from

detachment of the retina. Sight was considerably reduced. A scotoma, very clearly limited to the upper part of the visual field, corresponded to a slight but evident detachment in the lower equatorial region of the fundus. The optic disc was surrounded by a zone of myopic choroidal atrophy, and the whole of the fundus of the eye was traversed by a line of choroiditis. It was these choroidal alterations that led one to think that subconjunctival injections of sublimate might exert a salutary effect upon the retinal detachment itself. This supposition was confirmed by the results, for the patient was cured of the detachment. Since 1892 the patient has returned every two or three months for a subconjunctival injection, which, he says, restores the powers of his eye and reduces the *mouches volantes*. The detachment has never been reproduced.

Two other cases of the same kind have not been published. Formerly, we treated detachment by the intraocular injection of tincture of iodin and by electrolytic puncture. To-day on all sides we read of cure by the subconjunctival injection of sodium chlorid, sodium sulphate, gelatin, etc. In any event, if such treatment is no improvement, it is quite harmless, and, thanks to acoin, almost painless.

Subconjunctival injections in the treatment of detachment of the retina have been repeatedly taken up and abandoned. De Wecker, who formerly made injections of saline water, turned to injections of gelatin, etc., after having given up puncture, drainage, etc.

In a very interesting thesis published under the direction of Professor Mellinger, of Basle, by Staerkele, the following conclusions, based upon twenty-three cases, were reached:

1. That subconjunctival injections of sodium chlorid are without danger and are almost painless. They hasten considerably the resorption of intraocular pathologic products.

2. This resolutive action is the greater the stronger the concentration of the solution of sodium chloride.

3. In detachments of the retina these injections lead to a prolonged amelioration and, in some cases, to permanent cure.

4. Subconjunctival injections of saline improve, above all, partial detachments of recent date, while they act with greater difficulty upon total and long standing detachments.

Cases of cure, or of more or less marked improvement, by the injection of 2 to 4 per cent. solutions of sodium chlorid have also been reported by Mazzoli, Vinselmann, Haitz, Senn, and others.

Dor, Bourgeois, and Jocqs have advised the use of strong and even saturated solutions, so as to provoke by exosmosis the resorption of the subretinal fluid. It may appear very difficult to understand how a saline solution, even a saturated one, can exercise an osmotic action through so dense a membrane as the sclera. But the clinical fact is evident, even if the theoretic explanation is not easy to furnish.

Deutschmann, in many consecutive works based upon numerous cases, praises the freeing of the fibrous tracts which provoke the skrinking of the vitreous body, which is, according to Leber's theory, the true cause of detachment of the retina. He introduces a narrow blade, with double cutting edges, at one of the edges of the detachment, traverses the retina and the vitreous body, and makes the counterpuncture at the other edge of the detachment. Then, in order to give new vitality to the altered vitreous, he employs intraocular injections of a solution of the vitreous body of the rabbit. This is a treatment logical, but also daring. Leber's very interesting theory is not true in every case, for in young subjects the vitreous body is but little altered, although more fluid than in the normal state.

Following somewhat the same ideas, the author has

carried out the following operation upon eyes affected with old detachments. By means of a grooved needle of platinum-iridium there was made a puncture at the level of the detachment, and the subretinal liquid was aspirated. Then, without withdrawing the needle, the instrument was pushed more deeply into the vitreous body beyond the detached retina. By means of another syringe, filled with physiologic serum at a temperature of 32° C., brought into connection with the needle belonging to the first syringe, there was injected the liquid into the vitreous body until the eye had assumed an almost normal consistence. The needle was then withdrawn until nothing beyond its point remained in the wound. Then, placing the platinum needle in connection with the positive pole of a pile prepared for that purpose, a current of from 4 to 5 milliamperes was allowed to pass for a period of three minutes. On the following days, subconjunctival injections were made at intervals of two or three days for three or four weeks.

That is a rational method of treatment, but, like Deutschmann's, it has the drawback of being too complicated, and the results have not been more brilliant than with much more simple procedures. The method, nevertheless, may perhaps succeed where other methods have failed.

During recent years Abadie has used electrolysis in many cases of retinal detachment with good results. Professor Terson, of Toulouse, has reported many cases of detached retina cured by electrolysis, and, more recently, Maraval, of Oran, has published the results of his practice, from which he concludes:

1. Electrolysis gives in recent cases of detachment of the retina a real and constant amelioration, and sometimes brings about complete cure.

2. Its application is free from danger, and the nutrition of the eye is rather favorably influenced by a current of 5 milliamperes.

3. Electrolysis may be repeated several times at a few days' interval without inconvenience.

For electrolysis it is important to employ only blades of gold or rather of iridium-platinum, for steel is corroded by the powerful chemical action of the current, so that when we withdraw the knife, it is often notched, comes out with difficulty, and in doing so, may tear vessels, thus leading to loss of the eye by intraocular hemorrhage.

To the foregoing methods of treatment we should add simple punctures, which, in the hands of many authors, have given good results. The cautery has been equally praised. It may be used in conjunction with other means.

The application of leeches to the temple renders service in certain special indications. Sweatings, induced by sodium salicylate and especially by pilocarpin, may be valuable adjuvants.

One of the most important factors in the cure of retinal detachment, however, is certainly prolonged dorsal decubitus, although to keep in bed for two, three, or even six months persons who enjoy good general health is to apply a most irksome remedy. However, experience has shown that to allow the patients to get up before a month is to commit a great imprudence.

The simplest and, in general, the most benign of the retinal detachments is assuredly that which is caused by a **contusion of the eyeball.** It is not necessary that the traumatism should be violent enough to give rise to multiple and profound lesions, large ruptures of the choroid with abundant hemorrhages into the vitreous body, luxation of the lens, and tears of the iris, with or without ruptures of the sclera. But there are cases in which a more or less violent shock sustained by an eye previously healthy and not strongly myopic has provoked detachment of the retina without any complications other than an insignificant subretinal hemorrhage.

Under these conditions, if the patient presents himself within a short time of the accident, cure may be obtained

by some days' rest in bed with a simple compressive bandage. If there is retinal hemorrhage, the application of from three to six leeches is advisable. If the retina has not become reattached at the end of five or six days, subconjunctival injections of sodium chlorid should be made, employing a syringeful of the 2 to 4 per cent. solution, or, if necessary, of a 10 or even 20 per cent. solution. Few cases will resist this treatment if it is carried out seriously, and particularly if the dorsal decubitus is well observed from the beginning.

There are cases of traumatic detachment which, owing to the negligence of the patients, pass into the chronic state. Under these circumstances more energetic measures, described in the discussion of grave myopic detachments, should be employed.

There are many circumstances which may render grave the prognosis of retinal detachment. In the first place, there is the age and the patient's state of health; then the pathologic antecedents of the eye itself, which may have been affected with iritis, iridocyclitis, etc., or may have simply been very strongly myopic with advanced choroidal lesions. Finally, the detachment may be so old that retina and choroid have suffered such alterations that it becomes difficult to attain even a relative cure.

Some authors go so far as to say that they have never seen a case of retinal detachment absolutely cured. It is evident that so serious a lesion as retinal detachment cannot be cured without leaving its traces. At the same time traumatic detachments may be cured with *restitutio ad integrum.*

In **myopic detachment** the retina may become reapplied completely and vision may become as good as or even better than it was before, although the visual field sometimes shows scotomata which correspond to the part formerly detached. Sometimes, indeed, these scotomata may be as large as they were before the reattachment, especially as regards colors. It is evident that this can be called a relative cure only. Although instances of com-

plete cure of myopic detachments are very rare, yet they assuredly do occur.

Among traumatic detachments we should place those which follow an abundant loss of vitreous during the course of an operation for cataract. In these cases prognosis must be extremely reserved.

There are detachments which must be looked upon as secondary to intraocular pathologic alterations. In cases of tumor of the choroid in which the diagnosis is sometimes very difficult at the beginning, valuable indications may be given by transillumination. As to treatment, should mercurials and large doses of iodids remain without effect, we must without hesitation enucleate the eye.

Detachment may be consecutive to spontaneous choroidal hemorrhage. In this case we must try to bring about resorption of the effused blood as quickly as possible. When the hemorrhage is recent, leeches are indicated; puncture may at the commencement set up a new hemorrhage. Resorption of the exudation may he hastened by massage and the subconjunctival injection of sodium chlorid.

Exudative choroiditis, if it be abundant, may also produce detachment of the retina, the treatment of which will be indicated by the nature and the cause of the exudation. Brilliant results may be often obtained, in cases in which syphilis exists, by the inunction of mercury or its administration by intravenous and subconjunctival injection. Even in the absence of syphilis, we have seen cases rapidly cured by subconjunctival injections of mercury cyanid. Thus, in a young soldier affected with detachment reaching to the macula, due to exudation choroiditis, the author succeeded in causing the detachment to disappear completely and in bringing about normal visual acuity, although a scotoma persisted for a longer time.

Detachments consecutive to chronic iridochoroiditis

have a very bad prognosis, since all the tissues of the eye are in state of trophic decay which allows of little hope. However, there are some cases of this kind in which feeble vision has been retained for years, thanks to prolonged treatment by hypodermic or intravenous injections of mercury cyanid.

Lastly, certain forms of atrophic choroiditis, especially when they are widely spread, may have as a consequence detachment of the retina. Cases of this category, if they do not supervene in myopes, are those in which the best results will be obtained by subconjunctival injections of mercury.

The gravest form of all is what may be called the "idiopathic" detachment, which is met with so often in high myopia. It is easy to understand that even relative cure is difficult to obtain under these conditions; still we should seek by all means in our power to obtain, if not a cure, at least an arrest of the malady.

The following is a summary of the treatment to be adopted in the different types of retinal detachment:

1. **Moderate Detachments.**—A myope of more than 6 D. or 7 D., with a partial detachment, a quarter or a third of the retina being involved, the condition having existed only for a few days. The first duty is to prescribe the dorsal decubitus, to apply a compressive bandage to the eyes, and to practise one or more subconjunctival injections of sodium chlorid. The following is the formula which gives the best results:

Sodium chlorid	1.0
Cocain or acoin	0.10
Dionin	0.20
Sterilized distilled water	10.0

Of this liquid first a half and then a full syringe of 1 c.c. is injected well behind the eyeball, and when pain is violent, four leeches are applied in the neighborhood of the ear, and, if necessary, morphin is injected at night. Every two or three days moderate sweating is produced

by the injection of about 0.01 of pilocarpin. Vomiting must be avoided.

If at the end of several days the retina is well reattached, we allow the patient to leave his bed toward the end of the month, at first for an hour and then for two hours a day, keeping the ocular fundus and especially the visual field for blue under observation.[1]

The subconjunctival injections should be continued during all this period of observation. Once a week an injection is made of mercury cyanid, 1 : 5,000, since the salts of mercury have manifestly a salutary action upon myopic changes in the choroid, which are generally the cause of the detachment.

Leeches, wet cups, and cauterization of the sclera are valuable adjuvants capable of rendering real service, especially when the injections have been painful and have induced a somewhat lively reaction. After each injection the eye should be covered with a compressive bandage, atropin having first been instilled several times, for the iris should be watched very attentively. The smallest synechia indicates too violent a reaction. Under these circumstances the subconjunctival injections should be made at longer intervals. The first injections should be made at intervals of three or four days, but if the retina becomes reattached after the initial injection, a second is not practised in the absence of indication. We must content ourselves with instillations of dionin, sweatings, and a compressive bandage. If, on the contrary, after two or three injections there is no improvement, or if detachment follows an immediate reattachment, precious time must not be lost in vain attempts. More energetic measures must be immediately adopted.

2. **Grave Detachments.**—In these cases the indications are clear enough: a more or less abundant and altered liquid

[1] The visual field for white may show no defect in very slight detachments, while a scotoma for blue gives exactly the limits of the detached parts of the retina (Darier).

has been effused between retina and choroid; this liquid does not become resorbed under the influence of saline injections, and an issue must be given to it by puncture.

Simple **puncture** under many circumstances has yielded good results, although to avoid too rapid a renewal of the evacuated fluid, it should be combined with a strong subconjunctival injection, which may perhaps prevent a fresh subretinal effusion. **Electrolytic puncture** has the advantage over simple puncture that after the evacuation of the subretinal fluid, the electric current, passing between choroid and retina, may set up an adhesive inflammation, capable in some cases of keeping the retina fastened to the wall of the eye. The eye having been well anesthetized with cocain and rendered aseptic, the patient is placed horizontally in his bed. A constant current of nine small Gaiffe elements is arranged, with rheostat and galvanometer, upon a firm table placed in a convenient position. The platinum-iridium blade, with the double cutting edge, recommended by Abadie, is connected with the positive pole of the battery, the negative pole of which is applied to the patient's arm. The eye being luxated as strongly as possible with fixation-forceps, so as to expose that part of the sclera which corresponds to the detachment, the blade is introduced as far back as possible (to avoid the ciliary processes) and perpendicularly to the equator of of the globe, since hemorrhages are more readily caused by transverse incisions. The blade is allowed to penetrate for 2 or 3 mm., and then by giving a turn to the instrument, the subretinal fluid is allowed to escape. The current is then passed very slowly and progressively, so as to cause no shocks, and when it has reached 4 or 5 milliamperes, it is allowed to act for two or three minutes. During the last minute the needle is withdrawn very slowly in such a way that at the moment of exit the fine point remains no longer than an instant in contact with the wound. The current is reduced *decrescendo* parallel with the extraction of the needle. The electrolysis finished, a

subconjunctival injection is made behind the globe a centimeter farther away than the puncture.

Lastly, a third method of giving issue to the subretinal fluid is to transfix the detachment through and through by means of a Graefe knife, making the puncture and the counterpuncture through the edges of the detachment. The knife is held horizontally, the cutting edge being kept away from the ciliary processes as much as possible. There is no need, as recommended by Deutschmann, to interfere with the vitreous body. These punctures are much less painful than electrolysis, and they present two incisions, each of which may furnish a point of adhesion for the retina. They may without difficulty be repeated every fortnight by changing the place of the puncture and the counterpuncture.

In some cases reattachment may be partial only. Fresh punctures must then be made, although these should not be undertaken until the inflammatory phenomena have disappeared. Cure may be sometimes completed by the cautery, leeches, and the sweating induced by pilocarpin, alternated with subconjunctival injections.

Finally, if after a month or six weeks of vain effort the detachment always reproduces itself, we may try the intravitreous injections already spoken of.

Unhappily, a large number of cases of chronic retinal detachment resist all treatment, and end in complete disorganization of the eyeball. A cataract first forms, and then the globe becomes more or less atrophic. Under these circumstances all interference is contraindicated, unless there are special indications, such as dislocation of the cataractous lens or inflammatory glaucomatous accidents.

In a case of retinal detachment produced by a cysticercus complete cure was obtained by L. Dor by electrolysis of the cystic pouch.

CHAPTER XXIV.

DISEASES OF THE OPTIC NERVE.

Retrobulbar neuritis and specific neuritis or papillitis are practically the only diseases of the optic nerve amenable to ordinary treatment. When the trunk of the optic nerve has been seriously affected, it is rarely that it can be cured with *restitutio ad integrum.* Even certain cases of retrobulbar neuritis often terminate in partial atrophy of the optic nerve despite all treatment.

The therapeutic indications must be guided by the **pathogeny** of the affection regarded in the light afforded by the discoveries of modern medicine. The pathogeny of neuritis of the optic trunk is still far from being very clear. In the majority of cases the neuritis is of infective or toxic origin; but it may also be the result of injury.

We should consider in the class of retrobulbar neuritis all the series of toxic amblyopias, all cases in which a pathologic alteration of the axial fibers of the optic nerve has produced more or less marked atrophy of the nerve fibers going to the macula. As regards the papilla, there may be no inflammatory phenomena whatever, and in certain cases it becomes difficult or impossible to recognize partial pallor, along with atrophic excavation of the optic nerve. The primordial symptom is the presence of a more or less absolute central scotoma, with relative integrity of the peripheral field of vision. As a rule, the amblyopia is bilateral. In some rare cases, nevertheless, one eye may be first affected. It is even possible that one eye may alone be involved, if treatment has succeeded in removing the cause.

Theoretically, the limits of retrobulbar neuritis are well marked; but, practically, many cases present peculiarities

which render their classification a matter of difficulty. Abortive forms are as common as typical forms. In the present day retrobulbar neuritis has become a morbid entity by its cardinal symptom, the central scotoma.

Von Graefe was the first to suggest that a disease of the optic nerve may develop behind the eyeball and seriously affect sight without betraying itself by ophthalmoscopic changes. Leber studied retrobulbar neuritis in more detail, insisting upon the absence of intraocular lesions and upon the fact that only intoxications could cause the affection. He laid emphasis upon the importance of heredity, and created a particular type based upon numerous cases —hereditary retrobulbar neuritis.

To Samelsohn, however, belongs the credit of having furnished the irrefutable anatomic proof of the pathologic process and its localization. He found that the chief focus of the inflammatory lesion lay at the level of the optic foramen, in the osseous canal, and in the axis itself of the optic nerve—central, partial interstitial neuritis, with multiplication of nuclei. The lesion diminishes gradually the farther we go, up or down, from the principal focus, and before long nothing is found beyond atrophy of the nerve fibers. These fibers, which occupy the axis of the optic nerve at its entrance into the orbit, end by occupying the external sector of the optic nerve, in order to reach the macula. The atrophy of these macular fibers, which have become external at the level of the papilla, explains the temporal atrophic excavation which is almost always observed after retrobulbar neuritis.

In explaining the genesis of this pathologic process, there is a natural inquiry as to why the axial fibers of the optic nerve suffer more than those which lie in immediate contact with the sheath and are more exposed to lesions of the neighboring structures. *A priori*, inflammation of the sheath should affect particularly the underlying fibers. In certain cases this is true. But inflammation of the

sheath or the bony canal may also cause compression of all the optic tube, in which event the part which will suffer the most will be that which receives with the greatest difficulty its blood and nutritive supply. That will be the center, since at this level, before the penetration of the central vessels, the smallest capillaries are those which nourish the axial portion of the nerve. It is therefore at this spot that there will be produced at first a trophic disturbance and then one of an inflammatory nature.

As **etiologic factors** of retrobulbar neuritis, we have, first, all the inflammatory lesions of the bone, the periosteum or of the sheath at the level of the optic foramen, whether they be due to injury, chill, syphilis, tuberculosis, or a neighboring lesion (sinusitis, etc.). Then there is the whole series of chronic intoxications by chemical agents, such as alcohol, tobacco, lead, etc. In this class of cases it is particularly the center of the optic nerve that suffers the most. This is undoubtedly attributable to the same reason that the axial fibers are the least rich in vessels, and that this part of the optic nerve is least resistant to toxic influences. According to Nuel's view, toxic retrobulbar neuritis is secondary to an alteration in the retinal elements themselves. The fact is true as regards animals intoxicated by quinin (Drault).

It is important not to lose sight of the fact that all the pathologic processes may evolve without betraying themselves by any ophthalmoscopic signs, even although the central amblyopia is already definitive and irremediable, for it is not until much later that partial atrophy and temporal excavation of the papilla are manifested. It is not so much the extent as the intensity of the scotoma that renders prognosis the more serious. The gravest event is the persistence of an absolute scotoma.

Traumatic retrobulbar neuritis is more frequent than generally believed, and it would be no difficult task to quote many cases which for the most part have rapidly yielded to local injections. An injury of the eyebrow may provoke

disturbances of sight, ranging from a transitory amblyopia to complete or partial atrophy of the optic nerve.[1] If there is a fracture at the level of the optic foramen, the optic nerve may be completely crushed, with absolute loss of the sight of that eye, and with consecutive atrophy, which does not show itself until a couple of months after the accident, the papilla always receiving its habitual blood-supply, since the lesion has occurred above the point of penetration of the central artery. In this case all treatment is in vain.

A better prognosis may be expected in simple contusions, with or without hemorrhage, but always with anatomic lesions at the level of the optic foramen (infiltration and compression of the less vascularized axial fibers). In these cases we must act with quickness and energy. We understand the evolution of the pathologic process and how to estimate its extent and intensity by functional examination; but its duration is still without proper explanation.

The therapeutic indications, however, are clear. There exists lymphatic and leukocytic infiltration. The deep injection of a resolutive and hemolytic fluid will provoke the rapid resorption of the exudations and even of the effusions of blood. A few leeches also will bring about a salutary decongestion. The therapeutic indications will be completed by periorbital mercurial inunctions. By these means, many partial atrophies may be avoided, and numerous cases have been rapidly cured by this treatment.

Retrobulbar neuritis from cold, taken at the beginning, can usually be influenced favorably and even cured by local blood-letting, potassium iodid, and local mercurial inunctions. Rapid and brilliant results can

[1] These amblyopias are most frequently characterized by a very marked central scotoma, without any ophthalmoscopic signs. The optic nerve may simply have been compressed by *contrecoup*, and then the axial fibers, which go to the macula, will suffer most. If the bruising has been violent, atrophy of the macular bundle may be the result.

also be obtained from intensive retrobulbar injections. The same treatment is applicable to neuritis of syphilitic, tuberculous, infective, or other origin.

In toxic retrobulbar neuritis, as from tobacco, alcohol, and various medicamentous agents, when the cause is ascertained soon enough, before atrophy has had time to develop, removal of the cause alone is sufficient.

The form of retrobulbar neuritis so well described by Leber has the gravest prognosis of all forms of the disease. Nevertheless, even in these cases, treatment must be followed with tenacity for months, since improvement has taken place in cases believed to be hopeless, and blindness never becomes complete.

A certain number of cases of amblyopia consecutive to lactation have been reported supervening toward the seventh week after labor. The presence of an absolute central scotoma has never been noted. On the other hand, the enfeeblement of sight could always be accounted for by the very marked intraocular optic neuritis found with the ophthalmoscope. Cure has been almost always relative, and accompanied by slight atrophy of the optic nerve. The neuritis which may be observed during pregnancy runs almost the same course, although it often ends in complete atrophy if delivery is too long delayed.

From the numerous cases observed, the following **conclusions** may be drawn:

1. Subconjunctival injections have a powerful action upon neuritis of infective origin.

2. The opportune moment for therapeutic interference is at the very beginning, or at the time when the pathologic process begins to regress.

For purpose of illustration we may suppose that the two eyes of the same patient have been treated at altogether different periods. The left eye, already in the way of atrophy, or, rather, of regression of the inflammatory process, improves rapidly, while the right eye, in full evolution with obvious optic neuritis, shows at first no

response to treatment. It is necessary to wait for about fifteen days, when injections will quickly lead to cure.

During the period of evolution of retrobulbar neuritis, therapeutic action is scarcely appreciable, while at the very beginning and during the period of regression it is shown in a remarkable way. This is almost the same in all morbid processes. It becomes a simple question of therapeutic opportunism, with which every clinical observer is endowed by experience. At the commencement many maladies may be aborted; during the period of activity it is better to wait, and not to take the offensive until the disease has reached the end of its evolution.

Apart from Leber's disease and alcohol and tobacco amblyopia, we may claim that in acute retrobulbar neuritis, due to infection or to chill, or to lesions of neighboring parts, as sinusitis or periostitis of the optic foramen, the therapeutic influence of subconjunctival injections is powerful and undoubted when the method is properly understood and applied before the central fibers have suffered complete atrophy.

Local treatment should not interfere with general treatment by mercurial inunction, which formerly represented the only efficacious way of dealing with these cases. Accessory measures that may be employed with advantage include injections of strychnin and the application of the constant current. Elimination of toxins and stimulation of the tone of iris and ciliary processes may be brought about by pilocarpin.

However precarious our means of action in diseases of the optic nerve may appear to be, it is sometimes possible either to prevent the morbid process at its beginning or to hasten its resolution at its decline, and thus to arrive at cure, complete or relative, as the case may be. Such results have been obtained especially in cases due to traumatism, infection, or chill. Unfortunately, these cures are exceptional. Despite all our efforts, more frequently we see the neuritis follow its course and terminate in a

smaller or greater loss of the visual field (central scotoma or peripheral scotoma).

This result really does not come about because we are completely disarmed against a morbid process that evolves in the depths of the tissues, and because it would be difficult to apply our remedies in such a way as to act at so great a distance. It is rather that, being acquainted too imperfectly with the pathogeny and the evolution of the changes which are proceeding in the optic nerve itself, we do not understand how to interfere. It is not unlikely, also, that we believe too implicitly in the fatal issue of the affection, and that the wish to cure (which makes the force of all true therapeusis) is not the goal of our ambition. The propitious moment must be grasped, and advantage must be taken of the slightest occasion offered by nature for felicitous intervention. Clinical experience will furnish the basis of therapeutic opportunism. The most powerful and specific medicine, if not applied at the right moment, sometimes fails not only to cure but even does positive harm. In a case of infective bilateral retrobulbar neuritis, the first eye, which seemed to be on the way to atrophy, and which was certainly most gravely compromised, was improved with remarkable rapidity, since it was in the stage of regression of the morbid process. On the contrary, the other eye, which was in full pathologic efflorescence, was scarcely influenced by the same treatment. It was necessary to wait for almost a month before resuming the subconjunctival injections, which then had a prompt effect, with resultant vision of 2/3 and 1, although with restriction of the visual field.

The same proofs have been furnished in regard to central choroidoretinitis and myopic choroiditis, which, after several injections, first of sodium chlorid and then of mercury cyanid, improved so much that in a few weeks reading had become possible, which had not been the case for a considerable time before. In a case which became worse despite treatment, the injections were replaced for

several days by leeches. The injections were then resumed, and leeches were applied after each injection. The result soon showed that we had been right in temporizing in order to place the patient under conditions favorable to an opportune therapeutic effect.

In speaking of iritis and interstitial keratitis, it has already been noted that the therapeutic results obtained by the most active means have been denied by some and affirmed by others. This is due to the fact that the different observations were not under equally favorable conditions, although all the patients were treated for the same disease by the same means.

Neuritis of the optic foramen generally produces only a slightly marked effect upon the optic disc. Papillitis, or intraocular optic neuritis, is rarely a local malady. It is usually the outcome of a deeper affection.

Syphilis and the infective maladies, the toxemias connected with disturbances of nutrition, as diabetes, albuminuria, grave anemia, and the intoxications, as saturnism, usually give rise to simultaneous alterations in the retina, the choroid, and the papilla. Heredity (Leber) appears to be a cause of certain cases of neuritis, and in these cases our therapeutic resources have little if any effect.

It is really only in diseases of the orbit and of the neighboring cavities (tumors or inflammations) that we can regard optic neuritis, which is then generally unilateral, as a local affection. The treatment of these cases is to suppress as promptly as possible the cause of the trouble. In cases of sinusitis, the pus must be evacuated surgically at the earliest moment possible. If operable, a tumor of the orbit must be ablated.

Periostitis of the walls of the orbit should be treated in accordance with its etiology. But in cases which are not too far advanced, the promptest and surest results can be obtained by the frequent application of mercurial poultices. The heat and the local action of the mercurial

lanolin sometimes causes resolution of the inflammatory process. It is advisable to keep up this local action by the administration of potassium iodid in ascending doses of from 2 to 10 grms. a day, although the best way to cause regression of the inflammatory process which compresses the optic nerve is to inject mercury cyanid into the depths of the orbit.

One of the most interesting forms of disease is furnished by **specific neuritis,** both on account of its great gravity and its etiology. It is usual to regard all maladies clearly connected with syphilis as having a relatively favorable prognosis. This view, unhappily, is not borne out in cases of serious specific neuritis. There are, however, cases of papillitis, consecutive to syphilitic lesions of the orbit, which yield very quickly to the classic treatment. It is not this purely neuritic form that we have in mind, but cases in which the retina, the choroid, the optic nerve, and even the vitreous body are all involved by the morbid process (see Retinitis and Choroiditis). Here we have not a veritable neuritis, for the disc is hardly tumefied, and the veins are scarcely more turgescent and tortuous than normal. That which strikes one especially is the dirty aspect of the papilla, which is really due to a slight infiltration of the retina and to the fact that the layers of the vitreous body lying in immediate contact with the papilla have lost their normal transparency and present a characteristic state of cloudiness. This specific neuritis is often only the first stage in multiple alterations of the retina and the choroid. In fact, later we see patches of chorioretinitis appear either at the periphery or near the macula and the papilla, with all the complications proper to those affections, such as choroidal atrophy, hemorrhages, and retinitis proliferans.

In face of so redoubtable an affection, therapeutic interference should be most rapid and most energetic, but it should also be kept up for a very long time, of course with intervals of rest. The patient should be at once

submitted to an intensive mercurial treatment. This should be carried out by means of periorbital mercurial inunctions and by the daily intravenous injection of increasing doses of mercury cyanid (0.008 to 0.02 and even 0.03), while not forgetting the first sign of intestinal reaction. Attention should be paid to the condition of the mouth. Every other day the patient should be asked whether he has suffered from diarrhea or colic. When this reaction has been produced, the doses are reduced, to return again to the maximum dose, in order to avoid medicamentous tolerance which is speedily produced both as regards the patient and the treponema, to which time must not be given to recover its virulence. If intolerance is set up, general treatment may be replaced by subconjunctival injections. Arsacetin may also be tried, or pilocarpin, combined with iodic preparation, may be given.

Thanks to the foregoing procedures, it is possible to obtain cures believed at first to be impossible, when we were limited to the classic antisyphilitic therapeutics.

Mercurial inunctions quickly entail stomatitis of so intense a nature that we are compelled to suspend the mercurial treatment before it has had time to end completely the morbid process. In specific neuritis durable cure cannot be obtained by several days' treatment. We must beware of the rapid improvements observed sometimes after an intensive cure. If the patient stops treatment too soon, he will speedily suffer from manifestations more serious than the first, and to combat which our efforts are singularly impotent.

When thirty to forty intensive intravenous injections have been made, the method of treatment must be changed for a time. For example, we may make a series of subconjunctival injections (two or three a week) alternatively upon each eye. The patient is then given about a fortnight's rest, after which we recommend a cure by pilocarpin or a sojourn of three weeks at a hot sulphur bath resort.

In specific neuritis the results given by potassium iodid, administered by itself, are something more than mediocre. At the same time, the use of this drug may be of service, possibly because it compels the patient to look after himself and allows rest from mercurial treatment.

By the adoption of these different means we can keep the patient under continuous observation for almost four months, and then even if he seems to be cured (which is seldom the case) we still find the papilla dirty and observe small choroidal changes in the fundus oculi, which show that the morbid process is not extinct, and furnish us with a formal indication for a fresh series of injections.

By watching the patient with the greatest care, the practitioner can readily find indications for continuing the treatment, naturally with periods of rest, for two or three years or longer. We count ourselves fortunate if we succeed by our most faithful efforts in retaining useful vision in patients affected with specific neuritis, the cure of this disease should always be looked upon as an important victory.

Frequently, no improvement comes about during the first intravenous injections. They must not, however, be discontinued upon that account. An amelioration may show itself a fortnight or a month afterward. Under such circumstances we might be tempted to attribute the improvement to the medicament given last, when it was really due to the tardy effect of the one first employed.

True optic neuritis, stasis neuritis, called by the Germans "Stanungspapille," is always indicative of an **intracranial malady,** accompanied by increase of the intracranial pressure, such as cerebral or cerebellar tumor, meningitis, hydrocephalus, etc. In these cases, the patient, as a rule, does not consult the ophthalmic surgeon until it is too late—when the process is already so advanced that sight is seriously compromised if not entirely lost.

The affection is usually first manifested by headache, accompanied by nausea and vomiting, symptoms that are

likely to suggest gastric disturbances or migraine. At other times the picture is different. The patient, feeling that his sight is failing, comes to the oculist with double optic neuritis already several weeks old. The papilla is very swollen and its borders are ill-defined. An edematous infiltration, with hemorrhagic streaks, accompanies the tortuous and turgescent vessels, which are sometimes more or less hidden by the exudation and by the edematous tissue of the papilla.

At other times the same clinical picture may be met with in patients who make no complaint whatever of their sight, but who are brought for the ophthalmoscopic confirmation of a diagnosis of cerebral tumor. The visual acuity is normal; colors are well seen; the visual field presents no peculiarities except an enlargement of the blind spot. But sight speedily fails, and if the cause cannot be removed, complete blindness may ensue from white atrophy of the optic nerves. In this instance the disease is extremely difficult to cure because an exact diagnosis is usually impossible. If the patient has suffered from disease of the ear localized to the side of the morbid process, we may suppose that meningitis from caries of the petrous exists, and surgical interference undertaken in time may by the evacuation of the purulent collection, bring about a complete cure. But it must be recognized that these are exceptional cases, and it is commoner to find a double optic neuritis unaccompanied by any symptom precise enough to allow of absolute diagnosis. It is fortunate when the history of the patient indicates a specific or even tuberculous origin. We should then have recourse to intensive inunctions of mercury and to the administration of potassium iodid in large doses. In this way more or less complete cure may sometimes be obtained. The morbid intracranial process may be extinguished either spontaneously or under the influence of treatment, and life is saved. But more frequently the sight is lost or returns very imperfectly, and white atrophy

of the optic nerves is the inevitable consequence of the neuritis.

When intracranial tuberculosis is suspected, the patient must be submitted twice a day to inunctions of guaiacolated cod-liver oil, 5:100 (Abadie), at the same time taking raw meat juice, beef extract, the yolk's of eggs, etc. By the adoption of this treatment we may cause the headache and nausea to disappear, and the sight to notably clear. The most persistent lesion is the infiltration of the papilla. Two cases of cure of this kind were observed by Arnold and the writer. But cure can be looked for only when the process is not too far advanced.

During the last few years **surgical intervention** has been frequently employed in optic neuritis.

Trephining has yielded some success, although often it has been impossible to reach the morbid focus. It would appear, therefore, that reduction of the intracranial pressure has a direct action upon stasis neuritis.

A diminution in the tension of the cerebrospinal fluid may be equally brought about by **lumbar puncture.** In one case the writer observed a marked but transitory improvement in sight after lumbar puncture had been performed. Inasmuch as lumbar puncture has an action only of short duration, it has been proposed to make a kind of **vertebral trepanation** by resecting one or several of the lamellæ of the spine.

These procedures, which belong to the realm of major surgery, have not yet been sufficiently studied to allow of definite indications. But the results of the various communications and discussions of the last few months may be **summarized** as follows.

1. The regression of papillary stasis, either definitive or for a long time, may be brought about by trephining.

2. When the operation is performed in good time, prognosis as regards sight appears to be favorable, but unfavorable when the vision is useless. The operation is generally done too late.

3. The duration of life in those who have been trephined successfully, when dealing with true tumor, is rather favorably influenced by the operation.

4. Trephining may act not only upon papillary stasis but may also lead to complete cure, as in cases in which, despite clear evidence of tumor, nothing can be found except pseudotumor, hydrocephalus, chronic encephalitis, serous meningitis, etc. Cure or blindness may result in these cases.

5. The risks of the operation must be considered. But, in general, the danger is least when trephining is performed solely for the purpose of preserving sight.

6. The immediate danger of the operation may be lessened by adopting certain precautions, such as the administration of chloroform instead of ether, performing the operation in two stages, anesthetizing the dura mater by cocain, the slow evacuation of the encephalic liquid, and the rapid occlusion of the wound without osteoplasty.

7. In certain cases the intracranial pressure may be adequately reduced without opening the dura mater, although in most cases the latter is best resected.

8. In order to arrive at the result, a cerebral hernia (which often appears) is necessary. The protrusion therefore must not be combated, although its development may be moderated.

9. When the tumor can be localized with enough exactitude, the trephine should be applied over the part, but otherwise the right parietal region is chosen.

10. The relatives of the patients should be warned that success cannot be absolutely guaranteed. Nevertheless, operation should be proposed as soon as sight commences to fail from stasis neuritis.

11. Lumbar puncture as a means of treatment cannot be considered except when the presence of tumor is very problematic. Ventricular puncture by trephining and large incision of the corpus callosum, with or without drainage, have been proposed as last resorts.

12. The employment of Neisser's exploratory puncture may be useful, especially when it is hoped to prevent blindness (E. von Hippel).

Up to the present all surgical attempts bearing upon the optic nerve itself; as, for example, incision of the sheath of the nerve, *élargation* of the optic nerve itself, etc., have yielded results too inconstant and too imperfect to allow of recommendation. It is possible that in future these operations may be performed with more precision by taking advantage of Krönlein's method, whereby the depths of the orbit can be thoroughly explored.

If our therapeutic resources are still of doubtful value in the treatment of optic neuritis of cerebral origin, they are even more so in the essential atrophies of the optic nerve arising from affections of the spinal cord.

The **white atrophy** succeeding to neuritis may still to some extent be influenced by certain medicaments, especially when the primary affection causing the neuritis is in process of regression. It is then possible that certain fibers of the optic nerve which have not become absolutely atrophied may be recalled to life. These clinical indications must not be allowed to escape, for they never present themselves again.

Gray atrophy, which often constitutes one of the first signs of tabes dorsalis and of some other affections of the spinal cord, offers the worst prognosis. Indeed, after the diagnosis is once well established by ophthalmoscopic examination, mensuration of the visual field, perception of colors, etc., more or less complete blindness is merely a question of time.

The evolution of the atrophy is extremely irregular. Blindness is often complete in one or two years. But it sometimes happens that one eye alone is seized, while the other (more or less affected) retains a certain amount of sight for several years. At other times the process may develop with great rapidity, although some central fibers

may remain intact, and thus allow the patient to retain a glimmer of sight for the rest of his days.

It is difficult to decide what is the share taken in these arrests of disease by the different methods of treatment employed. It is also difficult to explain how medicaments can act well upon a degenerative process, pure and simple, of the nerve fibers. Most of the remedies which have been praised in atrophy of the optic nerve are merely stimulants, as strychnin or brucin, or eutrophics, as phosphorus or arsenic. Electricity applied to the optic nerves, or, rather, to the eyeballs has a suggestive rather than an actual effect, but it is always a good method, because it never does harm.

Mercurial treatment is indicated in certain cases of tabes, in which specific antecedents are very evident. Even in these conditions, however, it is followed by poor results. The opinion of authors differs with regard to whether this is because the treatment is instituted too late, or is carried out with too little energy. Some think that specific treatment is capable of bringing about, if not a cure, at least a relaxation of the morbid process. On the contrary, others (and they are numerous) have found that sight fails rapidly under the influence of mercurial medication. This fact is frequently observed: after about a dozen intravenous injections, the sight of the worse eye diminishes rapidly, and the other eye fails in turn. But at the end of the twentieth injection, sight remains stationary and often improves a little, when there may intervene a complete arrest of the atrophy lasting for several years. Whether or not this is a matter of pure chance, no one can say.

A tumor of the hypophysis, compressing the chiasm, gives rise to a peculiar form of progressive atrophy of the optic nerve. The first symptom is temporal hemianopsia, either of one or of both eyes. By means of radiography, an enlargement of the sella turcica can be observed. There may or may not be acromegaly. If the tumor is of syphilitic nature, specific treatment may cure the patient. Otherwise, pituitary and thyroid gland should be administered.

An atrophy of the same order is observed in **oxycephaly (Thurmschaedel)**, in which precocious ossification of the cranial sutures, with meningitis, produces neuritis followed by optic atrophy. The early treatment should be that of retrobulbar neuritis. During the later stages, treatment is useless.

INDEX.

Abrin, 77
Abscess of orbit, paraspecific serotherapy in, 197
Albuminuria, in relation to eye disease, 16
  milk diet in, 85
Acne rosacea of cornea, 276
    dionin in, 277
    guaiacol in, 277
    high-frequency current in, 277
    hydrotherapy in, 277
    iridectomy in, 277
    laxatives in, 277
    turpeth mineral in, 277
    yellow ointment in, 277
  of eyelids, 212
    sulphur in, 212
    turpeth mineral in, 212
Acoin and cocain, 145
    in burns, 151
    in enucleation, 151
    in removal of lacrimal sac, 151
    in strabismus operations, 151
  as analgesic, 147
  as anesthetic, 137
  combined with mercury cyanid, 47
  in burns of conjunctiva, 138
    of cornea, 266
  in conjunctival irritation, 220
  in infiltration anesthesia, 148
  in parenchymatous keratitis, 286
  in retinal detachment, 384
  in retinal electrocution, 382
  in subconjunctival injections, 149
  in trauma of cornea, 138
  in vesicular keratitis, 274
  in zona ophthalmica, 274
  preparation of solutions, 149
Aconitin, antineuralgic, 86
Actol, silver lactate, 189
Adonidin, in glaucoma, 156
  in iritis, 156
  in keratitis, 156
Adrenalin, antidote to opium and morphin, 165
  in adynamic conditions, 165
  in chronic glaucoma, 357
  in collapse from chloroform, 165
  in conjunctivitis, 167
  in corneal ulcer, 168
  in episcleritis, 290, 293
  in glaucoma, 169, 349
  in hemorrhage, 78
  in iridectomy for glaucoma, 353
  in iritis, 171, 295
  in keratitis, 167
  in pannus, 168
  in prolapse of iris, 341
  in retinal electrocution, 382
  in scleritis and sclerokeratitis, 290
  in spring catarrh, 168, 241
  in strumous pannus, 271
  intravenously, 171
  subconjunctivally, 172
  with atropin, 165
  with cocain, 165
    in conjunctivitis, 167
  with eserin, 165
  with stovain and cocain, 167
Advancement, in paralysis of ocular muscles, 199
Adynamic conditions, adrenalin in, 165
Affections of sinuses, treatment of, 198
Air injections, indications of, 49
    in episcleritis, 49
    in iritis, 301
    in phlyctenular keratoconjunctivitis, 49
    in traumatic keratalgia, 49
    in tuberculous choroiditis, 370
    in tuberculous iritis, 307
  subconjunctivally, in phlyctenular keratitis, 270
    in vesicular keratitis, 275
Alcohol and cocain injections, in blepharospasm, 201

Alcohol dressings, 93
alternated with heat, 89
as aid to mydriasis, 174
in advanced corneal infection, 257
in ocular pain, 153
in paralysis of ocular muscles, 199
in parenchymatous keratitis, 285
in relapsing central retinitis, 375
in syphilitic iritis, 309
injections, in trigeminal neuralgia, 200
Aleurone, in infections, 73
Alkaline lotions, in corneal marginal ulcer, 272
waters, in atrophic macular retinitis, 377
Alkalines, in diabetic retinitis, 378
Aluminium acetate, in ophthalmia neonatorum, 237
Alypin, 144
Amaurosis, uremic, 371
Amblyopia, 371
consecutive to lactation, 398
diuretics in, 86
strychnin in, 87
toxic, pilocarpin sweats in, 83
Amyl nitrite, in cocain poisoning, 141
Analgesics, 146
disadvantages of, 153
Anaphylaxis, 54
Anatomico-pathologic diagnosis, 3
Anemia, bone-marrow and spleen-pulp in, 80
in relation to eye disease, 16
purgatives and laxatives in, 84
Anesthesin, 146
in burns of cornea, 266
in zona ophthalmica, 274
Anesthetics, 136
contraindicated in intravenous injection, 37
Anterenol, 172
Anterior sclerotomy of, de Wecker, 360
Antidiphtheritic serum, after cataract extraction, 340
in diphtheritic conjunctivitis, 239
in purulent iridocyclitis, 308
in zona ophthalmica, 213
of Roux-Behring, 52
indications, 53
Antiformin, as bacteriolytic agent, 75
Antiinfective serotherapy, in suppurative choroiditis, 370
in sympathetic ophthalmia, 316
Antiplague serum, intravenously, 37
Antipneumococcic serum, in infective corneal ulcers, 55
technic, 57
Antipyretics, in neuralgia, 86
Antipyrin, 86, 152
in diabetic retinitis, 378
in episcleritis, 291
in inflammatory glaucoma, 352
in iritis, 297
in retinal electrocution, 382
in trigeminal neuralgia, 200
Antiseptics, 179
Antispasmodics, 86
Antistreptococcus serum, 59
in rheumatic affections of eye, 59
in suppuration of lacrimal sac, 59
Antitetanic serum, after wounds, 58
intravenously, 37
in wounds of eyelids, 214
Antithyroidin, in diabetes, 79
Antitoxic serum, 51
intravenously, 37
Apomorphin, in hemorrhage in cataract extraction, 340
Aqueous collyria, 135
Arc lamp, in phototherapy, 97
Argonin, 188
Argyrol, 182
immersion, in gonococcal ophthalmia, 234
in arborescent keratitis, 273
in aspergillary keratomycosis, 278
in conjunctivitis, 185, 224
in dacryocystitis, 206, 207
in excessive lacrimation, 205
in extraction of cataract, 335
in granulous conjunctivitis, 244
in infection after cataract extraction, 343
in metastatic gonorrheal conjunctivitis, 237
in opthalmoblennorrhea, 184
in Parinaud's infective conjunctivitis, 242
in phlyctenular keratitis, 269
in purulent conjunctivitis, 226
in purulent dacryocystitis, 207
in purulent ophthalmia, 185

Argyrol, to prevent ophthalmia neonatorum, 238
Arning and Klein's method, 4
Arsacetin, 17
in syphilis, 17, 35
Arsenic in leukemic retinitis, 378
in pustular keratitis, 270
intravenously, 37
Arsenical preparations in syphilis, 34
Arteriosclerosis, iodids in, 15
milk diet in, 16
nitrites in, 16
ocular complications of, 15
treatment, 15
Arthritis, complicating purulent ophthalmia, 233
Aspergillary keratomycosis, 277
argyrol in, 278
collargol in, 278
iodoform in, 278
Aspiration in retinal detachment, 383
in tuberculous iritis, 307
Aspirin in blennorrhagic iritis, 305
in episcleritis, 291
in marginal ulcer of cornea, 271
in prodromal glaucoma, 350
in rheumatic affections, 152
Asthenopia, hydromineral treatment in, 122
massage in, 124
spermin and testicular extract in, 80
Astigmatism in wounds of the lens, 322
Astringents and antiseptic caustics, 180
Atoxyl in iritis, 304
in parenchymatous keratitis, 284
in syphilis, 17, 35
Atropin, action of, 173
alternately with eserin, in posterior synechiæ, 318
combined with adrenalin, 165
in cataract extraction, 321
in central ulcer of cornea, 271
in corneal lepromata, 278
in episcleritis, 294
in extraction of cataract, 338
in fascicular keratitis, 271
in infected wounds of eyeball, 263
in infections after cataract extraction, 343
in iritis, 164, 173, 295, 297, 298
in keratitis, 173, 269
Atropin, in parenchymatous keratitis, 283
in retinal detachment, 391
in sympathetic ophthalmia, 314
in tuberculous iritis, 307
toxic symptoms, 174
Autoplasty, in burns of cornea, 266
by caustics, 268
in filamentary keratitis, 276
in infective wounds of eyeball, 262
in prolapse of iris, 341
in staphyloma of cornea, 289
in sympathetic ophthalmia, 316
in wounds of lens, 326
in xerosis, 252

B

Bacteriologic diagnosis, 3
Bacteriolytic agents, antiformin, 75
bile, 75
pyocyanose, 74
thalianin, 75
Beef-serum in ophthalmia neonatorum, 237
Behring serum in wounds of eye, 62
Bier's method in dacryocystitis, 95
in keratitis, 95
in styes, 95
of inducing hyperemia, 95
Bier-Tuffier's method of rachianesthesia, 38
Bile in corneal ulcerations, 75
Biniodid, intravenously, 33
oil injections, 28
solutions, 28
Biologic method of Bordet and Gengou, 10
Bipolar electrolysis in nevus, 103
in xanthelasma, 103
Blennorrhagia, collargol injections in, 191
Blepharitis, ciliary, 217
collargol in, 218
eau d'Alibour in, 218
mercurial lanolin in, 218
protargolage in, 218
turpeth-mineral in, 218
cold compresses in, 216
hydromineral treatment in, 122
hypertrophic, electrolysis in, 217
galvanopunctures in, 217

Blepharitis, hypertrophic, grattage in, 217
lead lotion in, 216
marginal, cocarenalin in, 217
copper sulphate in, 217
ichthyol in, 217
lead extract in, 217
protargolage in, 217
red precipitate in, 217
yellow precipitate in, 217
zinc oxid in, 217
zinc sulphate in, 217
massage in, 132
Pagenstecher's ointment in, 133
parasitical, mercurial lanolin in, 218
resorcin in, 218
protargolage in, 182
purgation in, 85
refraction in, 216
ulcerous, 217
vapor douches in, 91, 216
Blepharospasm, dionin in, 201
electricity in, 201
injections in, 201
probing in, 202
radium in, 201
surgical treatment of, 201
Blisters, action of, 94
Blood-letting in detachment of retina, 383, 390
in retrobulbar neuritis, 397
in thrombosis of retinal veins, 373
Bone-marrow and spleen-pulp in anemia, 80
Boric lotion, in conjunctival irritation, 220
in purulent conjunctivitis, 226
Bowman's probes, in dacryocystitis, 206
Bromids, in conjunctival irritation, 219
in exophthalmic goiter, 198
Brossage in conjunctivitis, 224
in trachoma, 246, 249
Brucin in optic atrophy, 409
Buller's shield in ophthalmia, 235
in trachoma, 235
Burns, acoin and cocain in, 151
collargol in, 193
of cornea, 266
acoin in, 266
anesthesin in, 266
autoplasty in, 266
dionin in, 266
orthoform in, 266
picric acid in, 266
by caustics, 268
autoplasty in, 268
Burns, of cornea, by caustics, iodoform in, 268
picric acid in, 268
by lime, euvaselin in, 268
milk in, 268
oil in, 268
by vapor, 267
dionin in, 267
orthoform in, 146

C

Calcium chlorid to avert hemorrhage in iridectomy, 360
or lactate, in hemorrhage of the vitreous, 363, 364
subconjunctivally, in retinitis proliferans, 376
in vitreous hemorrhage, 364
Calomel in corneal opacities, 287
in hard chancre of eyelids, 215
in iritis, 301
injections in relapsing central retinitis, 376
in strumous pannus, 271
insufflation, 133
Canaliculus, incision of, in excessive lacrimation, 205
Canthus, incision of, in purulent ophthalmia, 229
Carbolic acid, 179
lotion injections, in malignant pustule, 215
plaster, 95
Cataplasm, 90
in eczema of eyelids, 211
Cataract, antidiphtheritic serum after extraction, 340
atropin in, 332
diabetic, hydromineral treatment in, 121
discission, followed by massage, 123
etiology of, 327
extraction of, 330
extraction, accidents during, 338
after treatment, 337
argyrol in, 335
atropin in, 321
chloroform in, 321
cocain for, 140, 145, 335
complications of, 338
contraindications to, 334
ethyl chlorid in, 321
followed by dionin, 160, 162, 321
glaucomatous complications of, 342
in child, 321

Cataract extraction, infective complications of, 342
iridectomy in, 321
mercury cyanid in, 335
paraspecific serotherapy in, 62
physostigmin in, 321
precautions before, 333
preparation of patient for, 334
protargol in, 335
sodium chlorid subconjunctivally in, 321
steps in the operation, 337
vibratory massage in, 321
incipient, dionin in, 329
electrolytic eye-bath in, 329
iodosol inunctions in, 329
iodized vasogene in, 329
medicamentous electrolysis in, 104
potassium iodin in, 329
sodium iodid in, 329
incomplete, 327
immature, pulverized crystalline lenses in, 80
in retinal electrocution, 381
iridectomy in, 320, 332
potassium iodid collyria in, 328
subconjunctivally in, 328
sodium chlorid subconjunctivally in, 328
spontaneous resorption of, 328
surgical treatment of, 330
traumatic, 324
extraction of, 326
iridectomy in, 325, 326
vibratory massage in, 125
Cathelin's method of epidural injection, 38
Cauterization in corneal ulcer, 259
in episcleritis, 290
in iritis, 302
in malignant pustule of eyelids, 215
in purulent ophthalmia, 228
in retinal detachment, 387, 391
in soft chancre of eyelids, 215
of sclera, in retinal detachment, 391
Chalazion, iodin ointment in, 214
radium in, 113, 214
Chancre (hard) of eyelid, calomel in, 215
mercurial injections and inunctions in, 215
radium in, 112, 215
sublimate in, 215
Chancre (soft) of eyelids, cautery in, 215
iodoform dressings in, 215
Chaulmoogra oil in corneal lepromata, 278
Cherry diuretic, 86
Chloral, 86
Chlorin water in conjunctival irritation, 220
in dacryocystitis, 206, 207
Chloroform anesthesia, in extraction of cataract, 321
in iridectomy for glaucoma, 353
in operation for trachoma, 248
narcosis, adrenalin in collapse from, 165
Choroidal hemorrhage, leeches in, 389
massage in, 389
sodium chlorid subconjunctivally in, 389
Choroid, diseases of, 365
alterant treatment in, 366
diaphoretics in, 82
pathogeny of diseases of, 365
Choroiditis, dionin in, 160, 370
exudative, mercurial injections and inunctions in, 389
mercury cyanid subconjunctivally, 389
iodo-ioduric injections in, 368
iodin trichlorid in, 368
light baths in, 96
myopic, mercury cyanid in, 400
sodium chlorid in, 400
pigmentary, 368
potassium iodid in, 370
sodium iodate in, 368
subconjunctival injection in, 367
suppurative, antiinfective serotherapy in, 370
enucleation, 370
hot compresses in, 370
mercury subconjunctivally, 370
thiosinamin, 370
tuberculous, air injections in, 370
guaiacol subconjunctivally in, 370
mercurial injections in, 370
vibratory massage in, 125
Chorioretinitis, mercury cyanid in, 47
injections in, 400

Chorioretinitis, myopic, leeches in, 84
sodium chlorid in, 400
specific, 375
Cicatrices, radium in, 112
Citric acid in corneal opacities, 288
Clinical diagnosis, 3
Cocain, 137
as anesthetic, 137
as mydriatic, 140
combined with acoin, 145
with adrenalin, 165
contraindicated in glaucoma, 164
in cataract operation, 140, 145, 335
in conjunctival irritation, 220
in corneal ulcer, 259
in glaucoma, 140
in infected wounds of eyeball, 63
in iridectomy for glaucoma, 353
in iritis, 295
injected with alypin, in conjunctival flap, 262
injections in enucleation, 142
in ophthalmoscopic examination, 176
in prolapse of iris, 341
in retinal electrocution, 382
in sympathetic ophthalmia, 314
in trachoma operation, 246
poisoning, 141
subconjunctivally, in operations for strabismus, 139
subcutaneous injections of, 141
with other mydriatics, 175
Cocarenalin, after trachoma operation, 250
in marginal blepharitis, 217
in connection with sublimate, 168
in iritis, 295
injection into lacrimal sac, 168
in dacryocystitis, 206
in excessive lacrimation, 204
ointment, in prurigo of eyelids, 211
prior to savonnage, 187
Codein, hydrochlorid of, 155
Cod-liver oil, in hemeralopia, 80
in pustular keratitis, 270
in tuberculous ulcerations of eyelids, 215
Colchicin in episcleritis, 292
in marginal ulcer of cornea, 272
Cold, action of, 92
compresses, after trachoma operation, 247
in blepharitis, 216
in retinal electrocution, 381
moist, 93
Collargol, 189
action as a diastase, 72
after cataract extraction, 338
as antiseptic in operations, 193
in aspergillary keratomycosis, 278
in blennorrhagia, 191
in blennorrhagic iridocyclitis, 305
in burns, 193
in complications of purulent ophthalmia, 192, 193, 233
in corneal infection, 191, 256, 257
in dacryocystitis, 192
in episcleritis, 191, 305
in infection after cataract extraction, 343
in iritis, 191
injections in chronic iridochoroiditis, 312
in keratitis, 279
in keratomalacia, 279
in operations, 193
in primary marginal ulcerations of cornea, 278
in sinus affections, 198
in tenonitis, 198
in trachoma, 193
intravenously, 37, 190
in erysipelas of eyelids, 212
in wounds, 193
in zona ophthalmica, 274
ointment, 190
in ciliary blepharitis, 217
in eczema of eyelids, 211
subcutaneously, 190
Colloidal mercury, intrarachidian injection of, 38
metals, 71
in leukemic retinitis, 378
Collyria, dry, 133
Coloboma, 320
Commotion retinæ, 382
electricity in, 382
eserin in, 382
massage in, 382
pilocarpin in, 382
Compressive bandage in contusion of eyeball, 388
in retinal detachment, 383, 390

Congenital aphakia, refraction in, 320
cataract, 320
imperforations of lacrimal canal, 203
Conjunctiva, hyaline and amyloid degeneration of, 253
Conjunctival flap, after extraction of cataract, 262
in burns of cornea, 266
in infected wounds of eyeball, 262
in prolapse of iris, 341
in sympathetic ophthalmia, 316
irritations, treatment, 219
Conjunctivitis, adrenalin in, 167
and cocain in, 167
alcoholic, 238
argyrol in, 185, 224
dionin in, 232
diphtheritic, serotherapy in, 53, 238
follicular, 243
lead acetate in, 243
granulous, 242
argyrol in, 244
protargol in, 244
silver nitrate in, 244
hydromineral treatment in, 122
itrol in, 188
massage in, 132
metastatic gonorrheal, 236
Pagenstecher's ointment, 133
pneumococcal, 222
protargol in, 181, 224
purgation in, 85
purulent, argyrol in, 226, 228
boric lotion in, 226
dionin in, 228
hot compresses in, 229
iced compresses in, 93
ichthargan in, 230
potassium permanganate in, 226
protargol in, 226, 228
sunlight in, 230
Roux-Behring serum in, 223
silver nitrate in, 180
simple, 221
types of, 238
zinc sulphate in, 223, 225
Constant current, 102
Constitutional treatment in eye disease, 14
of arteriosclerosis, 14
of lymphatism, 18
of syphilis, 18
Contusion of eyeball, 322
compressive bandage in, 388
dorsal decubitus in, 388
leeches in, 387
sodium chlorid subconjunctivally, 388
Convallaria majalis in glaucoma, 350
in chronic glaucoma, 357
Copper sulphate in marginal blepharitis, 217
in dacryocystitis, 206
in trachoma, 244
Cornea, abscess of, 254, 255
conical, galvanocautery in, 105
lepromata of, atropin in, 278
hot compresses in, 278
chaulmoogra oil in, 278
incision in extraction of cataract, 336
Corneal infection, 254
alcohol dressing in, 257
cocain in, 259
collargol in, 256, 257
dionin in, 256, 261
fluorescin in, 156
galvanocautery in, 258, 261
iodin in, 261
mercury cyanid subconjunctivally, 256, 257
methylene blue or violet in, 258
phenic acid in, 261
protargolage in, 256
Saemisch's transfixion in, 259
serotherapy in, 257, 260
sodium chlorid subconjunctivally, 257, 261
sodium iodate subconjunctivally, 257
stovain in, 259
sublimate in, 257
treatment of advanced, 256
of complications, 259
treatment of early cases, 255
of grave, 258
xeroform in, 256
zinc salicylate in, 260
zinc sulphate in, 261
infiltrations, dionin in, 158, 225, 281
dry abscesses, 155
massage in, 132
mesokeratitis, 280
sodium chlorid subconjunctivally in, 255, 281
lesions, Bier's method in, 95
in pemphigus, dionin, 275

Corneal, lesions, in pemphigus, milk, 275
leukomata, dionin in, 46
lithium benzoate in, 46
sodium chloride in, 46
surgical treatment of, 288
opacities, calomel in, 287
citric acid in, 288
dionin in, 287
gomenol in, 288
lactic acid in, 288
lithium benzoate in, 288
potassium iodid in, 288
sodium hyposulphite in, 288
thiosinamin in, 288
vapor douches in, 287
vibratory massage in, 125
yellow ointment in, 287
pannus, jequiritol in, 78
ulcer, adrenalin in, 168
antipneumococcic serum in, 55
atropin in, 271
collargol ointment in, 191
complications, 239
formol in, 259
galvanocautery in, 239, 259
itrol in, 189
light in, 97
marginal, 271
alkaline lotions in, 272
aspirin in, 271
colchicin in, 272
dionin in, 272
lithium in, 272
milk diet in, 272
protargolage in, 272
quinin in, 272
rhus toxicodendron in, 272
salicin preparations in, 271
sodium benzoate in, 272
sodium bicarbonate in, 272
sodium iodid, 272
sodium salicylate, 272
paracentesis of, 259
paraspecific serotherapy in, 58
phenic acid in, 259
potassium permanganate in, 239
powdered dionin in, 160, 258
pyocyanase in, 239
radium in, 113
serotherapy in, 259
subconjunctival injections in, 259
zinc sulphate in, 259
Corneal ulcerations, bile in, 75
following exophthalmos, 279
phototherapy in, 98
primary marginal, collargol in, 278
dionin in, 278
iodoform in, 278
Credé's method, 237
ointment, 190
Critchett's operation in staphyloma of cornea, 289, 290
Crystalline lenses, pulverized, in immature cataract, 80
Cutaneous diagnosis, epidermal method, 8
Cuti-reaction, Lautier's modification, 7
von Pirquet, 3, 7
Cyclodialysis, 356
Cysticercus, electrolysis in, 365
Cystotome in extraction of cataract, 321
Cysts, destroyed by electrocautery à froid, 105

D

Dacryoadenitis, dionin in, 203
mercurial poultice in, 203
pilocarpin in, 203
Dacryocystitis, 206
argyrol in, 206
Bier's method in, 95
Bowman's probes in, 206
chlorin water irrigations in, 206
cocarenalin injections in, 206
collargol in, 192
copper sulphate in, 206
dionin in, 203
extirpation of sac in, 206
glycerin-iodoform in, 209
guaiacol in, 206, 209
mercury in, 209
oxygenated water irrigations in, 206
potassium iodid in, 209
potassium permanganate in, 206
purulent, argyrol in, 207
electrolysis in, 207
irrigations in, 207
protargol in, 207
staphylase in, 71
tuberculous, guaiacol in, 207
zinc sulphate in, 206
Daviel's curet, in extraction of cataract, 321
in wounds of lens, 326

Dermatoses and superficial neoplasms, radium in, 112
Descemetitis, 276
light in, 97
Desmarres's retractors in extraction of cataract, 339
Detached retina, vitreous body of rabbits in, 80
Detachment of retina, 383
electrolysis in, 103
massage in, 124
Deutschmann's serum, 58
Diagnosis, anatomico-pathologic, 3
bacteriologic, 3
clinical, 3
etiologic, 14
experimental, 3
methods, 3
microscopic, 3
serum, 3, 6
therapeutic, 3, 12
Diabetes, antithyroidin in, 79
in relation to eye disease, 16
Diabetic cataract, hydromineral treatment in, 121
Diaphoresis, indications, 82
in retinal detachment, 383, 387, 390
Diet, in albuminuric retinitis, 377
in diabetic retinitis, 378
Dionin, 157
action of, as vasodilator, 157
alternating with sodium chlorid injections, 160
and mercury cyanid, after extraction of foreign body, 162
as analgesic, 146
as anesthetic, 137
as antiseptic, 162
deep analgesic action of, 153
following discission, 160
operation for cataract, 160
in acne rosacea of cornea, 277
in blepharospasm, 201
in burns of cornea, 266
in cataract extraction, 321
in choroiditis, 160, 370
in conjunctivitis, 232
in corneal infection, 256, 261
infiltration, 158, 255, 281
leukomata, 46
opacities, 287
ulcer, 258, 272, 278
wounds, 163
in dacryoadenitis, 203
in embolism of retina, 372
in episcleritis, 154, 160, 291
in glaucoma, 151, 153, 164, 350
Dionin in glaucoma, chronic, 357
in glaucomatous complications of cataract extraction, 342
in hemorrhage into anterior chamber, 158
in incipient cataract, 329
in infected wounds of eyeball, 263
in infection after cataract extraction, 343
in inflammatory glaucoma, 352
in injuries, 156
in zona ophthalmica, 213
in iridocyclitis, 151
in iritis, 151, 160, 298, 299
injections, 155
before iridectomy, 354
for anesthesia, 137
in keratitis, 154, 159
in keratomalacia, 279
in macular keratitis, 275
in panophthalmitis, 154
in pemphigus, 275
in phlyctenular keratitis, 270
in purulent ophthalmia, 161, 228
in relapsing central retinitis, 375
in retinal detachment, 383, 391
in retinal electrocution, 382
in retinitis, 160
in retrobulbar neuritis, 160
in rheumatic iritis, 153
in striated keratitis, 280
in strumous pannus, 271
in subconjunctival ecchymoses, 158
infiltrations, 160
in sympathetic ophthalmia 314
in syphilitic iritis, 310
in trachomatous pannus, 160
in traumatic mesokeratitis, 281
in vapor burns of cornea, 267
in vesicular keratitis, 274
in xerosis, 252, 279
in zona ophthalmica, 274
massage in trachoma, 244
method of using, 162
prior to subconjunctival injections, 159
subconjunctivally, in zona ophthalmica, 274
to favor mydriasis, 174
to resorb crystalline masses, 345

Diplopia monocular, in subluxation of lens, 323
Discission, 321
dionin following, 160
massage after, 131
of detached retina, 383
repeated, in high myopia, 345
Distichiasis, electrolysis in, 102
Diuretics in tobacco and alcohol amblyopia, 86
in uric acid diathesis, 85
Dog's grass, diuretic, 85
Dor's ciliary extract, 379
Dorsal decubitus in contusion of eyeball, 388
in retinal detachment, 387, 390
Doyne's optocine, in retinitis pigmentosa, 379
Dressings, alcohol, 89, 93
cold moist, 93
Priestnitz's, 93
Dry-heat baths, 82
Duboisin, 175

E

Eau d'Alibour compresses in ciliary blepharitis, 218
Ecchymoses peribulbar, sodium chlorid injections in, 158
subconjunctival, dionin in, 158
Ectopia of crystalline lens, 320
Ectropin, galvanocautery in, 105
Eczema, impetiginous, of eyelids, 212
of eyelids, 211
cataplasms in, 211
collargol ointment in, 211
hydromineral treatment in, 121
ichthyol in, 211
lead acetate in, 211
moist dressings in, 211
sulphuric acid in, 211
tar in, 211
vapor douches in, 211
Edema of eyelids, 214
Egg-shell membrane, in burns of cornea, 267
Ehrlich's side-chain theory, 78
Electrargol, 194
Electricity, as dry heat, 92
effect on retina, 380
in blepharospasm, 201
in commotion retinæ, 382
in herpes febritis of cornea, 273
in optic atrophy, 409
Electricity, in paralysis of ocular muscles, 199
in retinal electrocution, 382
in retinal injuries by light, 382
in retinitis pigmentosa, 379
in trigeminal neuralgia, 200
in zona ophthalmica, 213, 274
medicamentous, in episcleritis, 293
Electric-light baths, in chronic diseases of the eye, 96
indications, 96
Electrocautery à froid, 105
Electrolysis bipolar, in nevus, 103
in chronic lacrimation, 205
in corneal opacities, 288
in cysticercus, 365
in dacryocystitis, 207
in detachment of retina, 103
in distichiasis, 102
in hypertrophic blepharitis, 217
in retinal detachment, 383; 386, 393
in trachoma, 246
in trichiasis, 102
in vitreous hemorrhages of the aged, 364
in xanthelasma of eyelids, 213
medicamentous, in incipient cataract, 104
in rheumatic eye conditions, 104
in rheumatic neuralgia, 104
in trigeminal neuralgia, 200
Electrolytic eye-bath in incipient cataract, 329
puncture in retinal detachment, 384, 392
method, 392
Electromagnets, in extraction of foreign bodies, 106
Electrotherapy, indications, 101
in iritis, 101
in keratitis, 101
in scleritis, 101
Embolism of central artery of retina, 372
of retina, dionin in, 372
iridectomy in, 372
massage of eyeball in, 372
paracentesis in, 372, 373
saline injections in, 372
sodium nitrate injections in, 372
sodium iodate injections in, 373
subconjunctival injections in, 372

Emphysema of eyelids, 214
lead extract in, 214
Enesol, in tertiary syphilis, 34
Enophthalmos, 198
paraffin injections in, 198
tenotomy in, 198
Enucleation, 315
acoin and cocain in, 151
adrenalin with stovain and cocain, 167
cocain injections in, 142
in infected wounds of eyeball, 264
in panophthalmitis, 316
in retinal detachment, 389
in suppurative choroiditis, 370
in sympathetic ophthalmia, 313, 316
in tuberculous iritis, 308
novocain in, 144
Ephedrin, 176
Epidermal method of cutaneous diagnosis, 8
Epidural injection, Cathelin's method, 38
Epithelioma of eyelids, jequirity in, 215
methylene blue in, 215
potassium chlorate in, 215
radium in, 112, 215
X-rays in, 215
Episcleral nodosities, 293
Episcleritis, 289
adrenalin in, 289, 293
air injections in, 49
alkalies in, 292
antipyrin in, 291
aspirin in, 291
atropin in, 293
cautery in, 290
colchicin in, 292
collargol in, 305
injections in, 191
diagnosis of, 289
dionin in, 154, 160, 291
electricity, medicamentous, in, 293
galvanocautery in, 105, 293
guaiacol in, 49, 294
heat in, 293
high-frequency current in, 293
injections of sterilized air in, 49
iodoform in, 294
iridectomy in, 290
light baths in, 293
lithium in, 292
massage in, 123
mercurial lanolin in, 134
phenacetin in, 291
Episcleritis, pilocarpin in, 293
salicin, 292
sodium salicylate injections, 47, 291
subconjunctival injections in, 290
tuberculin in, 294
vapor baths in, 293
vibratory massage in, 125
Ergotin injection in hemorrhage in cataract extraction, 340
Erysipelas of eyelids, collargol injections in, 212
paraspecific serotherapy in, 212
Eserin, 178
alternately with atropin, in posterior synechiæ, 318
in commotion retinæ, 382
in detachment or retina, 383
in glaucoma, 164, 348, 349, 350
chronic, 357
in glaucomatous complications of cataract extraction, 342
in infected wounds of eyeball, 263
in inflammatory glaucoma, 352
in iridectomy for glaucoma, 353
in prolapse of iris, 341
in subluxation of lens, 323
oily collyria of, 356
with adrenalin, 165.
Ethyl chlorid, 137
in cataract extraction, 321
for paracentesis, 301
Etiologic diagnosis in eye disease, 14
Eucain B, 142
Eumydrin, 176
Euphthalmin for mydriasis, 177
Euvaselin in burns of cornea by lime, 268
in keratomalacia, 279
in ophthalmia neonatorum, 237
Exophthalmic goiter, bromids in, 198
quinin sulphate in, 198
radium in, 199
serotherapy in, 199
sodium salicylate in, 198
spermin and testicular extract in, 80
surgical treatment, 199
thyroid treatment in, 79
valerian in, 198

Exophthalmos, infective, paraspecific serotherapy in, 198
pulsating, 198
gelatin injection in, 198
potassium iodid in, 198
Experimental diagnosis, 3
Expression in trachoma, 246
Extract of ciliary body in sympathetic ophthalmitis, 80
of retina in retinal diseases, 80
of uveal tract in retinitis pigmentosa, 80
Eyelid operations, stovain in, 143

F

Facial neuralgia, radium in, 117
paralysis, radium in, 116, 117
Fascicular keratitis, 271
atropin in, 271
Finsen's phototherapy in trachoma, 116
Fluorescin in arborescent keratitis, 273
in corneal infection, 256
in strumous pannus, 271
Forceps, special toothed, in trachoma operation, 247
Foreign bodies, 106
extraction followed by dionin and mercury cyanid, 162
radioscopy in diagnosis, 108
sideroscope in diagnosis, 107
extraction by electromagnet, 106
Formol in corneal ulcer, 259
Formol-alcohol, a disinfectant, 249
Friction-massage with mercurial lanolin, 134
Frottage in trachoma, 244

G

Galvanocautery, combined with paraspecific serotherapy, 104
in abscess of lacrimal sac, 209
in conical cornea, 105
in conjunctival flap, 263
in corneal infection, 258, 261
in corneal rodent ulcer, 279
in corneal ulcer, 239, 259
indications, 105
in ectropion, 105
in episcleritis, 105, 293
in filamentary keratitis, 276
in infected wound of eye, 255, 262
in infection after cataract extraction, 343
Galvanocautery, in neons, 105
in scleritis, 105
in sympathetic ophthalmia, 316
in trachoma, 105, 246
in tuberculous ulcerations of eyelids, 215
in tumors of eyelids, 105
Galvanopunctures in blepharitis, hypertrophic, 217
Gas-light in phototherapy, 98
Gelatin in hemorrhagic diathesis, 81
injections in detachment of retina, 384
in exophthalmos, pulsating, 19
in vitreous hemorrhage, 364
serum, in retinitis proliferans, 376
to avert hemorrhage in iridectomy, 360
Glaucoma, adonidin in, 156
adrenalin in, 169, 349
chronic, adrenalin in, 357
convallaria majalis, 357
dionin in, 357
eserin in, 357
iridectomy in, 355
iodids in, 357
irritative, 354
massage in, 357
miotics in, 355, 356
pilocarpin in, 357
quinin in, 357
simple, 354
strophanthus in, 357
valerian in, 357
cocain in, 140
contraindicated in, 164
convallaria majalis in, 350, 357
corneal complications of, 274
dionin in, 151, 154, 164, 350,
eserin in, 164, 348, 349
high-frequency currents in, 102, 362
hyperacute, chloroform anesthesia in iridectomy, 353
infantile, 357
inflammatory, antipyrin in, 352
dionin in, 352
eserin in, 352
iridectomy in, 352
leeches in, 352
massage in, 352
phenacetin in, 352
pilocarpin in, 352
quinin in, 352

Glaucoma, inflammatory, sodium salicylate in, 352
iridectomy in, 348
irritative or inflammatory, 351
malignant, 360
iridectomy in, 360
pilocarpin injections in, 360
preliminary sclerotomy in, 360
sclerotic punctures in, 360
sodium iodate subconjunctivally, 360
massage in, 348
miotics in, 178
"paradoxical," 359
pathogeny of, 346
pilocarpin in, 164, 349
piperazin in, 349
potassium bromid in, 350
prodromal, 349
massage in, 131
quinin in 349, 350
sodium iodate in, 48
sodium salicylate in, 348
strophanthus hispidus in, 350
subacute, 361
symptoms of, 347
valerian in, 350
vibratory massage in, 125
Glaucomatous complications of cataract extraction, dionin in, 342
eserin in, 342
sodium iodate subconjunctivally in, 342
Glycerin in xerosis of cornea, 279
Glycerin-iodoform in dacryocystitis, 209
Gold sheet in burns of cornea, 267
Gomenol in corneal opacities, 288
Gonococcal infection in adults, 233
pyocyanase in, 75
Gout, milk diet in, 85
Graefe knife in corneal opacities, 288
in extraction of lens, 323
in iridectomy, 353
Grattage in blepharitis hypertrophic, 217
in trachoma, 246
Gray oil injections, 26
in relapsing central retinitis, 376
Guaiacol for diagnosis, 12
in acne rosacea of cornea, 277
in conjunctival irritation, 220
in episcleritis, 294
injections in dacryocystitis, 206, 209
Guaiacol in macular keratitis, 275
in ocular tuberculosis, 285
in parenchymatous keratitis, 284
in Parinaud's infective conjunctivitis, 242
in phlyctenular keratitis, 269
in scleritis, 291
in spring catarrh, 241
in tuberculosis of conjunctiva, 241
in tuberculous choroiditis, 370
dacryocystitis, 207
iritis, 306
ulcerations of eyelids, 215
in xerosis of cornea, 279
in zona ophthalmica, 274
ointment after trachoma operation, 250
reaction, 49
subconjunctivally, associated with tuberculin injections, 70
in episcleritis, 49
in iritis, 49
Guaiacolated cod-liver oil in intracranial tuberculosis, 406
in tuberculous neuritis, 406

H

Haab's iodoform pencils, 365
Headache, aconitin in, 86
purgation in, 85
Heat, action of, 89
and cold, indications and contraindications, 87
dry, in rheumatism, 92
in episcleritis, 293
in inflammation and suppuration, 88
methods of applying, 90
moist, 90
Schaeffer's experiments with, 88
Helidor in phototherapy, 96
Heliotherapy, 96
Hemeralopia, cod-liver oil in, 80
lamb's liver in, 80
Hemianopsia in optic atrophy, 409
Hemolysin, 75
Hemolytic serum injections in retrobulbar neuritis, 397
in vitreous hemorrhage, 75
subconjunctivally, in vitreous hemorrhage, 364
Hemophilia, normal serum in, 74
raw meat in, 81

Hemorrhage into anterior chamber, dionin in, 158
in cataract extraction, 340
apomorphin in, 340
compression in, 340
ergotin in, 340
morphin in, 340
of vitreous, 363
calcium chlorid or lactate in, 364
iron perchlorid in, 363
quinin in, 363
quinquina in, 363
Roux serum in, 363
sulphuric lemonade in, 363
wine in, 363
Hemorrhagic affections of eye, serotherapy in, 74
diathesis, treatment of, 81
Heroin, 155
Herpes febrilis of cornea, 273
electricity in, 273
iodoform in, 273
quinin in, 273
serotherapy in, 273
yellow ointment in, 273
Hetol, intravenously, in tuberculosis, 37
High-frequency current in acne rosacea of cornea, 277
in episcleritis, 293
in glaucoma, 102, 362
in lupus of eyelids, 216
in relation to X-rays, 109
High myopia, mercury cyanid subconjunctivally in, 369
removal of lens in, 344
Holocain, 142
in iridectomy, 142
for glaucoma, 353
Homatropin in refraction, 175
Homorenon, 172
Hot air, 92
applications in striated keratitis, 281
baths, in retinal electrocution, 381
compresses, 90
and poultices in iritis, 299
in corneal lepromata, 278
in infection after cataract extraction, 343
in ocular pain, 153
in parenchymatous keratitis, 283
in purulent ophthalmia, 229
in suppurative choroiditis, 370
in syphilitic iritis, 309
Hutchinson's triad, 281
Hyalitis, 363
chronic, 365
Hyaloid artery, persistence of, 320
Hydriodic acid in trachoma, 245
Hydrogen peroxid in corneal opacities, 288
Hydromineral stations, 120
Hydrophthalmos, buphthalmus, 357
iridectomy in, 357
mercurial injections in, 357
pilocarpin in, 357
Hydrotherapy in acne rosacea of cornea, 277
indications, 120
in relapsing central retinitis, 375
Hyperthyroidism, antithyroid, 79
Hypertonus, ocular, tuberculin and guaiacol in, 70
Hypodermic medication of mercury, 24
prevention of complications, 25
technic, 25
Hypopyon keratitis, infective, antidiphtheritic serum in, 62
paraspecific treatment in, 62
galvanocautery in, 62
subconjunctival injection in, 62
paracentesis in, 62
mercury cyanid in, 47

I

Iced compresses after trachoma operation, 250
in blennorrhagic conjunctivitis, 93
in ophthalmoblennorrhea, 186
Ichthargan in purulent conjunctivitis, 230
Ichthyol in blepharitis marginal, 217
in eczema of eyelids, 211
Ignipuncture in detachment of retina, 383
Immunization, active, 65
passive, 66
against pneumococcus, 56
active—vaccins, 60
passive—sera, 60
Incandescent lamp as dry heat, 92
Infected wounds of eyeball, 261
atropin in, 263
cauterization in, 264
cocain in, 263
conjunctival flap in, 262

Infected wounds of eyeball, dionin in, 263
enucleation in, 264
eserin in, 263
galvanocautery in, 255, 262
lavage in, 262
leeches in, 263
mercury cyanid in, 262, 263
serotherapy in, 264
subconjunctival injections, 264
Infection after extraction of cataract, 342
argyrol in, 343
atropin in, 343
collargol in, 343
dionin in, 343
galvanocautery in, 343
hot compresses in, 343
iodoform in, 343
mercury cyanid in, 343
serotherapy in, 343
sodium chlorid in, 343
Infections, aleurone in, 73
normal salt solution in, 73
nucleinic acid and nucleinates in, 73
of eyeball, serotherapy in, 260
sera in, 73
traumatic of eye, treatment of, 258
warmed horse's serum in, 73
Infusions of plants in conjunctival irritation, 219
Injection, hypodermic, of mercury, 24
in traumatic retrobulbar neuritis, 396
of mercury cyanid, 17
of sterilized air, indications, 48
subconjunctival, of mercury, 23
tuberculin, 6
Injuries, dionin after, 156
massage after, 131
of cornea, dionin in, 163
Insolation of wounds, 99
Insufflation, indications, 133
Interstitial keratitis, mercurial poultice in, 24
sodium chlorid injections in, 47
Intestinal derivatives in albuminuric retinitis, 377
Intraocular hemorrhage, dilaceration of opacities in, 365
punctures of vitreous in, 365
pilocarpin in, 364
thyroidin in, 365
Intraocular hemorrhage, thyroid treatment in, 79
injections of iodoform, 59
of mercury cyanid in sympathetic ophthalmitis, 47
Intrarachidian injection, methods, 38
of colloidal mercury, 38
Intravenous injections, complications, 32
drugs contraindicated in, 37
in retinitis pigmentosa, 379
of arsenical preparations, 35
of colloidal silver, 37
of hetol, 37
of iodin, 36
of iron, 37
of mercury, 29
in relapsing central retinitis, 375
of pilocarpin, 36
of potassium iodid, 36
of quinin, 36
of serums, 37
of sodium salicylate, 36
technic, 30
Instruments in extraction of cataract, 336
Inunctions, mercurial, method of application, 24
Iodic medication in chronic iridochoroiditis, 312
Iodids in arteriosclerosis, 15
in chronic glaucoma, 357
in retinal detachment, 389
in syphilis, arsenic, 19
potassium, 19
Iodin, action of tincture in inflammation, 94
in conjunctival irritation, 219
in corneal infection, 261
injections in retinal detachment, 383, 384
in lymphatism, 18
intravenously, 36, 37
ointment in chalazion, 214
tincture in abscess of lacrimal sac, 209
in arborescent keratitis, 273
in corneal rodent ulcer, 278
in making conjunctival flap, 263
trichlorid in choroiditis, 368
in parenchymatous keratitis, 283
Iodized vasogene, in incipient cataract, 329
Iodoform dressings in soft chancre of eyelids, 215

Iodoform in aspergillary keratomycosis, 278
in burns of cornea by caustics, 268
of eyelid, 268
in conjunctivitis, 239
in episcleritis, 294
in herpes febrilis of cornea, 273
in infection after cataract extraction, 343
in keratomalacia, 279
in macular keratitis, 275
in Parinaud's infective conjunctivitis, 242
in primary marginal ulcerations of cornea, 278
in sympathetic ophthalmia, 316
intraocular injection of, 39
in zona ophthalmica, 274
ointment, in corneal complications, 233
in tuberculosis of conjunctiva, 241
in zona ophthalmica, 213
pencils in vitreous infections, 365
Iodo-ioduric injections in choroiditis, 368
Iodosol inunctions, in incipient cataract, 329
Iodotannic preparations in pustular keratitis, 270
in tuberculous ulcerations of eyelids, 215
Iridectomy, adrenalin in, 353
and cocain in, 166
chloroform in, 353
cocain in, 353
dionin injection before, 354
eserin in, 353
in acne rosacea of cornea, 277
in cataract, 320
extraction, 321
in central opacities of lens, 332
in chronic glaucoma, 355
in complicated cataract, 318
in corneal staphylomata, 318
in detachment of retina, 383
in diseases of lens, 320
in embolism of retina, 372
in episcleritis, 290
in extraction of cataract, 338
in glaucoma, 318, 348
holocain as anesthetic, 142, 353
in hydrophthalmos, 357
in inflammatory glaucoma, 352
Iridectomy, in irritative glaucoma, 351
in malignant glaucoma, 360
in parenchymatous keratitis, 287
in prodromal glaucoma, 351
in recurrent iritis, 318
in seclusio pupillæ, 317
in subluxation of lens, 323
in sympathetic glaucoma, 359
in traumatic cataract, 325
in wounds of lens, 326
morphin injection before, 354
results of, 361
Iridochoroiditis chronic, collargol injections in, 312
Lugol's solution in, 312
mercury intravenously, 312
pilocarpin injections in, 312
Tourneur's iodin in, 312
diaphoretics in, 82
iridectomy in, 318
metastatic purulent, 308
paracentesis in, 311
purulent, 308
subconjunctival injections in, 31
Iridocyclitis, Behring serum in, 308
blennorrhagic, collargol in, 305
dionin in, 151
hydromineral treatment in, 121
leeches in, 84
purgation in, 85
radium in, 116
Iritis, acute, leeches in, 84
adonidin in, 156
adrenalin in, 171, 295
antipyrin in, 297
atropin in, 164, 173, 295, 297, 299
blennorrhagic, 305
aspirin in, 305
potassium iodid in, 305
sodium salicylate in, 305
calomel in, 300
cautery in, 302
chronic rheumatic, treatment, 306
cocain in, 295
cocarenalin in, 295
collargol injections in, 191
complicating purulent ophthalmia, 233
diagnosis of, 295
diaphoretics in, 82
dionin in, 151, 160, 164, 298
faradic current in, 101

Iritis, guaiacol in, 49
hot compresses in, 298
hydromineral treatment in, 121
iridectomy in, 318
leeches in, 300
light baths in, 96
local indications in treatment, 308
metastatic purulent, 308
methyl-atropin in, 176
miotics in, 178
morphin injections in, 298
paracentesis in, 300
paraldehyd in, 298
pathologic evolution of, 296
phenacetin in, 298
potassium bromid in, 298
poultices in, 298
purgation in, 85
purulent, paraspecific serotherapy in, 308
quinin in, 297
sodium in, 113, 116
revulsives in, 302
rheumatic, 305
aspirin in, 305
dionin in, 153
pilocarpin in, 306
salicylate in, 305
vapor baths in, 306
salicin in, 297
scopolamin in, 175, 299
sodium iodate in, 300
salicylate subconjunctivally, 312
injections in, 47
surgical treatment of, 317
symptoms, 297
syphilitic, alcohol dressings in, 309
atoxyl in, 304
dionin in, 310
hot compresses in, 309
leeches in, 309
mercurial poultices in, 309
mercury in, 303
mercury cyanid, 304, 308
mercury salicylarsenate in, 309
mercury subconjunctivally in, 309
potassium iodid in, 303
sodium iodate, in, 303
Wassermann's serodiagnosis in, 303
treatment, 297
tuberculin in, 64
tuberculous, air injection in, 307
Iritis, tuberculous aspiration in, 307
enucleation in, 308
guaiacol in, 306
tuberculin in, 306
vibratory massage in, 125
Iris, "tremulous," in subluxation of lens, 323
Iron in conjunctival irritation, 219
in pustular keratitis, 270
intravenously, 37
perchlorid, in hemorrhage of the vitreous, 363
Itrol in conjunctivitis, 188
in corneal ulcer, 189
in trachoma, 189
in wounds, 188
silver citrate, 188

J

Jequirity, in epithelioma of eyelids, 215
Jequiritol in leukomata, 251
in pannus, 251
crassus, 271
of cornea, 78
in xerosis, 252

K

Keloids, radium in, 112
Keratalgia, quinin in, 86
traumatic, air injections in, 49
Keratitis, adonidin in, 156
adrenalin in, 167
atropin in, 173, 269
Bier's method in, 95
collargol in, 279
deep, parenchymatous, interstitial, 280
dendritica, 255
dionin in, 154, 159
e lagophthalmos, 278
en bandelette, 278
faradic current in, 101
filamentary, autoplasty in, 276
galvanocautery in, 276
hydromineral treatment in, 122
injections of sterilized air in, 49
lavage in, 269
light-baths in, 96
macular, dionin in, 275
guaiacol in, 275
iodoform in, 275
mercurial lanolin in, 275
mercury cyanid in, 275

Keratitis, macular, quinin in, 275
sodium iodate, 275
syphilitic, 275
dionin in, 276
mercury cyanid subconjunctivally in, 276
mercury intravenously in, 276
massage in, 123
mercurial lanolin in, 134
neuroparalytic, 279
Pagenstecher's ointment in, 133
parenchymatous, 285
acoin in, 286
alcohol dressings in, 285
atoxyl in, 284
atropin in, 283, 285
dionin in, 285
guaiacol in, 284, 285
hot compresses in, 283
iodin trichlorid in, 283
light in, 97
mercurial injections in, 282
inunctions in 282
lanolin massage in, 284
poultice in, 283, 285
mercury cyanid injections in, 285
mercury salicyl-arsenate in, 286
salicylate, 285
saline baths in, 287
injections in, 284
sea-water injections in, 284, 285
sodium nitrate in, 284, 285
thyroid treatment in, 79
tuberculin in, 286
vapor douches in, 284
phlyctenular, air subconjunctivally in, 270
argyrol in, 269
dionin in, 270
guaiacol in, 267
saline injections in, 270
yellow ointment in, 269
protargol in, 269
punctata, descemetitis, 276
purgation in, 85
pustular, 269
arsenic in, 270
cod-liver oil in, 270
iodotannic preparations in, 270
iron in, 270
mercury bichlorid in, 271
potassium iodid in, 270
quinin in, 270
quinin in, 152
Keratitis, rheumatic parenchymatous, 281
stellata, 255
striated, 280
after extraction of cataract, 281
dionin in, 280
hot applications in, 280
massage in, 280
sodium chlorid in, 280
sodium iodate in, 280
sodium salicylate in, 280
superficial arborescent, 272
argyrol in, 273
fluorescin in, 273
iodin tincture in, 273
phenic acid in, 273
quinin in, 273
serotherapy antiinfective in, 273
sodium iodate in, 273
xeroform in, 273
suture of eyelids in, 279
transversalis, 278
treatment of, 269
tuberculin in, 64
vapor douches in, 91
vesicular, acoin in, 274
air subconjunctivally, 274
dionin in, 274
refractions in, 274
sodium iodate in, 274
vibratory massage in, 125
yellow ointment in, 269
Keratomalacia, 279
antisyphilitic treatment in, 279
collargol in, 279
dionin in, 279
euvaselin in, 279
iodoform in, 279
pilocarpin in, 279
Keratome in iridectomy, 353

L

Lacrimal canal, cocarenalin in anesthesia of, 168
glands, 203
removal in chronic epiphora, 205
probe, in excessive lacrimation, 204
sac, abscess of, 208
abscess of, galvanocautery in, 209
iodin tincture in, 209
mercurial poultices in, 208
thermocautery in, 208

Lacrimal sac, abscess of, Vienna paste in, 208
zinc chlorid in, 208
acoin and cocain in removal of, 151
extirpation of, adrenalin with stovain and cocain cain, 167
in dacryocystitis, 206, 207
suppuration of, antistreptococcus serum in, 59
Lacrimation, chronic, electrolysis in, 205
removal of lacrimal glands, 205
excessive, 204
argyrol in, 205
cocarenalin injection in, 204
incision of canaliculus, 205
oxygenated water injections in, 205
passing of lacrimal probe in, 204
style, 205
Lactic acid in corneal rodent ulcer, 278
Lamb's liver in hemeralopia, 80
Lautier's modification of cutireaction, 7
Lavage, by vapor douches, 91
friction of granulations, cocarenalin and sublimate, 168
in keratitis, 269
in infected wounds of eyeball, 262
Lavements, 193
Lead acetate, in eczema of eyelids, 211
in follicular conjunctivitis, 243
extract, in emphysema of eyelids, 214
glycerole after trachoma operation, 251
lotion, in blepharitis, 216, 217
compresses, in solar erythema, 211
Leber's disease, a retrobulbar neuritis, 398
Leeches after subconjunctival injections, 401
in acute iritis or iridocyclitis, 84
in albuminuric retinitis, 377
in diabetic retinitis, 378
in infected wounds of eyeball, 263
in choroidal hemorrhage, 389
in hemorrhagic retinitis, 374
in inflammatory glaucoma, 352
Leeches in iritis, 300
in myopic chorioretinitis, 84
in posterior sclerochoroiditis, 290
in relapsing central retinitis, 375
in retinal detachment, 389, 390
hemorrhage, 388
in retrobulbar neuritis, 397, 401
in sympathetic ophthalmia, 313
in syphilitic iritis, 309
Lenicet, in ophthalmia neonatorum, 237
Lens, dislocated, in extraction of cataract, 339
extract of, in lental opacities, 328
in senile cataract, 327
extraction, 323
in diseases of lens, 320
removal of cataractous, 320
in high myopia, 344
Lenticonus, 320
Leukocythemia, radiotherapy in, 16
serotherapy in, 16
Leukomata, dionin in, 159
jequiritol in, 251
massage in, 123
vapor douches in, 91
Light, in eye diseases, 96
baths in episcleritis, 293
in rheumatic iritis, 306
perception and projection, in cataract, 333
Linseed-meal poultice, 90
Lithium benzoate, in corneal opacities, 288
injections, in corneal leukomata, 46
salts, in marginal ulcer of cornea, 272
Local remedies, classification of, 136
Lugol's solution, in iridochoroiditis, 312
Lumbar puncture in optic neuritis, 406
in stasis optic neuritis, 38
Lupus of eyelids, guaiacol ointment in, 216
high-frequency current in, 216
phototherapy in, 216
radium in, 216
X-rays in, 216
radium in, 112
Lusemin, 145

Luxation of lens, 323
miotics in, 323
removal of lens in, 323
Lymphatism, treatment, 18
arsenic iodid in, 18
cod-liver oil in, 18
iodin in, 18
iron in, 18
quinin in, 18

M

Macula, disease of, 367
Macular choroiditis, saline injection in, 368
sodium chlorid injections in, 369
disease, subconjunctival injections in, 367
Magnetometer for diagnosis of foreign bodies, 108
Malarial affections, quinin in, 152
Malignant pustule of eyelids, 214
actual cautery in, 215
carbolic lotion injections in, 215
Marienbad waters in hemorrhagic retinitis, 377
Massage, action upon intraocular tension, 131
after discission of cataract, 123
in choroidal hemorrhage, 389
in chronic glaucoma, 357
in commotion retinæ, 382
in conjunctival irritation, 220
in detachment of retina, 124
in embolism of retina, 372
in episcleritis, 123
in glaucoma, 349
in inflammatory glaucoma, 352
in keratitis, 123
in leukomata, 123
in posterior sclerochoroiditis, 290
in retinal detachment, 389
in retinal injuries by light, 382
in striated keratitis, 281
in trachoma, 123
in tuberculosis of cornea and iris, 123
medicamentous, 123
of eyeball, 123
simple, 123
vibratory, 124
with mercurial lanolin in parenchymatous keratitis, 284
Massage, with mecurial lanolin, in scleritis and sclerokeratitis, 290
with powder in trachoma, 123, 244
Mechanotherapy, indications, 125
Mercurial injections, 28
and inunctions in exudative choroiditis, 389
in parenchymatous keratitis, 282
in retinal detachment, 389
in scleritis, 291
hypodermic, 24
in choroiditis, 370
in hydrophthalmos, 357
intravenous, 29
of biniodid, 28
of cyanid, 28
prevention of complications, 25
technic, 25
toxic effects of, 27
treatment of complications, 26
inunctions, action of, 73
application, 24
in Mikulicz's disease, 203
in osteoperiostitis, 197
in retrobulbar neuritis, 397
in sinus affections, 198
in specific neuritis, 403, 405
in sympathetic ophthalmitis, 21
in tenonitis, 198
in traumatic infections of eye, 21
in vitreous infections, 365
orbital, in relapsing central retinitis, 375
lanolin, in blepharitis, ciliary, 218
in blepharitis, parasitical, 218
in episcleritis, 134
in macular keratitis, 134, 275
in orbital periostitis, 197
in pericorneal infiltrations, 134
in spring catarrh, 134, 241
in sympathetic ophthalmia, 313
plasters, 94
poultice, 91
in abscess of lacrimal sac, 208
in dacryoadenitis, 203
in interstitial keratitis, 24
in optic neuritis, 402

Mercurial poultice, in parenchymatous keratitis, 283
in periostitis, 401
in relapsing central retinitis, 375
in syphilitic iritis, 309
Mercuric chlorid, 179
and cyanid in trachoma, 244
in corneal infection, 257
intravenous injections of, 33
irrigations in trachoma operation, 247
in pustular keratitis, 271
Mercury biniodid, in vitreous hemorrhage of the aged, 364
cyanid, as disinfectant, 20
after cataract extraction, 338
in chorioretinitis, 47
in conjunctival irritations, 220
in corneal infection, 256
in extraction of cataract, 335
in infected wounds of eyeball, 263
in infection after cataract extraction, 343
in iritis, 304
injections, acoin in, 150
hypodermic, 28
in detachment of retina due to iridochoroiditis, 390
in hypopyon keratitis, 47
in specific neuritis, 403
in sympathetic ophthalmia, 47, 313, 316
intravenous, 33
in macular keratitis, 275
in optic neuritis, 402
in osteoperiostitis, 197
in purulent ophthalmia, 231
in retinitis pigmentosa, 379
in spring catarrh, 241
in syphilis, 17
in syphilitic iritis, 308
intraocular injections of, 47
in zona ophthalmica, 274
subconjunctivally, in chorioretinitis, 400
in choroiditis, 400
in corneal infection, 257
in exudative choroiditis, 389
in infected wounds of eyeball, 262
in infections after cataract extraction, 343
Mercury cyanid, subconjunctivally, in relapsing central retinitis, 375
in retinal detachment, 389, 391
in retinitis proliferans, 376
prior to surgery in high myopia, 369
substitute for sublimate, 179
with dionin, after extraction of foreign body, 162
for diagnosis, 12
hemolytic power of, 21
in dacryocystitis, 209
in hard chancre of eyelids, 215
in iritis, 303
in paralysis of ocular muscles, 199
in posterior sclerochoroiditis, 290
in retinal detachment, 389
in syphilis, 19
intravenously, in chronic iridochoroiditis, 312
in optic atrophy, 409
in specific neuritis, 403
oxycyanid, 179
salicylarsenate, in iritis, 310
in parenchymatous keratitis, 286
in tertiary syphilis, 34
subconjunctivally, in iritis, 309
in suppurative choroiditis, 370
yellow oxide, preparation of, 133
Metallic ferments, in disorders of nutrition, 72
intravenously, 37
Methyl-atropin hydrobromid, 175
in iritis, 176
Methylene blue or violet, in corneal ulcer, 258
in epithelioma of eyelids, 215
Microscopic diagnosis, 3
Mikulicz's disease, 203
mercurial frictions in, 203
potassium iodid in, 203
radiotherapy in, 203
thiosinamin in, 203
Mille loop, in extraction of lens, 324
Milk diet, in albuminuria, 85
in albuminuric retinitis, 377
in arteriosclerosis, 16
in gout, 85
in marginal corneal ulcer, 272

Milk, in burns of cornea by lime, 268
instillations, in pemphigus, 275
in xerosis of cornea, 279
Mineral waters in diabetic retinitis, 378
Miotics, 177
in glaucoma, 128
chronic, 355, 356
in iritis, 178
in seclusion pupillæ, 317
in subluxation of lens, 323
Moist compresses, in ocular infections, 90
dressings, in eczema of eyelids, 24
heat, new appliances, 91
Morphin, action of, 155
and scopolamin injections, for anesthesia, 137
as analgesic, 147
injections, 153
before iridectomy, 354
in hemorrhage in cataract extraction, 340
in iritis, 298
in retinal detachment, 390
Mouches volantes, 363
in retinal detachment, 384
Mucocele, 209
Mustard foot-baths, in albuminuric retinitis, 377
Mydriasis, augmented by dionin, 174
Mydriatics, 173
Mydrin, 176
Myopia traumatic, in wounds of the lens, 322
Myopic choroiditis, sublimate subconjunctivally in, 368
detachment of retina, 388

N

Narcotics after operation, 80
Needlings of lens followed by vibratory massage, 125
Neoplasms, radiotherapy in, 110
superficial, radium in, 112
X-rays in, 109
Neisser's exploratory puncture, in optic neuritis, 406
Neuralgia, antipyretics in, 86
massage in, 132
radium in, 117
Neuralgic affections, quinin in, 152
Neuritis, infective, subconjunctival injections in, 398
of pregnancy, 398
Neuritis, radium in, 116
specific, 402
complications of, 402
mercurial inunctions in, 403
mercury cyanid injections in, 403
pilocarpin in, 403
potassium iodid in, 404, 405
subconjunctival injections in, 403
sulphur baths in, 403
tuberculous, guaiacolated cod-liver oil in, 406
treatment of, 406
Neurochorioretinitis, 375
Nevus, bipolar electrolysis in, 103
galvanocautery in, 105
radium in, 113
Nitric acid lotions in purulent ophthalmia, 230
Nitrites in arteriosclerosis, 16
Normal salt solution in infections, 73
Novocain, 144
in enucleation of eye, 144
Nucleinic acid and nucleinates, in infections, 73

O

Ocular complications of albuminuria, 16
of arteriosclerosis, 15
treatment, 15
of diabetes, 16
of lymphatism, 18
pain, alcohol dressings in, 153
dionin in, 86
hot compresses in, 86
morphin, 86
Oil in burns of cornea by lime, 268
Oily collyria, 134
Ointments, 133
Opacities of lens, potassium iodid in, 47
Ophthalmia, Buller's shield in, 235
neonatorum, 226
argyrol in, 238
beef-serum in, 237
dionin in, 229
hot compresses in, 229
lenicet in, 237
potassium permanganate in, 229
prophylaxis, 237
protargol, 229
silver nitrate in, 227
purulent, 226
argyrol in, 185
arthritis in, 233

Ophthalmia, purulent, corneal complications of, 233
dionin in, 161
iritis in, 233
protargolage in, 185
silver nitrate in, 180, 186
Ophthalmoblennorrhea, 225
argyrol in, 182
collargol in, 192, 193
gonococcal in adult, 233
argyrol in, 234
protargol in, 234
protection of sound eye in, 234
Ophthalmo-reaction, Calmette, 8
technic, 9
Wolff-Eissner, 8
Opiates in diabetic retinitis, 378
Opotherapy, 78
Opsonic index, 51
determination of, 67
theory, 66
Optic atrophy, 408
brucin, 409
electricity, 409
hydromineral treatment in, 121
in oxycephaly, 410
mercury intravenously in, 409
pituitary gland in, 409
spermin and testicular extract in, 80
strychnin in, 87, 409
thyroid gland in, 79, 409
neuritis in diseases of the orbit, 401
hydromineral treatment in, 122
guaiacol inunctions in, 13
indicative of intracranial malady, 404
lumbar puncture in, 38
mercurial lanolin poultices in, 401
mercury cyanid injections, 402
Neisser's exploratory puncture in, 408
potassium iodid in, 402
seton in, 83
surgical treatment of, 406
Optocine, in diseases of retina, 80
Orbital neuralgia, radium in, 116
periostitis, 197
mercurial lanolin in, 197
Orbital tumor, 401
Organotherapy by adrenalin, 78
in cataract, 330
in lental opacities, 328
in senile cataract, 328
Orthoform in burns, 146, 151
of cornea, 266
in zona ophthalmica, 274
Osteoperiostitis, mercurial inunction in, 197
Oxycephaly, optic atrophy in, 410
Oxydases, action of, 72
Oxygenated water, in dacryocystitis, 206
injections, in dacryocystitis, 207
in excessive lacrimation, 205

P

Pagenstecher's ointment, 133
Pannus, 248
adrenalin in, 168
crassus, jequiritol in, 271
jequiritol in, 251
of cornea, jequiritol in, 78
strumous, 271
trachomatous, dionin in, 160
Panophthalmitis, dionin in, 154
enucleation in, 316
evisceration by thermocautery, 316
Paracentesis in corneal ulcer, 259
in high myopia, 345
in iritis, 300
in retinal embolism, 372, 373
in secondary glaucoma, 357
Paraffin injections in exophthalmos, 198
Paraldehyde in iritis, 298
Paralysis of ocular muscles, 199
advancement, 199
alcohol dressings, 199
electricity, 199
hydromineral treatment in, 121
mercury, 199
sodium salicylate, 199
tenotomy, 200
vibratory massage in, 125
Parinaud's infective conjunctivitis, 242
argyrol in, 242
guaiacol in, 242
iodoform in, 242
Paraspecific serotherapy, 52, 58, 61
combined with galvanocautery, 104
in abscess of orbit, 197
in erysipelas of eyelids, 212
in infective exophthalmos, 198
in infective complications of operation for cataract, 62
in purulent iritis, 308

Paraspecific serotherapy, in sympathetic ophthalmia, 315
Pemphigus of conjunctiva, 252
corneal lesions in, 275
Pericorneal infiltrations, mercurial lanolin in, 134
Periostitis, mercurial lanolin poultice in, 461
potassium iodid in, 402
Peronin, in trachoma, 155
massage, in trachoma, 244
Pflugk's experiments with naphthalin cataract, 328
Phagocytosis, 51, 66
Phakolysis, 344
Phenacetin, 86, 152
in episcleritis 291
in inflammatory glaucoma, 352
in iritis, 297
in retinal electrocution, 382
in trigeminal neuralgia, 100
Phenic acid in arborescent keratitis, 273
in corneal infection, 261
in corneal ulcer, 259
in corneal rodent ulcer, 278
Phlyctenulæ, etiology of, 270
Phlyctenular conjunctivitis, 223
keratitis, 255, 269
Photophobia in retinal electrocution, 381
Phototherapy, indications, 96
in tuberculous ulcerations of eyelids, 215
methods, 96
Physical agents, 87
Physiologic serum in detachment of retina, 386
Physostigmin in cataract extraction, 321
oily solutions preferable, 134
Picric acid in burns of cornea, 266
by caustics, 268
Pilocarpin, 178
contraindicated in intravenous injection, 37
in albuminuric retinitis, 377
in commotion retinæ, 382
in dacryoadenitis, 203
in detachment of retina, 383, 386
in episcleritis, 293
in glaucoma, 164, 349, 350
chronic, 357
in hydrophthalmos, 357
in inflammatory glaucoma, 352
in intraocular hemorrhage, 364
Pilocarpin injections, in chronic iridochoroiditis, 312
in malignant glaucoma, 360
in syphilis, 36
in keratomalacia, 279
in relapsing central retinitis, 376
in retinal injuries by light, 382
in retinitis pigmentosa, 379
in retrobulbar neuritis, 399
in rheumatic iritis, 306
in specific neuritis, 403
in subluxation of lens, 323
in sympathetic ophthalmia, 315, 316
in wounds of the lens, 322
sweats, in toxic amblyopia, 83
Pinguecula, 252
Piperazin, diuretic, 86
in glaucoma, 349
Pituitary gland in optic atrophy, 409
Plasters, carbolic, 95
mercurial, 94
salicylic, 95
Posterior sclerochoroiditis, leeches in, 290
massage in, 290
mercurials in, 290
mustard foot-baths in, 290
refraction in, 290
revulsions in, 290
sclerotomy, 352
Potassium bromid, 86
in glaucoma, 350
in iritis, 298
in retinal electrocution, 381
chlorate, in epithelioma of eyelids, 145
iodid, in blennorrhagic iritis, 305
in cataract, 328
in choroiditis, 370
in connection with diaphoresis, 82
in corneal opacities, 288
in dacryocystitis, 209
in detachment of retina, 383
in exophthalmos, 198
in incipient cataract, 329
in iritis, 303
in Mikulicz's disease, 203
in optic neuritis, 402
in periostitis, 402
in pustular keratitis, 270
in relapsing central retinitis, 376
in specific neuritis, 404, 405
in syphilis, 36

Potassium iodid, in vitreous hemorrhage of the aged, 364
subconjunctivally in cataract, 33
in infiltrations of sclera, 48
in lenticular opacities, 47
nitrate, diuretic, 85
permanganate in corneal ulcer, 239
in dacryocystitis, 206
in purulent conjunctivitis, 226
Poultice, 90
in styes, 214
Powders, 133
Prelacrimal tumor, 209
Preliminary iridectomy in cataract, 332
indications for, 332
Pressure massage of Domec, 126
in retinal embolism, 132
Priestnitz dressing, 93
Probing in blepharospasm, 202
Prodromal glaucoma, aspirin in, 350
dionin in, 350
eserin in, 350
iridectomy in, 351
pilocarpin in, 350
quinin in, 350
sodium salicylate in, 350
valerian in, 350
Prolapse of iris, adrenalin in, 341
autoplasty in, 341
after extracting of cataract, 346
cocain in, 341
eserin in, 341
serotherapy in, 341
Protargol in conjunctivitis, 181, 224
in dacryocystitis purulent, 207
in extraction of cataract, 335
in gonococcal ophthalmia, 234
in granulous conjunctivitis, 244
in keratitis, 269
in purulent conjunctivitis, 226
insufflation, 133
preparation of solutions, 181
to prevent purulent ophthalmia, 237
Protargolage in blepharitis, ciliary, 218
marginal, 217
in corneal infection, 256
in marginal corneal ulcer, 272
in prurigo of eyelids, 211
in purulent ophthalmia, 185
Protochlorid of mercury in iritis, 303
Prurigo, cocarenalin ointment, 211
Pterygium, 252
Ptosis, special spectacles in, 200
Punctures in retinal detachment, 387, 392
Purgation after operations, 85
after wounds, 85
in acute affections of iris and ciliary body, 85
in blepharitis, 85
calomel in, 85
castor oil, 85
in chronic conjunctivitis, 85
in keratitis, 85
in ocular congestions, 85
Purgatives and laxatives, in anemic conditions, 84
in vitreous hemorrhages, 84
Pyocyanase, 53
auxiliary to serotherapy, 74
in corneal ulcers, 239
in gonococcal infection, 75
Pyramidon, 86
in retinal electrocution, 382
in trigeminal neuralgia, 200
in zona ophthalmica, 213, 273
Pyramidal cataract, 320
Pyrenol, 152

Q

Quinin and quinquina in hemorrhage of the vitreous, 363
in arborescent keratitis, 273
in conjunctival irritation, 219
in exophthalmic goiter, 198
in glaucoma, 348, 350
chronic, 357
in herpes febrilis of cornea, 273
in inflammatory glaucoma, 352
in iritis, 297
injections in fevers, 37
in syphilis, 37
in keratalgia, 86
in keratitis, 152
in lymphatism, 18
in macular keratitis, 275
in malarial affections, 152
in marginal corneal ulcer, 272
in neuralgic affections, 152
in pustular keratitis, 270
in retinal electrocution, 381
in trigeminal neuralgia, 86, 200
in zona ophthalmica, 213, 274

Quinquina in hemorrhage of vitreous, 363

R

Rabbit's vitreous, injection of, in detachment of retina, 383, 385
Rachiostovainization, 142
Radioscopy for diagnosis of foreign bodies, 108
Radium, 112
in blepharospasm, 201
in chalazion, 113, 214
in chancre of eyelids, 112
in cicatrices, 112
in corneal ulcer, 113
in epithelioma of eyelids, 116, 215
in exophthalmic goiter, 199
in facial paralysis, 116
in hard chancre of eyelids, 215
in iridocyclitis, 116
in iritis, 113, 116
in keloids, 112
in leukocythemia, 16
in lupus of eyelids, 112, 216
in malignant tumors, 110
in Mikulicz's disease, 203
in neoplasms, 110
in nervous affections, 116
in neuralgia, 116
in nevi, 113
in retinal electrocution, 382
in tabes, 117
in trachoma, 113, 251
in trigeminal neuralgia, 200
in uveitis, 113
in xanthelasma of eyelids, 213
mode of application, 111
Raw meat in hemophilia, 81
Refraction in blepharitis, 216
in congenital aphakia, 320
in conjunctival irritation, 219
in excessive lacrimation, 204
in posterior sclerochoroiditis, 290
in subluxation of lens, 323
in vesicular keratitis, 275
Refractive errors, pressure-massage of Domec in, 128
Removal of crystalline lens, dionin in, 345
by extraction, 345
by paracentesis, 345
by repeated discissions, 345
sodium iodate in, 345
Resection in trachoma, 246
in sympathetic ophthalmia, 315
Resorcin in parasitical blepharitis, 218
Retina, anemia of, 371
complications of diseases of, 374
detachment, 383
acoin in, 383
aspiration in, 384
atropin in, 391
blood-letting in, 383
cautery in, 387, 391
compressive bandage in, 383, 390
Deutschmann's method, 385
diaphoresis in, 383, 387, 390
dionin in, 383
discission of, 383
dorsal decubitus in, 387, 390
electrolysis in, 383, 384, 386
enucleation in, 389
eserin in, 383
gelatin in, 384
idiopathic, 390
ignipuncture in, 383
iodids in, 389
iodin injections in, 383, 384
iridectomy in, 383
Leber's method, 386
leeches in, 389
massage in, 389
mercurial injections and inunctions in, 389
mercury cyanid subconjunctivally in, 389
morphin in, 390
myopic, 388
physiologic serum in, 386
pilocarpin in, 383, 390
potassium iodid in, 383
punctures in, 383, 387
rabbit's vitreous in, 383
secondary, 389
sodium chlorid subconjunctivally in, 384, 389, 390
sodium salicylate in, 387
sodium sulphate in, 384
subconjunctival injections in, 383, 384, 390
traumatic, 387
treatment of types of, 390
types of, 390
diseases of, 370
diaphoretics in, 82
optocine in, 80
inadequate blood supply of, 371
Retinal electrocution, 380
acoin in, 382
adrenalin in, 382

Retinal electrocution, antipyrin in, 382
cocain in, 382
cold compresses in, 381
dionin in, 382
electricity in, 382
hot baths in, 381
phenacetin in, 382
pyramidin in, 382
quinin in, 381
radium in, 382
valerian in, 381
treatment of, 381
embolism, pressure-massage in, 132
injuries by light, dionin in, 382
electricity in, 382
massage in, 382
pilocarpin in, 382
strychnin in, 382
opotherapy, by Dor's ciliary extract, 379
by Doyne's "optocine," 379
in retinitis pigmentosa, 379
phototraumatism, 380
Retinitis albuminuric, 377
diet in, 377
intestinal derivatives in, 377
leeches in, 377
milk diet in, 377
mustard foot-baths in, 377
pilocarpin in, 377
serotherapy in, 378
sudorifics in, 377
atrophic macular, alkaline waters in, 377
sodium iodid in, 377
diabetic, alkalines in, 378
antipyrin in, 378
diet in, 378
leeches in, 378
mineral waters in, 378
opiates in, 378
dionin in, 160
gravidic, 378
hemorrhagic, 373
calcium chlorid in, 376
gelatin-serum in, 376
etiology of, 374
leeches in, 374, 388
Marienbad waters in, 376
mercury cyanid in, 376
sodium iodid in, 374, 376
subconjunctival injections in, 376
Truneseck's serum in, 374
leukemic, arsenic in, 378
colloidal metals in, 378
serotherapy in, 378
sulphur in, 378
Retinitis leukemic, X-rays in, 378
pigmentosa, 379
constant current in, 379
extract of uveal tract in, 80
intravenous injections in, 379
mercury cyanid in, 379
pilocarpin injections in, 379
retinal opotherapy in, 379
sine pigmento, 379
sodium chlorid in, 379
strychnin in, 379
subconjunctival injections in, 379
proliferans, 376
calcium chlorid in, 376
gelatin-serum in, 376
mercury cyanid in, 376
subconjunctival injections in, 376
relapsing central, of von Graefe, 375
alcohol dressings in, 375
calomel in, 376
dionin in, 375
gray oil in, 376
hydrotherapy in, 375
intravenous injections in, 375
leeches in, 375
mercury cyanid in, 375
mercurial orbital inunctions in, 375
mercurial poultices in, 375
pilocarpin in, 376
potassium iodid in, 376
subconjunctival inunctions in, 375
septic metastatic, 378
Retrobulbar neuritis, 397
blood-letting in, 397
constant current in, 399
dionin in, 160, 161
etiology of, 396
hemolytic serum in, 397
infective, subconjunctival injections, in, 400
leeches in, 397, 401
mercurial inunctions in, 397
pathogeny of, 394
pilocarpin in, 399
retrobulbar injections in, 297, 398
strychnin in, 399
subconjunctival injections in, 398, 399
traumatic, 396
injections in, 396
treatment of, 397
toxic, 398

Revulsives, action of, 94
and derivatives, 83
in inflammation, 94
Rheumatic affections of eye, antistreptoccus serum in, 59
aspirin in, 152
dry heat in, 92
medicamentous electrolysis in, 104
sodium salicylate in, 152
injections in, 36
thyroid treatment in, 79
treatment of, 306
Rhus toxicodendron, in marginal corneal ulcer, 272
Rodent ulcer of cornea, galvanocautery in, 278
iodin, tincture of, 278
lactic acid in, 278
phenic acid in, 278
Roemer's antipneumococcic serum, 56
jequiritol serum, 77
Roux-Behring serum, 52
in conjunctivitis, 239
in diphtheritic conjunctivitis, 52, 223
dose, 54
in hemorrhage of the vitreous, 364
in nondiphtheritic infections, 54
technic, 54

S

Saemisch's section, 55
transfixion in corneal ulcer, 259
Salicin in episcleritis, 292
in iritis, 297
in marginal ulcer of cornea, 271
in scleritis and sclerokeratitis, 290
Salicylated alcohol dressings, in scleritis, 291
Salicylic alcohol in tenonitis, 197
plaster, 95
Saline baths in parenchymatous keratitis, 287
in strumous pannus, 271
irrigations in extraction of cataract, 321
Savonnage, 185, 187
in conjunctivitis, 224
Sclera, infiltrations of, potassium iodid in, 48
Scleral puncture in detachment of retina, 383
Scleritis and sclerokeratitis, adrenalin in, 290
massage with mercurial lanolin in, 290
salicin in, 290
galvanic current in, 101
galvanocautery in, 105
guaiacol in, 291
mercurial injections and inunctions in, 291
rheumatic, hydromineral treatment in, 121
salicylated alcohol dressings in, 291
sodium salicylate in, 291
vibratory massage in, 125
X-rays in, 110
Sclerosing keratitis, 293
Sclerotomy, in malignant glaucoma, 360
Scopolamin, 174
in iritis, 299
Scotoma in retrobulbar neuritis, 394, 400
Sea-water injections, in parenchymatous keratitis, 284
Seclusion pupillæ, iridectomy in, 317
miotics in, 317
Secondary cataract, 344
glaucoma, dionin, 358
iridectomy in, 358
miotics, 358
paracentesis in, 357
sodium iodate in, 358
subconjunctival injections in, 357
infection, subconjunctival injections in, 41
Senile cataract, 327
extract of lens in, 327
Serotherapy, 51
for prophylaxis, 63
general remarks in, 77
in albuminuric retinitis, 378
in arborescent keratitis, 273
in corneal infection, 257
in corneal ulcer, 259
in diphtheritic conjunctivitis, 223
in exophthalmic goiter, 199
in hemorrhagic affections of eye, 74
in herpes febrilis of cornea, 273
in infection after extraction of cataract, 330, 343
in infective corneal ulcers, 260
in leukemic retinitis, 378
in leukocythemia, 16

Serotherapy, in vitreous infections, 365
in zona ophthalmica, 213, 273
orally, 63
paraspecific, 52, 58
specific, 58
in sympathetic ophthalmia, 315
Serpiginous ulcer of cornea, 254
antipneumococcic serum in, 55
Serum, by rectum, 77
diagnosis, 3, 6
of syphilis, 9
of tuberculosis, 6
Wassermann and Neisser, 10
hemolytic, in vitreous hemorrhages, 75
horse's, 73
compared with paraspecific, 74
in infectious, 73
methods of use, 77
normal, in hemophilia, 74
oral administration of, 63
physiologic, in retinal detachment, 387
paraspecific, compared with warmed horse's, 74
Roemer's jequirital, 77
sickness, 54, 58, 77
subconjunctivally, 50
Seton in optic neuritis, 83
Sideroscope for diagnosis of foreign bodies, 107
Silver compounds, 179
foil in burns of cornea, 267
inunctions in traumatic infections, 21
in sympathetic ophthalmitis, 21
nitrate, 180
in conjunctivitis, 180
in granulous conjunctivitis, 244
in making conjunctival flap, 263
in ophthalmia neonatorum, 227
in purulent ophthalmia, 180, 186
to prevent purulent ophthalmia, 237
salts, merits and modes of application of, 184
in granulous conjunctivitis, 244
sulphophenate, 188
Sinuses, affections of, collargol in, 198
mercurial inunctions in, 198
sodium salicylate in, 198
Sinusitis, 401
Snellen loop in extraction of cataract, 339
in extraction of lens, 324
Snellen's shield, 236
Sodium benzoate in marginal ulcer of cornea, 272
bicarbonate, 85
in marginal corneal ulcer, 272
chlorid injections, acoin in, 149
in corneal leukomata, 46
in embolism of retina, 372
in interstitial keratitis, 46
in hypopyon keratitis, 47
in macular choroiditis, 368
in phlyctenular keratitis, 270
in purulent ophthalmia, 230
in retinal detachment, 384, 390
in striated keratitis, 280
subconjunctivally, in cataract, 328
in choroidal hemorrhage, 389, 390
in chorioretinitis, 400
in choroiditis, 400
in contusion of eyeball, 388
in corneal infection, 257
in corneal infiltration, 281
in infections after cataract extraction, 343
in parenchymatous keratitis, 284
in retinal detachment, 389
in retinitis pigmentosa, 379
in traumatic mesokeratitis, 281
hyposulphite in conjunctival irritation, 220
in corneal opacities, 288
iodate, in arborescent keratitis, 273
in corneal infections, 257
in choroiditis, 368
in extraction of cataract, 322
in glaucoma, 48
in glaucomatous complications of extraction of cataract, 342

Sodium iodate in iritis, 300
in macular keratitis, 275
in striated keratitis, 280
intravenously and subconjunctivally, in embolism of retina, 373
in vesicular keratitis, 274
subconjunctivally in iritis, 309
in malignant glaucoma, 360
in removal of lens, 345
in secondary glaucoma, 358
iodid in atrophic macular retinitis, 377
in hemorrhagic retinitis, 374, 376
in incipient cataract, 329
in marginal corneal ulcer, 272
nitrate in parenchymatous keratitis, 284
injections in retinal embolism, 372
salicylate, for diagnosis, 12
in blennorrhagic iritis, 305
in complications of purulent ophthalmia, 233
in connection with diaphoresis, 82
in episcleritis, 291
in exophthalmic goiter, 198
in glaucoma, 348
in inflammatory glaucoma, 352
injections in episcleritis, 47
in iritis, 47
in rheumatism, 36
in marginal corneal ulcer, 272
in paralysis of ocular muscles, 199
in prodromal glaucoma, 350
in retinal detachment, 387
in rheumatic affections, 152
in scleritis, 291
in sinus affections, 198
in striated keratitis, 280
in sympathetic ophthalmia, 315
in tenonitis, 198
in retinal detachment, 384
subconjunctivally, in iritis, 312
Solar erythema, lead lotion in, 211
powdered starch in, 211
Somnoform, 137
Sophol, 188
to prevent ophthalmia neonatorum, 238
Spermin and testicular extract, in exophthalmic goiter, 80
in ocular asthenopia, 80
in optic atrophy, 80
Spirochæta, demonstration of, 4
in sections, 5
of Schaudinn, 4, 17
Spring catarrh, 240
adrenalin in, 168, 241
guaiacol in, 241
mercurial lanolin in, 241
mercury cyanid in, 241
X-rays in, 110, 241
Staphylase in chronic dacryocystitis, 71
Staphylococci in conjunctivitis, 222
Staphyloma of cornea, 289
autoplasty in, 289
Critchett's operation in, 289
Starch, powdered, in solar erythema, 211
Stasis hyperemia, 95
neuritis, 404
Steam in application of moist heat, 91
Stilling's knife in dacryocystitis, 208
Stimulants, 87
Stomatitis resulting from mercurial injections, 25
Stovain, action of, 142
in corneal ulcer, 259
in operations on eyelids, 144
in strabismus operations, 144
Strabismus operations, acoin and cocain in, 151
adrenalin with stovain and cocain, 167
cocain in, 139
stovain in, 143
treatment of, 199
Streptococci in conjunctivitis, 222
Strophanthus hispidus in glaucoma, 350
in chronic glaucoma, 357
Strumous pannus, adrenalin in, 271
calomel in, 271
dionin in, 271
fluorescin in, 271
salt baths in, 271
yellow ointment, 271
Strychnin contraindicated in intravenous injection, 37
in amblyopia, 87
in optic atrophy 87, 409

Strychnin in retinal injuries by light, 382
in retinitis pigmentosa, 379
in retrobulbar neuritis, 399
Styes, Bier's method in, 95
incision of, 214
poultices in, 214
Style in excessive lacrimation, 205
Subconjunctival ecchymoses, dionin in, 158
infiltrations, dionin in, 160
injections, action, 43
contraindications, 43
dionin in connection with, 159
in central choroiditis, 368
in chorioretinitis, 41, 400
in choroiditis, 41, 367, 400
in corneal infiltration, 255
in corneal infection, 261
in corneal ulcer, 41, 259
indications, 46
in diseases of the macula, 367
in embolism of retina, 372
in episcleritis, 290
in infective neuritis, 398
in iridochoroiditis, 311
in iritis, syphilitic, 309
in phlyctenular keratitis, 270
in relapsing central retinitis, 375
in retinal detachment, 383, 384, 390
in retinitis pigmentosa, 379
in retrobulbar neuritis, 42, 399, 400
in secondary glaucoma, 357
in secondary infections, 41
in specific neuritis, 403
in striated keratitis, 280, 281
in sympathetic ophthalmia, 41, 315, 316
intraocularly in vitreous infections, 365
in vitreous infections, 365
of atropin, 40
of guaiacol, 13, 49
of mercury cyanid, 23, 47
of potassium iodid, 48
of serums, 49
of sodium chlorid, 46
of sodium iodate, 48
of sodium salicylate, 47
of sterilized air, 48
of sublimate, 40, 368
technic, 45
Subluxation in wounds of the lens, 322
of lens, eserin in, 323
iridectomy in, 323
pilocarpin in, 323
Sudorifics in albuminuric retinitis, 377
Sulphonal, soporific, 86
Sulphur in acne rosacea of eyelids, 212
baths, in specific neuritis, 403
in leukemic retinitis, 378
Sulphuric acid in eczema of lids, 211
lemonade in hemorrhage of the vitreous, 363
Sun-bath, action of, 99
indications, 99
Sun-light in local tuberculosis, 99
in ocular suppuration, 230
in wounds, 99
Sun's rays as means of phototherapy, 99
localization of, 100
Suture of eyelids in keratitis, 279
Suturing of lids in exophthalmic goiter, 199
Sympathectomy, 356
Sympathetic glaucoma, 359
iridectomy in, 359
Sympathetic ophthalmia, 313
antiinfective serotheraphy in, 316
atropin in, 314
autoplasty in, 316
cocain in, 316
conservative treatment in, 316
dionin in, 316
enucleation in, 313, 315
extract of ciliary body in, 80
galvanocautery in, 316
iodoform in, 316
leeches in, 313
mercurial inunctions in, 21, 313, 316
mercury cyanid injections in, 47, 316
pilocarpin in, 315, 316
serotherapy, paraspecific, in, 315
sodium salicylate in, 315, 316
Synchysis, 365
Synechiæ, posterior, rupture of, 318
Syphilis, atoxyl in, 17, 35
arsacetin in, 17, 35
biniodid in, 29, 33
cyanid in, 29, 33
enesol in, 34
gray oil in, 26

Syphilis, iodin injections in, 36
mercurial treatment of, 19
mercury cyanid injections, 17
pilocarpin injections in, 36
potassium iodid in, 36
sero-diagnosis, 9
Syphilitic affections of the eye, treatment, 17

T

Tabes, intrarachidian injection of colloidal mercury in, 38
radium in, 177
Tannin in conjunctival irritations, 219
Tar ointment in eczema of eyelids, 211
Tattooing of cornea, 289
Tenonitis, collargol in, 198
mercurial inunctions in, 198
salicylic alcohol in, 197
sodium salicylate in, 197
Tenotomy in exophthalmos, 198
in paralysis of ocular muscles, 200
Terson's curettage in dacryocystitis, 208
Thalianin as bacteriolytic agent, 75
Therapeutic diagnosis, 3, 12
by guaiacol, 13
by mercury, 12
by sodium salicylate, 12
Thermocautery in abscess of lacrimal sac, 208
in panophthalmitis, 316
in trachoma, 246
Thermoeorophore, as dry heat, 92
in applying moist heat, 91
Thermotherapy, 97
Thiosinamin in choroiditis, 370
in corneal opacities, 288
in Mikulicz's disease, 203
Thrombosis of the retinal arteries, 393
of retinal veins, 373
blood-letting in, 373
Thyroid gland in optic atrophy, 409
Thyroid, powdered, in intraocular hemorrhage, 365
Thyroid treatment in exophthalmic goiter, 79
in intraocular hemorrhage, 79
in optic atrophy, 79
in parenchymatous keratitis, 79
in rheumatism, 57
Thyroidin in intraocular hemorrhage, 365
Tourneur's leukolytic preparation of iodin in iridochoroiditis, 312
Trachoma, 242
Buller's shield in, 235
collargol in, 193
copper sulphate in, 244
Finsen's phototherapy in, 116
galvanocautery in, 105
hydriodic acid in, 245
itrol in, 189
massage in, 123, 244
mercury bichlorid, 244
mercury cyanid, 244
operation for, chloroform anesthesia in, 248
cocain anesthesia in, 246
peronin in, 155
radium in, 113, 251
surgical treatment of, 245
X-rays in, 110
Traumatic infections of the eye, mercurial inunctions in, 21
colloidal silver in, 21
mesokeratitis, 281
myopia, treatment of, 382
Traumatism of eye, antitetanic serum in, 58
Trephining in optic neuritis, 406
Trichiasis, electrolysis in, 102
Trigeminal neuralgia, alcohol injections in, 200
antipyrin in, 200
electricity in, 200
electrolysis, medicamentous, in, 200
phenacetin in, 200
pyramidon in, 200
quinin in, 86, 200
radium in, 200
surgical treatment of, 200
Triple-bladed knife in operation for trachoma, 249
Tropacocain, 142
Truneseck's serum in hemorrhagic retinitis, 374
Tuberculin in episcleritis, 294
injections, 6
subconjunctival, 69
in parenchymatous keratitis, 286
intravenously, 37
in tuberculosis of conjunctiva, 242
in tuberculous iritis, 306
O. or T. O., 68
orally, 71
T. R., 68

Tuberculin, T. R., dose, 68
dilution of, 68
preservation of, 68
subconjunctival injectionof, 69
Tuberculins in tuberculous iritis, 64
for diagnosis, 64
in tuberculous keratitis, 64
Tuberculosis, intracranial, guaiacolated cod-liver oil in, 406
of conjunctiva, guaiacol in, 241
iodoform in, 241
tuberculin in, 242
X-rays in, 110
of cornea and iris, massage in, 123
of eyeball, guaiacol in, 285
sero-diagnosis, 6
sun-light in, 99
Tuberculous ulcerations of eyelids, cod-liver oil in, 215
galvanocautery in, 215
guaiacol in, 215
iodoform in, 215
iodotannic preparations in, 215
lupus, 215
phototherapy in, 215
radium in, 216
X-rays and high-frequency currents in, 216
Tumors, malignant, radiotherapy in, 110
of eyelids, galvanocautery in, 105
of the hypophysis, 409
Turpeth mineral in acne rosacea of cornea, 276
of eyelids, 212
in ciliary blepharitis, 218

U

Ultraviolet rays, localization of' 100
Uremic amaurosis, 371
Uveitis, radium in, 113

V

Vaccination, false, 7
Vaccins in ocular infections, 55, 60
Valerian, in chronic glaucoma, 357
in conjunctival irritation, 219
in exophthalmic goiter, 198
in glaucoma, 350
in retinal electrocution, 381
in zona ophthalmica, 213
Valerianates, zinc and ammonia, 87
Validol, antineurotic, 87
Vapor baths, 82
in episcleritis, 273
in rheumatic iritis, 306
burns of cornea, 267
douches in blepharitis, 216
in chronic conjunctivitis, 91
in corneal opacities, 288
in eczema of eyelids, 211
in keratitis, 91
in leukomata, 91
in parenchymatous keratitis, 284
in spring catarrh, 91
Vaporizations in xerosis of cornea, 279
Ventricular puncture in optic neuritis, 406
Vertebral trepanation in optic neuritis, 406
Vibratory massage, in choroiditis, 126
in corneal opacities, 126
in episcleritis, 125
in extractions of cataract, 321
in eye diseases, 124
in glaucoma, 125
in iridochoroiditis, 125
in iritis, 125
in keratitis, 125
in needlings of lens, 125
in paralysis of eye muscles, 125
in scleritis, 125
in traumatic cataract, 125
in wounds of the lens, 322
Vienna paste in abscess of lacrimal sac, 208
Vitreous body of rabbits, in detached retina, 80
hemorrhage, hemolytic serum in, 75
of adolescents, 363
of the aged, calcium chlorid in, 364
electrolysis in, 364
gelatin in, 364
hemolytic serum in, 364
mercury biniodid in, 364
potassium iodid in, 364
purgatives and laxatives in, 84
infections, 365
iodoform pencils in, 365
mercurial inunctions in, 365
serotherapy in, 365
subconjunctival injections in, 365

Vitreous infections, sublimate injections intraocularly, 365
loss in extraction of cataract, 339
opacities, diaphoretics in, 82
dionin in, 160
Volkmann's magnet, 107
Von Pirquet, cuti-reaction, 3, 7

W

Warm packs, 82
Wassermann's sero-diagnosis in syphilitic iritis, 303
sero-reaction, 10
Wet cupping, 84
Wine in hemorrhage of the vitreous, 363
Wounds, airol insufflation in, 133
and infections of cornea and sclera, 254
collargol in, 193
itrol in, 188
of eyeball, antitetanic serum in, 58
Behring serum in, 62
of eyelids, antitetanic serum in, 214
of the ciliary region, 264
sequels of, 265
of the crystalline lens, 322
astigmatism in, 322
myopia in, 322
pilocarpin in, 322
vibratory massage in, 322
protargol insufflation, 133
xeroform insufflation, 133
sun-light in, 99

X

Xanthelasma, bipolar electrolysis in, 103
of eyelids, electrolysis in, 213
excision, 213
radium, 213
Xeroform, in arborescent keratitis, 273
in corneal infection, 256
insufflation in, 133
in zona ophthalmica, 274
Xerosis of conjunctiva, autoplasties in, 252
dionin in, 252
jequiritol in, 252
of cornea, dionin in, 279
glycerin in, 279
guaiacol in, 279
milk in, 279
vaporizations in, 279
xerophthalmia in, 279
X-rays, action, 109
indications, 109
in epithelioma of eyelids, 215
in leukemic retinitis, 378
in lupus of eyelids, 216
in neoplasms, 109
in relation to high-frequency currents, 109
in scleritis, 110
in spring catarrh, 110, 241
in trachoma, 101
in tuberculosis of conjunctiva, 110

Y

Yellow ointment in acne rosacea of cornea, 277
in corneal opacities, 288
in herpes febrilis of cornea, 273
in phlyctenular keratitis, 269
in strumous pannus, 271
or red precipitate, in blepharitis marginalis, 217

Z

Zinc chlorid in abscess of lacrimal sac, 208, 209
oxid in eczema of eyelids, 211
or sulphate in blepharitis marginalis, 217
salicylate in grave corneal infection, 260
sulphate in corneal infection, 261
in corneal ulcer, 259
in dacryocystitis, 206, 207
in diplobacillary conjunctivitis, 223
Zingage, 182
Zona ophthalmica, acoin in, 274
anesthesin in, 274
collargol in, 274
dionin injections in, 213, 274
electricity in, 213, 274
guaiacol in, 274
herpes corneæ in, 273
iodoform in, 213, 274
orthoform in, 274
pyramidon in, 213, 274
quinin in, 213, 274
serotherapy in, 213, 273
valerian in, 213
Zonular cataract, 320
Zonule of Zinn, rupture of, in wound of the lens, 322

WELLCOME LIBRARY INSTITUTE